

Case report

Acute ischaemic stroke in secondary polycythaemia due to complex congenital cyanotic heart disease

Jeyaraj Durai Pandian, Ivy Anne Sebastian, Ashlee Sidhu 

Department of Neurology,
Christian Medical College &
Hospital Ludhiana, Ludhiana,
India

Correspondence to
Dr Ashlee Sidhu;
ashlee2907@gmail.com

Accepted 13 October 2019

SUMMARY

A 65-year-old woman presented to the emergency department with an acute onset of left-sided hemiparesis and slurred speech for 6 hours. Physical examination was notable for clubbing and peripheral cyanosis. Brain MRI showed an acute infarct involving the right gangliocapsular region. Investigations showed an elevated haemoglobin level, a haematocrit level of >65% and thrombocytopenia. Transthoracic echocardiography revealed tricuspid atresia, ventricular septal defect and atrial septal defect. A diagnosis of cyanotic congenital heart disease was made. Studies have indicated an association between raised haematocrit and vascular occlusive episodes in patients with polycythaemia vera. However, a relationship between raised haematocrit due to polycythaemia secondary to complex congenital heart disease and vascular thrombosis has not been reported. The improvement of neurological deficits in our patient coincided with a decline in haematocrit. The objective of this report was to highlight an association between elevated haematocrit and ischaemic stroke in patients with secondary polycythaemia due to complex congenital heart disease.

BACKGROUND

It is well-established that cyanotic congenital heart disease (CCHD) can cause secondary polycythaemia as a consequence of chronic hypoxaemia, although the incidence of acute ischaemic stroke in these patients is not often related to an elevated haematocrit level.

A relationship between haematocrit level of >45% and vascular occlusive episodes including strokes has been reported in patients with primary polycythaemia.

Although this association has not been reported in patients with CCHD with secondary erythrocytosis, the current clinical practice is to perform phlebotomy in the presence of clear symptoms of hyperviscosity to maintain the haematocrit level below 65%.

CASE PRESENTATION

A 65-year-old woman presented to the emergency department with an acute onset of left-sided hemiparesis and slurred speech for 6 hours. Her pulse was 76 beats/minute and regular with a blood pressure of 130/70 mmHg. Physical examination was notable for grade 3 clubbing on fingers and toes ([figure 1A,B](#)), peripheral cyanosis and

purpurae on the left paraumbilical region. Tone was reduced on the left side of the body with a Medical Research Council (MRC) grade of power of 0/5 in both the upper and lower limbs. Deep tendon reflexes were absent and plantar reflex was extensor on the left side. Sensations were intact in all extremities. A National Institutes of Health Stroke Scale (NIHSS) score of 11 was noted.

She denied any chest pain, shortness of breath, palpitations, dizziness, tinnitus, paraesthesias or headache. She had never undergone any corrective procedures and was not on domiciliary oxygen therapy. She was nulliparous, had no smoking history and was not on any regular medications.

INVESTIGATIONS

Head CT scan without contrast showed no abnormalities ([figure 2A](#)). Brain MRI showed an area of restricted diffusion on diffusion-weighted imaging involving the right gangliocapsular region, suggestive of acute infarction ([figure 2B](#)). Magnetic resonance angiography (MRA) of the brain showed no evidence of large-vessel occlusion (LVO).

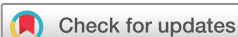Blood investigations revealed a red blood cell count of 6.01 million/cumm, predominantly normocytic and normochromic, haemoglobin level of 20.8 g/dL and haematocrit level of 69.1%, and platelet count of 71,000/cumm. Arterial oxygen saturation was 85%. Blood glucose levels were within the normal range, but glycated haemoglobin (HbA1c) levels were borderline high (6.4%).

Echocardiography revealed tricuspid atresia with a hypoplastic right ventricle, ventricular septal defect and atrial septal defect. All electrolytes, lipids, prothrombin time and activated partial prothrombin time were in normal ranges. Blood cultures were negative.

DIFFERENTIAL DIAGNOSIS

In lieu of acute onset of symptoms in a patient with congenital heart disease, a diagnosis of acute ischaemic stroke/transient ischaemic attack (TIA) was considered. Other differentials considered were metabolic derangements and demyelinating disorders. Metabolic workup for dyselectrolytemias and renal and hepatic functions was normal.

Brain MRI with MRA revealed an acute ischaemic infarct involving the right gangliocapsular region, establishing the diagnosis of an acute ischaemic stroke. No evidence of LVO was seen on MRA.



© BMJ Publishing Group Limited 2019. No commercial re-use. See rights and permissions. Published by BMJ.

To cite: Pandian JD, Sebastian IA, Sidhu A. *BMJ Case Rep* 2019;**12**:e231261. doi:10.1136/bcr-2019-231261

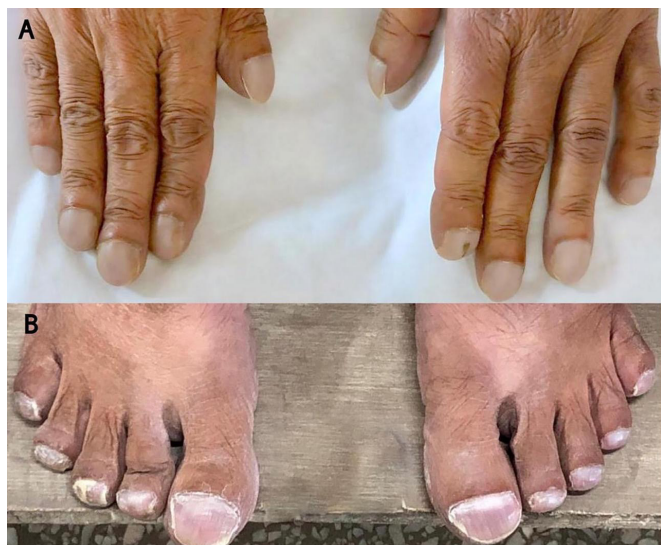

Figure 1 Grade 3 clubbing of (A) fingers and (B) toes.

Polycythaemia is defined as raised plasma red cell concentrations, with a haemoglobin level of >16.5 g/dL and haematocrit values of $>48\%$ for women, or a haemoglobin level of >18.5 g/dL and haematocrit values of $>52\%$ for men.

Polycythaemia may be categorised as absolute, caused by increased red cell mass, or as relative, due to decreased plasma volume, such as in dehydration or burn patients.

As opposed to polycythaemia vera, which presents with elevated red blood cells, white blood cells and platelets independent of erythropoietin levels, patients with complex congenital heart disease present with erythrocytosis and a normal or low platelet count. Secondary polycythaemia occurs when red blood cell production is induced by increased levels of circulating erythropoietin. Erythropoietin secretion may be appropriate as in hypoxaemic states, such as cyanotic heart disease or chronic obstructive pulmonary disease; or inappropriate due to erythropoietin-secreting tumours, such as renal cell carcinoma or hepatocellular carcinoma.

In our patient, a haematocrit level of 69.1%, haemoglobin level of 20.8 g/dL and arterial oxygen saturation of 85% in the

setting of a complex congenital cyanotic heart disease clearly indicated the presence of appropriate absolute polycythaemia.

TREATMENT

The patient arrived to the emergency department 6 hours after the onset of her symptoms. Due to her presentation beyond the window period, thrombolysis was not considered. Vessel imaging showed no evidence of anterior LVO; hence, thrombectomy was not considered.

The patient was managed conservatively with aspirin 325 mg and administration of intravenous fluids. Blood pressure readings were monitored and controlled. As HbA1c levels were borderline high, suggestive of impaired glucose tolerance, blood glucose levels were closely monitored and controlled. Early physiotherapy and rehabilitation were initiated. During the course of hospital stay, the patient showed gradual improvement in both speech and motor deficits, with an increase in MRC grade of power from 0 to 3 on the left side. The NIHSS score on re-evaluation had reduced from 11 to 4. Subsequent investigations showed a decline in her haematocrit from 69.1% to 61.3%.

OUTCOME AND FOLLOW-UP

The details of the diagnosis and disease process were discussed at length with the patient and her family. The patient did not wish to undergo any cardiac interventions and was discharged after 4 days on domiciliary oxygen therapy, physiotherapy and antiplatelets.

The patient is adherent to the medication and has been regular in her monthly follow-ups with no new complaints.

DISCUSSION

CCHD has a prevalence of 19 per 1000 individuals in North India.¹ Without surgical intervention, patients with complex CCHD rarely survive beyond infancy.² The rationale behind our patient reaching an age that is well beyond expectation without surgical intervention may be attributed to an excellently balanced circulation between atrial septal defect flow and ventricular septal defect flow, which protected her from a state of volume overload.

The systemic circulation in this patient, however well balanced, was unable to provide sufficient tissue perfusion, which led to a state of chronic hypoxaemia resulting in secondary polycythaemia.

Previous reports have indicated a relationship between a haematocrit level above 45% and vascular occlusive episodes in patients with polycythaemia vera.³ Therefore, phlebotomy is perceived to help lower the risk of developing vascular thrombosis. Although the direct association between elevated haematocrit and ischaemic stroke has not been reported in patients with CCHD with secondary polycythaemia, guidelines recommend phlebotomising patients with CCHD experiencing symptoms of hyperviscosity to maintain a target haematocrit level of $<65\%$.⁴ Repeated phlebotomy, however, is known to potentially accentuate rather than decrease the risk of a thrombotic event by causing microcytosis, thereby raising blood viscosity.⁵ Hence, there is no consensus in defining the optimal haematocrit in patients with CCHD.

A large retrospective analysis of contributing factors of stroke in adults with CCHD reported an increased association with hypertension, atrial fibrillation, repeated phlebotomies and iron deficiency,⁶ all of which were absent in our patient.

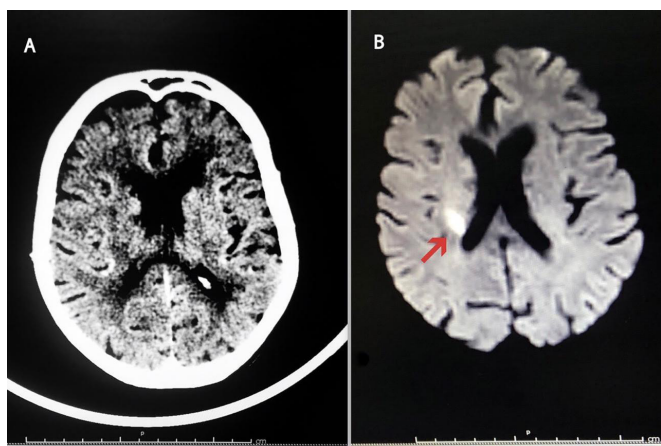


Figure 2 (A) Head CT scan without contrast showing no abnormalities. (B) MRI of the brain. Diffusion-weighted magnetic resonance image demonstrating the area of restricted diffusion (red arrow) involving the right gangliocapsular region.

Patient's perspective

Translated to English from the patient's native language, Hindi, by the corresponding author:

I have not been to a doctor in several years and considered myself as healthy as anyone else.

Having limited access to hospitals from where I come, I was not aware of my heart condition and I always felt fine. When I couldn't move my body or speak, it scared me and in that period I thought I was going to be that way forever.

But the support of my family and the doctors helped me get through it and today I feel good.

The doctors told me that my large nails were a result of the seriousness of my heart condition. I was quite taken back since I had always been aware of the size of my nails, and it was in fact a running joke in my family that they were so wide I could use up a bottle of nail polish on a single nail.

The doctors discussed with us the potential risks and benefits of not intervening in my condition, but I feel fine now. I have lived over 65 years without any procedures; I would like the remainder of my time to be the same. My family and I are very grateful for the care that was given to me. I can now take care of myself as I did before. I am able to bathe, change my clothes and groom myself, which now feels like a blessing.

Our patient developed acute ischaemic stroke at a haematocrit level of 69.1% and gradual improvement of the deficits was observed, along with a simultaneous decrease in the haematocrit level to 61.3%. The decline in haematocrit, as a result of aggressive intravenous hydration and coincidental improvement of the symptoms, supports our attribution of the potential cause of her neurological deficits to hyperviscosity induced by secondary polycythaemia.

A cross-sectional study of patients with uncorrected CCHD without a history of stroke showed cerebral ischaemic lesions on MRI to be associated with significantly higher haematocrit levels (>60%) compared with those with normal MRI.⁷

To the best of our knowledge, there have been no reports of acute ischaemic stroke precipitated by elevated haematocrit and haemoglobin levels in CCHD.

There have been few reports of vascular thrombosis, including cerebral infarction and TIAs precipitated by secondary erythrocytosis of other aetiologies.^{8–12}

The presence of thrombocytopenia in our patient required us to carefully weigh the risks and benefits of phlebotomy so as not to further compromise platelet count. Studies have reported the incidence of thrombocytopenia in a minority of patients with CCHD. Physiologically, megakaryocytes are fragmented into platelets within the lung and delivered to arterial circulation. It has been suggested that low platelet counts may result from blood bypassing the lung in the presence of a right to left shunt, drastically reducing platelet production.¹³ Although an increase in platelets has been reported postphlebotomy, this hypothesis is not established enough to be relied on to induce a desired increase in platelet count. As a result, the role of phlebotomy is unclear in such patients. General management recommendations include measures to lower haematocrit and blood viscosity by intravenous hydration and aspirin therapy.

This association between elevated haematocrit and ischaemic stroke in patients with polycythaemia secondary to CCHD needs to be further explored in a larger population so that significant correlations, if any, can be identified.

Learning points

- ▶ Acute ischaemic stroke in adults with cyanotic congenital heart disease (CCHD) in the absence of risk factors such as hypertension, atrial fibrillation, history of phlebotomies and iron deficiency should raise suspicion of a haematocrit level of >65%.
- ▶ A rare constellation of structural abnormalities, namely, tricuspid atresia and atrial and ventricular septal defects supports the development of a well-balanced circulation that protects from volume overload state.
- ▶ Improvement of neurological deficits coinciding with a decline in the haematocrit level raises the possibility of a relationship between elevated haematocrit and acute ischaemic stroke in polycythaemia secondary to cyanotic congenital heart disease.
- ▶ Management considerations in such cases are aimed at lowering haematocrit levels and blood viscosity with measures such as aggressive intravenous hydration and aspirin therapy.
- ▶ In patients with CCHD with thrombocytopenia, utmost consideration must be given to the potential consequences of performing phlebotomy, as judged by the haematocrit value.

Contributors JDP provided supervision and critically revised the manuscript for important intellectual content. IAS analysed, interpreted and reviewed the information. AS, the corresponding author, collected the data, analysed and interpreted the information, and wrote the report.

Funding The authors have not declared a specific grant for this research from any funding agency in the public, commercial or not-for-profit sectors.

Competing interests None declared.

Patient consent for publication Obtained.

Provenance and peer review Not commissioned; externally peer reviewed.

ORCID iD

Ashlee Sidhu <http://orcid.org/0000-0002-5851-8836>

REFERENCES

- 1 Bhardwaj R, Rai SK, Yadav AK, *et al.* Epidemiology of congenital heart disease in India. *Congenit Heart Dis* 2015;10:437–46.
- 2 Thorne SA. Atrioventricular Valve Atresia. In: Gatzoulis M, Webb G, Daubeney P, eds. *Diagnosis and management of adult congenital heart disease*. Philadelphia, PA: Elsevier, 2018: 570–8.
- 3 Rose SS, Shah AA, Hoover DR, *et al.* Cyanotic congenital heart disease (CCHD) with symptomatic erythrocytosis. *J Gen Intern Med* 2007;22:1775–7.
- 4 Thorne SA. Management of polycythaemia in adults with cyanotic congenital heart disease. *Heart* 1998;79:315–6.
- 5 Perloff JK, Marelli AJ, Miner PD. Risk of stroke in adults with cyanotic congenital heart disease. *Circulation* 1993;87:1954–9.
- 6 Ammash N, Warnes CA. Cerebrovascular events in adult patients with cyanotic congenital heart disease. *J Am Coll Cardiol* 1996;28:768–72.
- 7 Horigome H, Iwasaki N, Anno I, *et al.* Magnetic resonance imaging of the brain and haematological profile in adult cyanotic congenital heart disease without stroke. *Heart* 2006;92:263–5.
- 8 Hurtarte Sandoval AR, Flores Robles BJ, Andrus RF. Transient ischaemic attack secondary to paraneoplastic erythrocytosis. *Case Reports* 2014.
- 9 Thakur KT, Westover MB. Cerebral infarction due to smoker's polycythemia. *Case Reports* 2011.
- 10 Harston GWJ, Batt F, Fan L, *et al.* Lacunar infarction associated with anabolic steroids and polycythemia: a case report. *Case Rep Neurol* 2014;6:34–7.
- 11 Skoog K, Carmelle-Elie M, Ferguson K. Mesenteric infarction due to iatrogenic polycythemia. *World J Emerg Med* 2013;4:232–4.
- 12 Corse AK, Kurtis H. Ischemic stroke caused by secondary polycythemia and incidentally-found renal cell carcinoma: a case report. *Am J Case Rep* 2018;19:638–41.
- 13 Lill MC, Perloff JK, Child JS, *et al.* Pathogenesis of thrombocytopenia in cyanotic congenital heart disease. *Am J Cardiol* 2006;98:254–8.

Copyright 2019 BMJ Publishing Group. All rights reserved. For permission to reuse any of this content visit <https://www.bmj.com/company/products-services/rights-and-licensing/permissions/>
BMJ Case Report Fellows may re-use this article for personal use and teaching without any further permission.

Become a Fellow of BMJ Case Reports today and you can:

- ▶ Submit as many cases as you like
- ▶ Enjoy fast sympathetic peer review and rapid publication of accepted articles
- ▶ Access all the published articles
- ▶ Re-use any of the published material for personal use and teaching without further permission

Customer Service

If you have any further queries about your subscription, please contact our customer services team on +44 (0) 207111 1105 or via email at support@bmj.com.

Visit casereports.bmj.com for more articles like this and to become a Fellow