


Accepted Manuscript

A therapeutic regimen for 3-hydroxyisobutyryl-CoA hydrolase deficiency with exercise-induced dystonia

Yan Xu, Jing Zhang, Kang Yu, Feng Feng, Xiayuan Sun, Chunwei Li, Huili Li, Liying Cui



PII: S1090-3798(17)31991-8

DOI: [10.1016/j.ejpn.2017.11.004](https://doi.org/10.1016/j.ejpn.2017.11.004)

Reference: YEJPN 2325

To appear in: *European Journal of Paediatric Neurology*

Received Date: 7 September 2015

Revised Date: 14 January 2016

Accepted Date: 13 November 2017

Please cite this article as: Xu Y, Zhang J, Yu K, Feng F, Sun X, Li C, Li H, Cui L, A therapeutic regimen for 3-hydroxyisobutyryl-CoA hydrolase deficiency with exercise-induced dystonia, *European Journal of Paediatric Neurology* (2017), doi: 10.1016/j.ejpn.2017.11.004.

This is a PDF file of an unedited manuscript that has been accepted for publication. As a service to our customers we are providing this early version of the manuscript. The manuscript will undergo copyediting, typesetting, and review of the resulting proof before it is published in its final form. Please note that during the production process errors may be discovered which could affect the content, and all legal disclaimers that apply to the journal pertain.

Title: A therapeutic regimen for 3-hydroxyisobutyryl-CoA hydrolase deficiency with exercise-induced dystonia

Authors: Yan Xu¹, Jing Zhang², Kang Yu³, Feng Feng⁴, Xiayuan Sun¹, Chunwei Li³, Huili Li⁵, Liying Cui⁶

Address:

¹Department of Neurology, Peking Union Medical College Hospital, Beijing 100730, PR China.

²The State Key Laboratory of Medical Molecular Biology, Department of Molecular Biology and Biochemistry, Institute of Basic Medical Sciences Chinese Academy of Medical Sciences, School of Basic Medicine Peking Union Medical College, Beijing 100005, PR China; Neuroscience Center of Chinese Academy of Medical Sciences, Beijing 100005, PR China.

³Department of clinical nutrition, Peking Union Medical College Hospital, Beijing 100730, PR China.

⁴Department of Radiology, Peking Union Medical College Hospital, Beijing 100730, PR China.

⁵Capital Institute of Pediatrics, Beijing Municipal Key Laboratory of Child Development and Nutriomics, Beijing 100020, PR China.

⁶Department of Neurology, Peking Union Medical College Hospital, Beijing 100730, PR China; Neuroscience Center of Chinese Academy of Medical Sciences, Beijing 100005, PR China.

Author contributions:

Drs Xu and Zhang contributed equally to the manuscript.

Corresponding to:

Dr. Liying Cui, Department of Neurology, Peking Union Medical College Hospital, 1 Shuaifuyuan, Dongcheng District, Beijing, 100730, PR China. Tel: 86-10-69156373; Fax: 86-10-69156373. Email: pumhcui@pku.edu.cn

Dr. Huili Li, Capital Institute of Pediatrics, Beijing Municipal Key Laboratory of Child Development and Nutriomics, Beijing, 100020, China. Tel:86-10-85638400. Fax: 86-10-85631504. Email: lihuili2011@gmail.com.

Total number of words in Abstract: 105

Total number of words in paper: 1433

Total number of figures: 1

Abstract

3-hydroxyisobutyryl-CoA hydrolase (HIBCH) deficiency is a recently described disease resulting from mutations in *HIBCH* with no effective treatment. Here, we report a female Chinese patient presenting with exercise-induced dystonia and bilateral symmetrical hyperintensities of the globus pallidus on brain MRI associated with novel *HIBCH* mutations (c.1027C>G;p. H343D and c.383T>A;p.V128D). After treatment for 1 year with a low-valine diet, both clinical symptoms and brain lesions improved substantially. We propose that HIBCH deficiency should be considered in the differential diagnosis for patients with exercise-induced dystonia, particularly if bilateral symmetrical lesions in the globus pallidus are present. A low-valine diet is a potentially promising treatment for HIBCH deficiency.

Keywords:

3-hydroxyisobutyryl-CoA hydrolase; HIBCH deficiency; valine metabolism; exercise-induced dystonia; globus pallidus hyperintensities; magnetic resonance imaging

Highlights:

- 1) HIBCH deficiency should be considered in the differential diagnosis for patients with exercise-induced dystonia, particularly if bilateral symmetrical lesions in the globus pallidus are present.
- 2) A low-valine diet is a potentially promising treatment for HIBCH deficiency.

1. Introduction

3-hydroxyisobutyryl-CoA hydrolase (HIBCH) deficiency is a recently described disease resulting from mutations in *HIBCH*. Until now, HIBCH deficiency has been reported in five patients from four families. All of these patients are male Caucasians presenting with dystonia and hyperintensities of the basal ganglia (especially the globus pallidus), as determined using magnetic resonance imaging (MRI)¹⁻⁴. No optimal treatments for this disease have been established. Here, we report a 6-year-old Chinese girl with exercise-induced dystonia, hyperintensities of the globus pallidus, as observed in MRI scans, and two novel missense mutations in *HIBCH*. After treatment with a low-valine diet, the patient has improved markedly.

2. Case Study

2.1. Clinical course and diagnostic work-up

A 6-year-old Chinese girl was admitted to our hospital for exercise-induced dystonia. She was the first child of healthy, unrelated parents and had normal psychomotor function. At 3 years old, the patient began to complain of frequent cramps in the right leg triggered by prolonged and intense exercise (active play for 30 minutes), which resolved after 10 minutes of rest. Over the following 3 years, after trials with multiple medications alone and in combination (including carbamazepine, levodopa, baclofen, and clonazepam), the symptoms gradually worsened, characterized by dystonic posturing in both lower extremities and the waist triggered by mild physical activity (e.g., walking 100 m), which resolved after 1 hour of rest. The patient did not increase in height or weight for 2 years (118 cm, 18 kg).

Observations at examination between attacks were normal. The patient had a raven (intelligence quotient) test score of 110. Biochemical analyses indicated elevated levels of ammonia (46-51 $\mu\text{mol/L}$, normal 11-32 $\mu\text{mol/L}$) and creatine kinase (CK, 229-244 units/L, normal 24-170 units/L). Screening for aminoacidopathies and organic acidurias yielded normal results. Acylcarnitine analyses did not indicate any abnormalities. Activity of respiratory chain complexes in peripheral leukocytes, expressed as a ratio to activity of citrate synthase, indicated a reduction in the activity of complex V (0.559, controls 0.607-5.662), with normal values for complexes I, II, I+III, and IV. Blood lactate levels were elevated (2.3 mmol/L, normal 0.4-2.0 mmol/L) during exercise, but normal at rest. Cerebrospinal fluid lactate levels and electroencephalogram were normal. Analysis of a muscle biopsy (performed on frozen tissue) did not find clear evidence for myopathies or neuropathies. No “ragged red fibers” or cytochrome oxidase-negative fibers were observed.

MRI scans of the brain showed symmetrical signal abnormalities in the globus pallidus (Fig. 1-I.A), while magnetic resonance (MR) spectroscopy measurements were normal (Fig. 1-I.B).

2.2. Molecular genetic analysis

Because the patient's clinical picture suggested a diagnosis for mitochondrial encephalomyopathy, we used blood samples from the patient to employ a technique dependent on gene capture, combined with high-throughput sequencing of whole exons in 1033 mitochondrial and nuclear candidate genes (Mygenostics, <http://www.mygeno.cn>; sample NO.2014-S00696). Two point mutations in *HIBCH* were identified. We later used Sanger sequencing to validate the genotypes of the patient and her parents for *HIBCH*. The patient was compound heterozygous for two novel missense mutations, c.1027C>G;p. H343D and c.383T>A;p.V128D, at exon-13 and exon-5 in *HIBCH*, respectively. The former mutation was paternal, whereas the mother was a heterozygous carrier of the c.383T>A mutation (Table 1, supplementary material, Fig. 1-II.A). We also measured the expression of *HIBCH* at the mRNA and protein levels and found abnormal up-regulations in *HIBCH* mRNA and protein in the patient (Fig. 1-II.C, II.D).

2.3. Treatment and results

Based on the pathogenesis of HIBCH deficiency, a low-valine diet was prescribed, which included Maxamaind XP-2 (an enteral nutritional formula with no valine, methionine, or threonine) and avoidance of poultry, meat, eggs, and fish. To control attacks, the patient was prescribed gabapentin (75 mg), followed by a 5-day titration period with a dosage goal of 100 mg every 8 hours (10-20 mg/kg/day). After 1 year of treatment, the patient did not experience obvious attacks after routine activities, serum ammonia levels normalized (19.1-26.7 $\mu\text{mol/L}$), brain MRI scans indicated substantial reductions in lesion size (Fig. 1-I.C), height increased by 7 cm, and weight increased by 3.6 kg. Because no new attacks were reported and brain lesions had markedly diminished, the dose of gabapentin was reduced from 300 to 200 mg/day; the condition of the patient remained stable. There were no adverse effects secondary to the prescribed low-valine diet and gabapentin. Blood counts and tests of liver function remained normal.

3. Discussion

We report findings in a 6-year-old Chinese girl with HIBCH deficiency and two novel *HIBCH* mutations. She presented with exercise-induced dystonia, elevated levels of blood ammonia, lactate, and CK, as well as respiratory chain complex V deficiency in blood peripheral leukocytes, and hyperintensities of the globus pallidus on brain MRI scan. The patient demonstrated marked improvements in both clinical presentation and brain lesion size after treatment with a low-valine diet.

The mutations identified in this case (c.1027C>G;p. H343D and c.383T>A;p.V128D) affect two highly conserved amino acids. The former mutation is located in the C-terminal region associated with 2-enoyl-CoA hydratase activity, and the latter is located in the substrate-binding region of HIBCH (Fig. 1-II.B). In exon-13

of *HIBCH*, near the c.1027C>G mutation, there is a simple nucleotide polymorphism (SNP) at rs182123874 (Chr2-191073623, dbSNP database), which is a missense variant of a T>A mutation (average heterozygosity 0.001 ± 0.021 , with reported minor allele frequencies of “A” = 0.046% and “T” = 99.954%). In exon-5 of *HIBCH*, there is a SNP adjacent to the c.383T>A mutation at rs145102111 (Chr2-191155130). As a splice donor variant, the reported minor allele frequencies for the two polymorphisms of rs145102111 are A = 0.050% and C = 99.950%.

Due to the limitations of the clinical work, we could not collect fibroblasts for the analysis of HIBCH activity; however, the substantial reductions in brain lesion size (Fig. 1-I.C) and improvements in clinical presentation after 1 year of the low-valine diet suggest that HIBCH activity was abnormal. Moreover, up-regulations of *HIBCH* mRNA and protein (Fig. 1-II.C, II.D) further suggest that there may have been pathological compensatory increases in gene expression induced by abnormal HIBCH function. Therefore, given the above evidence, we postulate that the mutations identified in this patient are pathological, despite not being recorded in Human Gene Mutation Database Professional (HGMD Pro) and 1000 Genomes.

In contrast to the phenotypes of other patients (Table 1, supplementary material)²⁻⁴, this patient had a milder clinical presentation with only exercise-induced dystonia. This incongruence may be explained by differences in mutation types between our patient and those described in Table 1. Mutations causing complete loss of the enzyme or of function may result in a severe phenotype, whereas partial loss of function would result in a more moderate clinical course. Therefore, we hypothesize that HIBCH deficiency may range in severity from mild (purely exercise-induced dystonia) to very severe (early onset, poor feeding, developmental regression, dystonia, seizure, physical malformations, and death).

Results from biochemical analyses in reported cases have been inconsistent, even between affected individuals from the same family and in different samples from the same patient². Three of five reported cases had elevated levels of hydroxyl-C4-carnitine and, based on this finding, acylcarnitine analysis is thus recommended as a screening test^{2,3}. Hydroxyl-C4-carnitine levels in our patient, however, were normal; this might be explained by differences in dietary protein composition and mutational pathogenesis, which influence the concentration of toxic valine metabolites. Differences in methods of detection may be another contributing factor. While biochemical results have varied greatly between patients, radiological findings in the present patient and in other patients are highly consistent. Five patients had presented with hyperintensities of the basal ganglia (particularly in the globus pallidus), except Patient 1, who did not have MRI data (Table 1, supplementary material)²⁻⁴. These findings suggest that HIBCH deficiency should be considered in cases of children with symmetrical hyperintensities of the globus pallidus on brain MRI scan, after excluding common hereditary and metabolic diseases, although the patients had normal levels of hydroxyl-C4-carnitine.

The pathogenesis of HIBCH deficiency has been attributed to the accumulation of toxic valine metabolites, especially methacrylyl-CoA. The compound of methacrylyl-CoA with cysteine and cysteamine has been shown to accumulate in the

livers, kidneys, and brains of individuals with HIBCH deficiency, as reported in the first patient. Therefore, Loupatty et al. have suggested that treatment of patients with HIBCH deficiency should focus on preventing increased flux through the catabolic pathway of in L-valine⁴. The fact that brain lesion size diminished and clinical status improved with a low-valine diet in our patient supports this view.

In summary, HIBCH deficiency should be considered a cause of exercise-induced dystonia, especially if the patient presents with bilateral symmetrical lesions in the globus pallidus. Furthermore, a low-valine diet may be greatly beneficial for patients with this diagnosis.

Acknowledgements

The authors would like to thank the patient and her family

Conflict of interest

The authors declare no conflict of interest.

References

1. Brown GK, Hunt SM, Scholem R, et al. beta-hydroxyisobutyryl coenzyme A deacylase deficiency: A defect in valine metabolism associated with physical malformations. *Pediatrics* 1982; 70: 532-38.
2. Reuter MS, Sass JO, Leis T, et al. HIBCH deficiency in a patient with phenotypic characteristics of mitochondrial disorders. *Am J Med Genet Part A* 2014; 9999:1-8.
3. Ferdinandusse S, Waterham HR, Heales SJ, et al. HIBCH mutations can cause Leigh-like disease with combined deficiency of multiple mitochondrial respiratory chain enzymes and pyruvate dehydrogenase. *Orphanet J Rare Dis* 2013; 8: 188-98.
4. Loupatty FJ, Clayton PT, Ruiter JP, et al. Mutations in the gene encoding 3-hydroxyisobutyryl-CoA hydrolase results in progressive infantile neurodegeneration. *Am J Hum Genet* 2007; 80(1): 195-99.

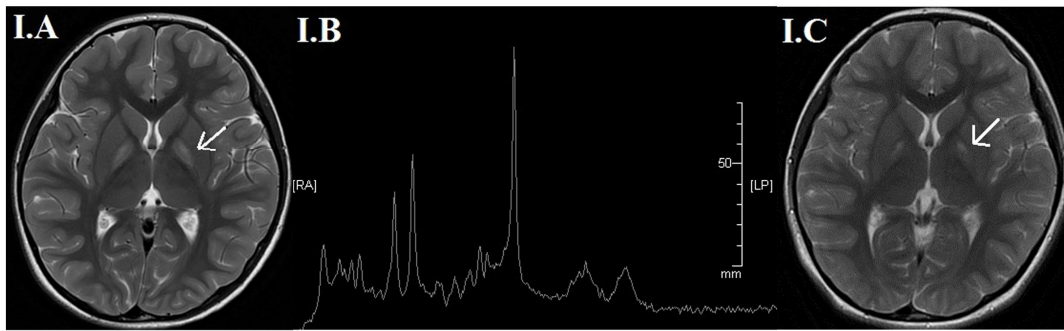
Fig. 1. (I) Brain MRI and MRS. (I.A) Brain MRI at the age of 6, indicating symmetric hyperintensities of the basal ganglia (arrows). (I.B) Brain MR spectroscopy of the lesion, demonstrating normal N-acetylaspartate, choline, creatine and lactate peaks. (I.C) Brain MRI after 1 year of low-valine diet, indicating substantial reductions in brain lesion size (arrows). (II) Diallelic heterozygous HIBCH mutation and up-regulation of levels of mRNA and protein of HIBCH in daughter. (II.A) Sequence electropherograms of HIBCH gene. Top panel: the genomic locus of human HIBCH gene and the 14 exons of HIBCH mRNA (NM_014362, GRCh37/hg19). Second row panels (from top): the patient obtains the heterozygous mutations with c.1027C>G mutation (exon13) and c.383T>A (exon5) on the alleles of HIBCH. Third row panels: the father is a heterozygous for the c.1027C>G mutation (exon13). Fourth row panels: the mother is a heterozygous for the c.383T>A (exon5). (II.B) Location the mutations identified in the present study and reported other HIBCH deficiency in the previous studies. The blue balls and green balls are shown the functional sites of the hHIBCH protein, moreover, the mutation variants in the present case (red cycles) and the mutation variants in the previous studies (blue cycles) are denoted in the HIBCH gene's body. The prediction of functional protein domains affected by the present two novel mutations: the c.1027C>G mutation induced a change of p.H343D in the 2-enoyl-CoA hydratase C-terminal region, and the c.383T>A mutation induced a change p.V128B in the substrate binding site of HIBCH. (II.C) Relative expression of HIBCH gene in the blood cells of parents and suffering daughter analyzed by RT-qPCR (mean \pm SE), and the data were standardized by the reference gene of GAPDH. (II.D) Immunoblot analysis of HIBCH in blood cells of the three members of the family. The proteins were subjected to SDS-PAGE and transferred onto nitrocellulose by semidry blotting. Polyclonal HIBCH antibody raised against rabbit were used at a dilution of 1:2,000.

Table 1. Clinical, biochemical and radiological features and mutations of HIBCH deficiency

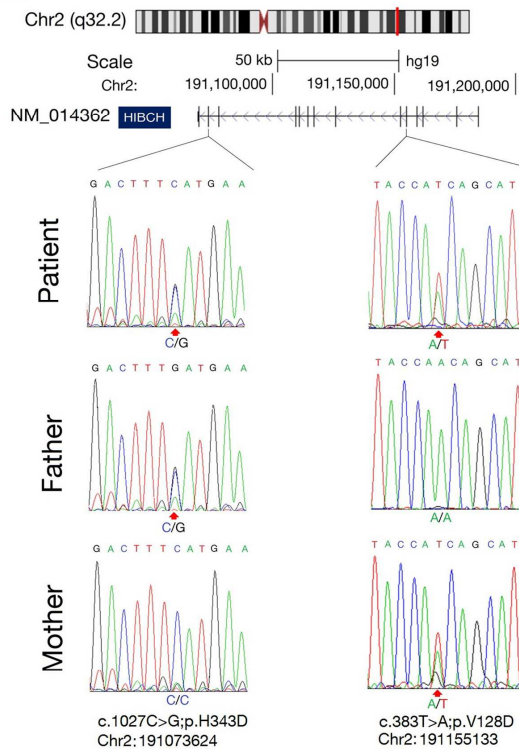
	Present case	Patient 1 (Brown; 1982)	Patient 2 (Loupaty; 2007)	Patient 3 (Ferdinandusse;2013)	Patient 4 (Ferdinandusse;2013)	Patient 5 (Reuter; 2014)
Gender	Female	Male	Male	Male	Male	Male
Ethnic origin	China	Egypt	No data	Pakistan	Pakistan	Tunisia
Family history	Nonconsanguineous, healthy parents	First cousin, healthy parents	Nonconsanguineous, healthy parents	Distantly related, healthy parents	Distantly related, healthy parents; younger sibling of patient 3	Double second cousins, healthy parents
Neonatal problem	No	Poor feeding	Poor feeding	Vomiting	Poor feeding	No
Developmental regression	No	No data	yes	yes	yes	yes
Age at presentation	3 years	Birth	4 months	3 months	Birth	7 months
Age at death	Still alive (now 7 years)	3 months	Alive at 8 years	3 years	2 years 8 months	No data
Initial presentation	Exercise-induced dystonia	Dysmorphic features	Head bobbing	Developmental regression	Poor feeding	psychomotor delay, generalized muscular hypotonia, convergent strabismus
Dystonia	yes	No data	yes	yes	yes	No data
Seizures	No	No data	Transient absences, Episodes of eye rolling	Myoclonus, Generalised seizures	Infantile spasms	Progressive epilepsy
Visual function	Normal	No data	No data	Visual impairment, optic nerve atrophy	Visual impairment	Optic nerve atrophy/blindness,

						Strabismus, nystagmus
Other clinical presentation	No	No	Episodes of acute encephalopathy	Screaming episodes, Sleep disturbance, Central apnoea, Hearing loss	Screaming episodes, Poor sleep, Central apnoea	Central coordination disorder
Neurological exam	Hypertonia (attack) Normal (interictal stage)	Hypotonia	Hypotonia, truncal ataxia, dysmetria and intention tremor	Hypotonia	Hypotonia	Hypotonia (trunk) Hypertonia (extremities) Hyperactive reflexes
Physical malformations	No	Facial dysmorphism Vertebral anomalies, Tetralogy of fallot, Agenesis of the cingulated gyrus and corpus callosum	No	Microcephaly	Microcephaly	No
Brain MRI	Bilateral symmetrical hyperintense signals of the globus pallidus. No lactate peak.	No data	Signal abnormalities in globus pallidus and midbrain.	Altered signal and atrophy in the globi pallid, with leukoencephalopathy and some generalized atrophy	Abnormal signal within the dentate nuclei and the globi pallid, with a generalized lack of white matter	Hyperintense signals of the basal ganglia (especial globi pallid). Progressive cortical atrophy. No lactate peak.
Venous blood lactate (<2.0 mmol/L)	2.3	No data	1.7	1.7	4.0 , 1.6, 1.2	2.4-4.3
Cerebral spinal fluid (<2.0 mmol/L)	1.59	No data	1.3	3.5, 2.2	2.1, 2.6	No data

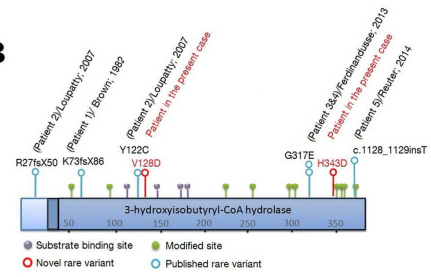
Hydroxy-C4-carnitine	Normal	No data	Elevated	No data	Elevated	Elevated
Blood ammonia	Elevated	No data	Normal	No data	No data	No data
Respiratory chain enzyme activities (Ratio to citrate synthase activity)						
Complex I	Normal (blood)	No data	Deficiency (muscle)	Deficiency (muscle)	Normal (muscle)	Deficiency (muscle)
Complex II	Normal (blood)	No data	No data	No data	No data	No data
Complexes I+III	Normal (blood)	No data	No data	No data	No data	Deficiency (muscle)
Complexes II+III	No data	No data	Normal (muscle)	No data	No data	Deficiency (muscle)
Complex IV	Normal (blood)	No data	Borderline deficiency (muscle)	Deficiency (muscle)	Normal (muscle)	Reduction in western blot (muscle)
Complex V	Deficiency (blood)	No data	No data	No data	No data	No data
HIBCH mutations	Compound heterozygous c.1027C>G;p.H343D and c.383T>A;p.V128D	Homozygous c.219_220insTTGAATAG; p.K73fsX86	Compound heterozygous c.365A>G; p.Y122C and IVS2-3C>G; p.R27fsX50	Homozygous c.950G>A; p.G317E	Homozygous c.950G>A; p.G317E	Homozygous c.1128_1129insT; p.Lys377



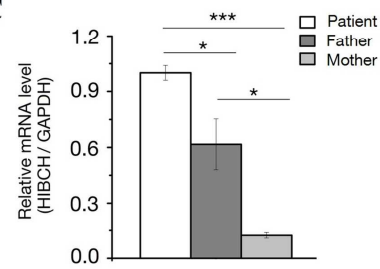
II.A



II.B



II.C



II.D

