



Available online at  
**ScienceDirect**  
www.sciencedirect.com

Elsevier Masson France  
**EM|consulte**  
www.em-consulte.com



## Letter to the editor

### Focal hyperperfusion and elevated lactate in the cerebral lesions with anti-GABA<sub>A</sub>R encephalitis: A serial MRI study

#### ARTICLE INFO

**Keywords:**  
Autoimmune encephalitis  
MRS  
Hyperperfusion  
GABA<sub>A</sub> receptor

#### Introduction

Anti- $\gamma$ -aminobutyric acid A receptor (GABA<sub>A</sub>R) encephalitis is a rare autoimmune disorder characterized by refractory seizures, status epilepticus, and multifocal cortical-subcortical T2/fluid-attenuated inversion recovery (FLAIR) abnormalities associated with auto-antibodies against the  $\alpha 1/\beta 3$  subunits of the GABA<sub>A</sub>R [1–3]. Brain MRI abnormalities are the hallmark of this disorder.

Here we report a case of anti-GABA<sub>A</sub>R encephalitis, of which neuroimaging showed multifocal hyperperfusion with lactate accumulation mimicking stroke-like lesions in mitochondrial encephalomyopathy, lactic acidosis, and stroke-like episodes (MELAS) [4–6].

#### Case report

A 67-year-old right-handed woman was admitted to our hospital. She had been in her usual state of health until 35 days before admission, when dysesthesia and pain developed in her left leg gradually ascending from the toes over 3 days. She underwent a brain MRI at another hospital, which showed increased FLAIR/T2 signal in the posterior part of the right insular cortex. Levetiracetam 1,000 mg/day was started, and she was referred to the department of neurosurgery with suspected brain tumor. On admission (day 1), the patient was alert, and well oriented. She had sensory symptoms but she had no sensory loss. A brain MRI obtained on day 9 showed newly appearing multifocal cortico-subcortical lesions and expansion of the initial insular lesion, without enhancing effect. Apparent diffusion coefficient (ADC) values were reduced in cortical lesions but elevated in underlying subcortical white matter. Arterial spin labeling (ASL)-perfusion MRI showed multifocal hyperperfusion in the areas corresponding to the acute lesions (Fig. 1A). On day 11 she was transferred to our department of neurology for further evaluation.

She had a past medical history of hypothyroidism and gastrointestinal stromal tumor of the stomach, which was removed one year earlier. She had been treated with levothyroxine since 62 years of age.

On examination, the temperature was 36.9 °C; physical examination was unremarkable. On neurologic examination, the patient had short-term memory loss and dyscalculia, but otherwise neurologically unremarkable. The blood test-results were normal, including thyroid function, serum lactate (0.92 mmol/L), and pyruvate (0.1 mmol/L), except ANA (1:80), serum TPO antibodies (417 IU/mL, normal <16), and Tg antibodies (> 4000 IU/mL, normal <28). Cerebrospinal fluid (CSF) examination revealed 5 white blood cells/ $\mu$ L, and a protein level of 38 mg/dL. CSF lactate level was elevated (3.62 mmol/L) but pyruvate level was normal (0.24 mmol/L); L/P ratio was 15.2.

On day 12 generalized tonic-clonic seizure developed followed by delirious state. On day 14 electroencephalogram showed paroxysmal discharges in C4 and T4. Stroke-like episodes in MELAS were initially suspected, but oligoclonal bands were subsequently detected in CSF. For possible autoimmune encephalitis, she received 2 cycles of intravenous high-dose methylprednisolone (1,000 mg for 3 days) on day 14 and 21, respectively, followed by gradual tapering of prednisolone (25 mg/day). On day 24 her symptoms began to improve associated with gradual resolution of the right peri-sylvian fronto-temporal cortical lesions, but the right posterior-temporal lesion further expanded with focal hyperperfusion (Fig. 1B). <sup>1</sup>H-MRS using a short echo time (TE 35 ms) showed elevated lactate (Lac) signals and Lac/creatine (Cr) ratio in the voxel of interest (Fig. 1C and D).

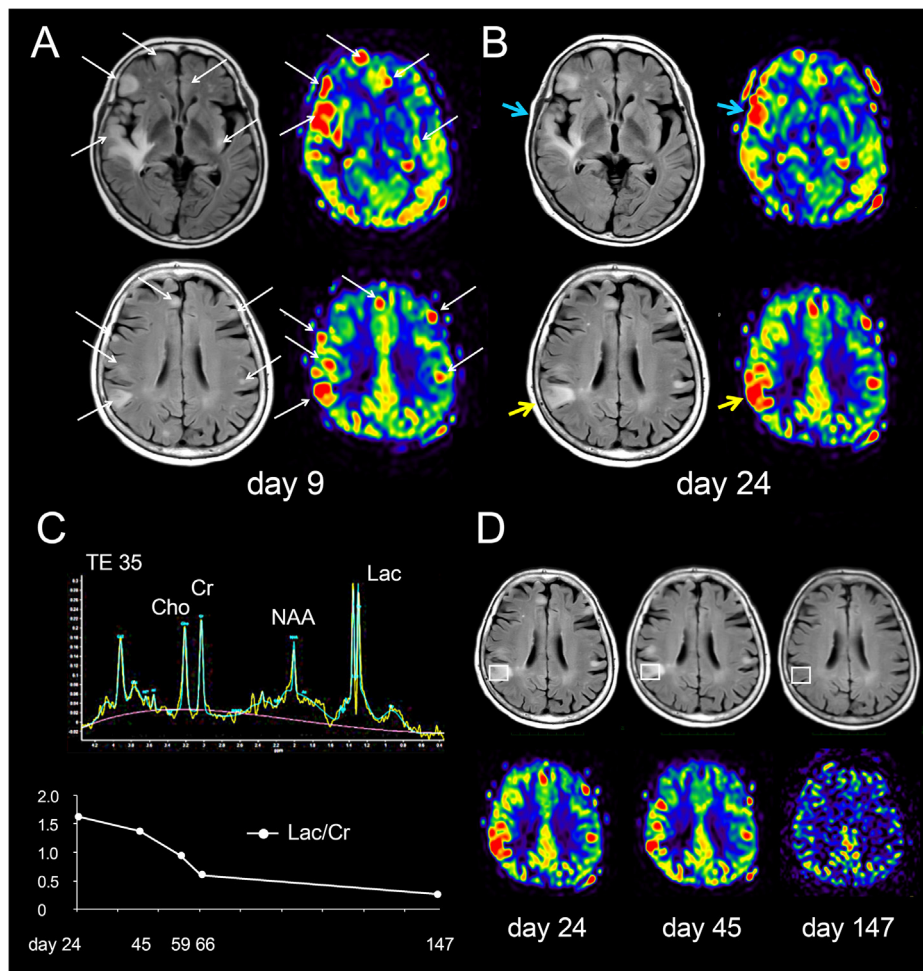
On day 37 prednisolone was changed to cyclophosphamide (50 mg/day) because steroid-induced manic state developed. On day 40 it was reported that she was positive for GABA<sub>A</sub>R antibodies in both serum and CSF obtained on day 11 but negative for other auto-antibodies against neuronal cell-surface antigens (NMDA receptor, AMPA receptor, GABA<sub>B</sub> receptor, LGI1, Caspr2, or mGluR5). These antibodies were determined with established cell-based assays and rat brain immuno-histo-chemistry at University of Barcelona. On day 45 the follow-up MRI studies showed mild improvement of the brain lesions. A Lac/Cr ratio remained high but subsequently returned to normal with resolution of hyperperfusion (Fig. 1C and D). On day 67 she was discharged without neurological sequelae; on discharge she was treated with levetiracetam (2,000 mg/day), perampanel (6 mg/day), and cyclophosphamide (50 mg/day). At the last follow-up (day 147), brain MRI was unremarkable (Fig. 1D), and she was free of symptoms without recurrence of seizure.

#### Discussion

This patient presented with ascending sensory symptoms in the left leg followed by generalized convulsive seizures associated with rapidly developing multifocal cortico-subcortical lesions. Although the MRI findings are typical of anti-GABA<sub>A</sub>R encephalitis, ASL-perfusion MRI and <sup>1</sup>H-MRS showed multifocal hyperperfusion with elevated Lac/Cr ratio in the acute lesions, of which

<https://doi.org/10.1016/j.neurad.2019.10.001>

0150-9861/© 2019 Elsevier Masson SAS. All rights reserved.



**Fig. 1.** Neuroimaging studies. Day 9: a brain MRI obtained on day 9 shows multifocal cortico-subcortical increased fluid-attenuated inversion recovery (FLAIR) signals (A, arrows). Arterial spin labeling (ASL)-perfusion map also shows multifocal hyperperfusion in the areas corresponding to the acute brain lesions (A, arrows). The follow-up brain MRI obtained on day 24 shows improvement in the right peri-sylvian cortex (B, blue arrow) but rather expansion of the right posterior-temporal parietal lesion (B, yellow arrow). ASL-perfusion map also shows disease activity dependent hyperperfusion.  $^1\text{H}$ -MRS shows marked elevation of lactate (Lac) doublet peaks in the right posterior-temporal parietal lesion (C and D). Note gradual decline in Lac/Cr ratio associated with resolution of increased FLAIR signal and hyperperfusion (C).

neuroimaging pattern is similar to those of stroke-like episodes in MELAS. As the patient was initially suspected with MELAS, the similarity of neuroimaging pattern may potentially delay the diagnosis of treatment-responsive autoimmune encephalitis particularly in cases of lack of CSF pleocytosis or fever.

The mechanism of hyperperfusion remains speculative, but elevated Lac/Cr ratio suggests increased anaerobic glycolysis through focally increased metabolic demands such as seizure, resulting in accumulation of lactate and increase in cerebral blood flow (CBF). In anti-GABA<sub>A</sub>R encephalitis, the auto-antibodies are shown to decrease the density of the GABA<sub>A</sub>R at post-synaptic membrane, and down-regulate GABA<sub>A</sub>R function, leading to neuronal hyperexcitability [1,7]. Vacchiano et al. reported a case of anti-GABA<sub>A</sub>R encephalitis with multifocal hypermetabolic lesions on  $^{18}\text{F}$ fluorodeoxyglucose positron emission tomography in the areas corresponding to T2/FLAIR hyperintensities [8]. Synaptic activity is sensed by astrocytes, and the regional CBF is controlled through neuron-astrocyte communications [9]. Multifocal hyperperfusion with lactate accumulation in our case is presumed by auto-antibody-mediated neuronal hyperexcitability. These pathophysiological changes are similar to those of stroke-like episodes in MELAS, in which neuronal hyperexcitability is proposed to play an important role in the initiation of stroke-like episodes [4,5]. Therefore, it is not unexpected that neuroimaging patterns in anti-GABA<sub>A</sub>R encephalitis mimic stroke-like episodes. Although classic

stroke-like-lesion is usually single and predominantly affecting the cortex with vasogenic edema [4,5], multiple or disseminated small cortical lesions have recently been reported as a distinctive form of stroke-like lesions in MELAS [6].

This study showed consecutive changes in perfusion and metabolites in the acute brain lesions; subcortical increased T2/FLAIR signals with elevated ADC values resolved subsequently, suggesting the presence of vasogenic edema. Focal hyperperfusion on ASL and elevated lactate spectra on  $^1\text{H}$ -MRS are more likely to reflect focally increased synaptic activity in the cerebral cortex, thus, ASL-perfusion MRI and  $^1\text{H}$ -MRS may provide useful information to estimate ongoing disease activity in anti-GABA<sub>A</sub>R encephalitis. Neuronal hyperexcitability may play an important role not only in stroke-like episodes of MELAS but also in anti-GABA<sub>A</sub>R encephalitis.

#### Ethics committee

This study is a retrospective observational single case report, which does not require the approval of Institutional Review Boards in our Institute, but a written consent was obtained from the patient and family.

## Funding

This work was supported in part by the Japan Epilepsy Research Foundation (JERFTENKAN 17002, TI).

## Contribution of authors

H. Ueno: study concept or design, data acquisition, analysis or interpretation of the data, and drafting/revising the manuscript; T. Iizuka: data acquisition, analysis or interpretation of the data, and revising the manuscript; Y. Tagane: data acquisition, analysis or interpretation of the data, and revising the manuscript; F. Yamasaki: data acquisition, analysis or interpretation of the data, and revising the manuscript; Y. Akiyama: data acquisition, analysis or interpretation of the data, and revising the manuscript; N. Hosomi: analysis or interpretation of the data, and revising the manuscript; H. Maruyama: analysis or interpretation of the data, and revising the manuscript.

## Disclosure of interest

T. Iizuka received a grant from Japan Epilepsy Research Foundation.

H. Maruyama received research support from Easi, Otsuka Pharmaceutical, Sumitomo Dainippon Pharma, Daiichi Sankyo, Bayer and MSD.

The other authors declare that they have no competing interest.

## Acknowledgement

The authors would like to express their deepest appreciation to Professor Josep Dalmau in Service of Neurology, IDIBAPS Hospital Clinic, University of Barcelona, Casanova (Spain) for examining auto-antibodies against neuronal cell-surface antigens including NMDA receptor, AMPA receptor, GABA<sub>B</sub> receptor, LGI1, Caspr2, or mGluR5.

## References

- [1]. Petit-Pedrol M, Armangue T, Peng X, et al. Encephalitis with refractory seizures, status epilepticus, and antibodies to the GABA<sub>A</sub> receptor: a case series, characterisation of the antigen, and analysis of the effects of antibodies. *Lancet Neurol*. 2014;13(3):276–286, [http://dx.doi.org/10.1016/S1474-4422\(13\)70299-0](http://dx.doi.org/10.1016/S1474-4422(13)70299-0).
- [2]. Spatola M, Petit-Pedrol M, Simabukuro MM, et al. Investigations in GABA<sub>A</sub> receptor antibody-associated encephalitis. *Neurology*. 2017;88(11):1012–1020, <http://dx.doi.org/10.1212/WNL.0000000000003713>.
- [3]. O'Connor K, Waters P, Komorowski L, et al. GABA<sub>A</sub> receptor autoimmunity: a multicenter experience. *Neurol Neuroimmunol Neuroinflamm*. 2019;6(3):e552, <http://dx.doi.org/10.1212/NXI.0000000000000552>.
- [4]. Iizuka T, Sakai F, Suzuki N, et al. Neuronal hyperexcitability in stroke-like episodes of MELAS syndrome. *Neurology*. 2002;59(6):816–824, <http://dx.doi.org/10.1212/wnl.59.6.816>.

- [5]. Iizuka T, Sakai F. Pathophysiology of stroke-like episodes in MELAS: neuron-astrocyte uncoupling in neuronal hyperexcitability. *Future Neurol*. 2010;5:61–83, <http://dx.doi.org/10.2217/fnl.09.71>.
- [6]. Hongo Y, Kaneko J, Suga H, et al. A cluster of disseminated small cortical lesions in MELAS: its distinctive clinical and neuroimaging features. *J Neurol*. 2019;266(6):1459–1472, <http://dx.doi.org/10.1007/s00415-019-09283-3>.
- [7]. Ohkawa T, Satake S, Yokoi N, et al. Identification and characterization of GABA<sub>A</sub> receptor autoantibodies in autoimmune encephalitis. *J Neurosci*. 2014;34:8151–8163, <http://dx.doi.org/10.1523/JNEUROSCI.4415-13.2014>.
- [8]. Vacchiano V, Giannoccaro MP, Napolitano RP, et al. Combined brain positron emission tomography/magnetic resonance imaging in GABA<sub>A</sub> receptor encephalitis. *Eur J Neurol*. 2019;26(10):e88–e89, <http://dx.doi.org/10.1111/ene.14004>.
- [9]. Koehler RC, Roman RJ, Harder DR. Astrocytes and the regulation of cerebral blood flow. *Trends Neurosci*. 2009;32(3):160–169, <http://dx.doi.org/10.1016/j.tins.2008.11.005>.

Hiroki Ueno<sup>a,\*</sup>  
Takahiro Iizuka<sup>b</sup>  
Yuichiro Tagane<sup>a</sup>  
Fumiyuki Yamasaki<sup>c</sup>  
Yuji Akiyama<sup>d</sup>  
Naohisa Hosomi<sup>a</sup>  
Hirofumi Maruyama<sup>a</sup>

<sup>a</sup> Department of Clinical Neuroscience and Therapeutics, Graduate School of Biomedical and Health Sciences, Hiroshima University, Hiroshima, Japan

<sup>b</sup> Department of Neurology, Kitasato University School of Medicine, Sagami-hara, Japan

<sup>c</sup> Department of Neurosurgery, Graduate School of Biomedical and Health Sciences, Hiroshima University, Hiroshima, Japan

<sup>d</sup> Department of Clinical Radiology, Hiroshima University Hospital, Hiroshima, Japan

\* Corresponding author. Department of Clinical Neuroscience and Therapeutics, Graduate School of Biomedical and Health Sciences, Hiroshima University, 1–2–3, Kasumi, 734-8551 Hiroshima, Minami-ku, Japan.

E-mail addresses: [hirokiueno@hiroshima-u.ac.jp](mailto:hirokiueno@hiroshima-u.ac.jp) (H. Ueno), [takahiro@med.kitasato-u.ac.jp](mailto:takahiro@med.kitasato-u.ac.jp) (T. Iizuka), [no.name.uone@yahoo.co.jp](mailto:no.name.uone@yahoo.co.jp) (Y. Tagane), [fyama@hiroshima-u.ac.jp](mailto:fyama@hiroshima-u.ac.jp) (F. Yamasaki), [uakiyama@hiroshima-u.ac.jp](mailto:uakiyama@hiroshima-u.ac.jp) (Y. Akiyama), [nhosomi@hiroshima-u.ac.jp](mailto:nhosomi@hiroshima-u.ac.jp) (N. Hosomi), [hmaru@hiroshima-u.ac.jp](mailto:hmaru@hiroshima-u.ac.jp) (H. Maruyama)

Available online xxx