

Marked Growth of an Angiographically Occult Arteriovenous Malformation: Case Report

Takato Morioka, M.D., Shunji Nishio, M.D., Takashi Hikita, M.D., Lau Hui Chung, M.D., and Tohru Soejima, M.D.

Department of Neurosurgery (TM, SN, TH) and Stroke Unit (LHC), Kyushu Rosai Hospital, Kitakyushu, and Department of Neurosurgery (TS), University of Occupational and Environmental Health, Kitakyushu, Fukuoka, Japan

The authors report a case of an angiographically occult arteriovenous malformation (AVM) that showed a marked increase in size over a period of 7 years. The importance of accurate diagnosis, follow-up computed tomography and repeated angiography, if needed, is stressed in cases where enlargement of an occult AVM is suspected. (*Neurosurgery* 23:101-103, 1988)

Key words: Angiographically occult arteriovenous malformation, Computed tomography

INTRODUCTION

Cerebral arteriovenous malformation (AVM) is not a true neoplasm, but a congenital maldevelopment of blood vessels during an early embryonic stage. Therefore, theoretically there cannot be true growth of an AVM. Since the first description by Olivecrona and Riives (13), however, many cases with enlargement of this lesion have been reported (4, 7, 9-12, 14, 17-19, 21, 22). We report the case of a large AVM that is considered to have grown from an angiographically occult AVM over a period of 7 years.

CASE REPORT

A 15-year-old boy was found lying unconscious in a bathroom on November 16, 1975. On admission to our hospital, he was semicomatose with a right hemiparesis and signs of meningeal irritation. Lumbar puncture revealed hemorrhagic

cerebrospinal fluid. Conservative treatment was instituted, and he recovered gradually. On the 20th day after the onset of symptoms, left carotid and vertebral angiography failed to show any vascular abnormalities (Fig. 1). Neither spasm of vessels nor mass effect was demonstrated angiographically. On the 37th day after onset, the patient returned home with a mild right hemiparesis, which was improving.

In 1980, the patient developed generalized seizures followed by postictal right hemiparesis. He was readmitted to our hospital without physical and neurological deficits on March 29, 1983, at 23 years of age. Computed tomography (CT) showed a ringed, high density area with marked contrast enhancement in the left posterior frontal lobe and a linear low density area in the frontal lobe, which was considered to be the previous hematoma cavity (Fig. 2). Left carotid angiography revealed a large AVM in the left posterior frontal lobe. It was fed by branches of the left anterior and middle cerebral arteries and drained into the superior sagittal sinus

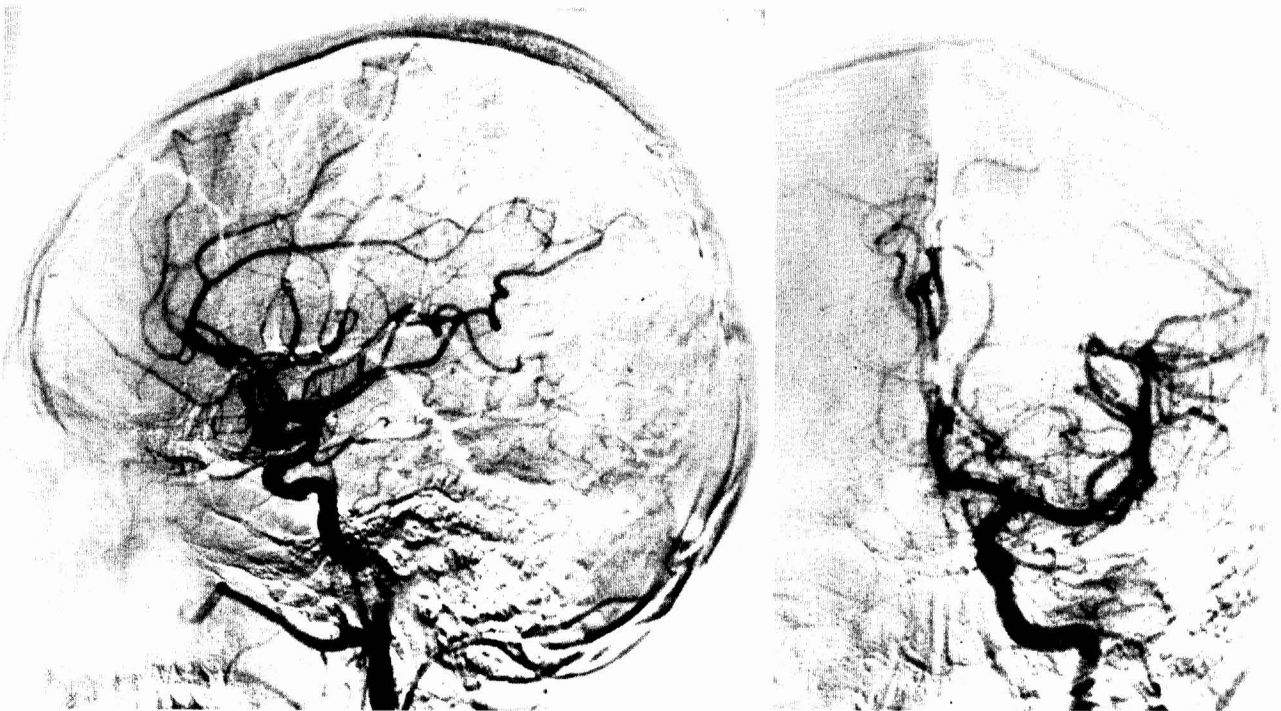


FIG. 1. Left carotid angiogram on the first admission (subtraction of venous phase). No abnormal vessels are visualized.

through cortical veins (Fig. 3). Comparing it with the previous angiogram, it was obvious that marked dilatation of the left anterior cerebral artery had occurred due to high arterial blood flow to the AVM.

On April 28, 1983, a left frontoparietal craniotomy was performed. The AVM was located in the premotor area facing the midline. After cauterization and clipping of feeding arteries (that is, the frontopolar artery, the callosomarginal artery, and a branch of the middle cerebral artery), the nidus was totally removed. During the procedure, the previous hematoma cavity was not encountered.

Postoperatively a right hemiparesis occurred; however, it gradually improved. The patient was discharged with mild impairment of skilled movements of his right hand.

DISCUSSION

The initial angiogram, performed when the patient developed subarachnoid hemorrhage, failed to demonstrate any

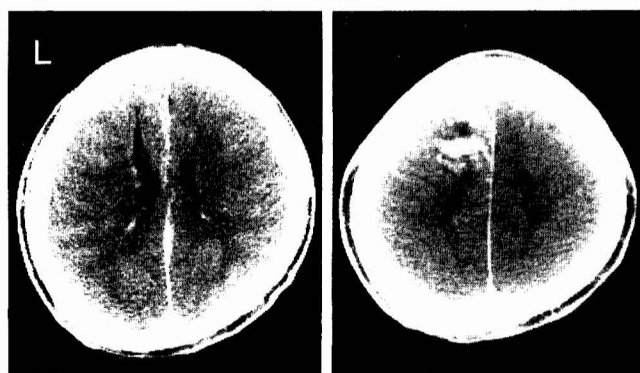


FIG. 2. CT on the second admission reveals a ringed high density area with marked enhancement and a linear low density area in the left posterior frontal lobe.

vascular abnormalities. Seven years later, however, the angiogram showed a large AVM in the frontal lobe. An AVM that is verified operatively and/or pathologically but is not detected angiographically is usually called an angiographically occult AVM. Several authors have tried to explain why angiography failed to demonstrate a vascular malformation. Some AVMs may have undergone partial or complete thrombosis, either spontaneously or secondary to hemorrhage (1-3, 6, 8, 15, 16). Several authors have suggested that the vascular malformations may either be compressed by adjacent hematoma or destroyed at the time of hemorrhage (3, 8, 23). One of the most common explanations is that some malformations are not visualized because of their small size (1, 3, 13, 20, 23), but many cases in which the AVM has grown since a previous observation have been reported. Waltimo reviewed 21 such cases and pointed out that smaller AVMs have a tendency to increase in size (21). In 1977, Krayenbühl reported almost identical observations (9). It may be possible, therefore, that initially cryptic or angiographically occult small AVMs also grow in size. In our case, the anterior cerebral artery, which was a main feeder of the nidus on the second angiogram, was larger on the second than on the first angiogram. We think that this large AVM had grown from a small cryptic AVM, as in the case reported by Watanabe et al. (22).

There are several possible mechanisms of growth or enlargement of AVMs on sequential angiograms: (a) progressive vascular dilatation or pseudoaneurysmal formation occurring as a result of repeated occult hemorrhages that destroy the extravascular neural tissues (9, 14, 21); (b) continuous hemodynamic stress causing progressive enlargement of the thin-walled, undifferentiated vessels forming the fistulous shunts of the AVM (7); (c) the presence of more room for growth, for example, in the sylvian fissure (7, 21); (d) autonomic growth (9, 19); and (e) the presence of a "reserve" nidus, which was not opacified initially and becomes visible angiographically after a change in hemodynamics (17). In our case,

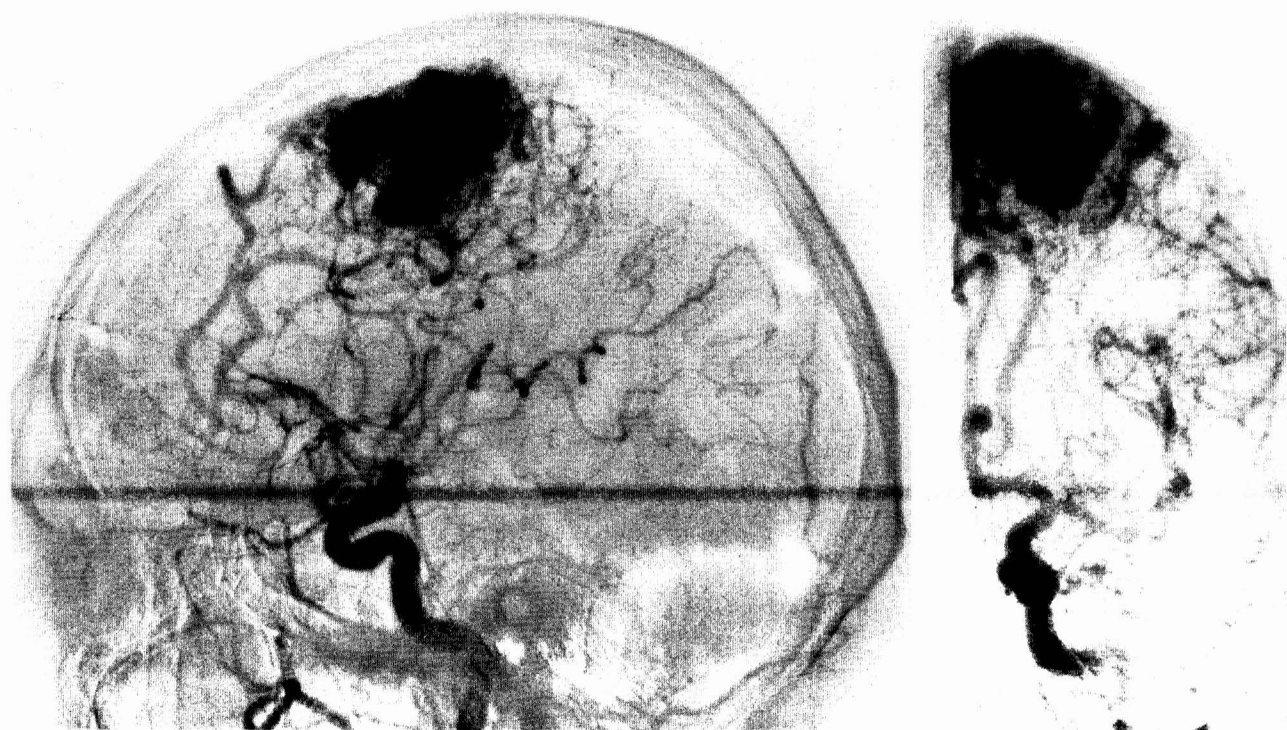


FIG. 3. Left carotid angiogram on the second admission. There is a large AVM in the posterior frontal lobe with markedly dilated feeding arteries.

repeated convulsive seizures might have indicated minor hemorrhages followed by AVM enlargement. In addition, the previous hematoma cavity might have served as an area for growth of the AVM.

Becker et al. (1) and Wilson and Martin (23) emphasized that intracerebral hematoma in young patients and in unusual locations should be explored surgically, even if angiography does not disclose a vascular lesion such as an AVM or angioma. We emphasize the importance of neuroradiological examination with CT, which usually visualizes an angiographically occult AVM as a hyperdense lesion with little or no contrast enhancement (2, 3, 5, 6, 8, 11, 15, 23). Unfortunately, our patient was initially hospitalized during our pre-CT era. He developed repeated epileptic seizures, however, which might be related to the increase in size of an initially small cryptic AVM. As in our case, follow-up CT and repeated angiography may be necessary, especially in young patients who have episodes of intracranial hemorrhage of unknown cause.

ACKNOWLEDGMENT

Greatful acknowledgement is made to Dr. K. Fujii, Department of Neurosurgery, Kyushu University, for his valuable suggestion and helpful comments.

Received for publication, November 5, 1987; accepted, December 18, 1987.

Reprint requests: Takato Morioka, M.D., Department of Neurosurgery, Neurological Institute, Faculty of Medicine, Kyushu University, 3-1-1, Maidashi, Higashi-ku, Fukuoka 812, Japan.

REFERENCES

1. Becker DH, Townsend JJ, Kramer RA, Newton TH: Occult cerebrovascular malformations: A series of 18 histologically verified cases with negative angiography. *Brain* 102:249-287, 1979.
2. Chin D, Harper C: Angiographically occult cerebral vascular malformations with abnormal computed tomography. *Surg Neurol* 20:138-142, 1983.
3. Cohen HCM, Tucker WS, Humphreys RP, Perrin RJ: Angiographically cryptic histologically verified cerebrovascular malformations. *Neurosurgery* 10:704-714, 1982.
4. Delitala A, Delfini R, Vagnozzi R, Esposito S: Increase in size of cerebral angiomas: Case report. *J Neurosurg* 57:556-558, 1982.
5. El-Gohary EM, Tomita T, Gutierrez FA, McLone DG: Angiographically occult vascular malformations in childhood. *Neurosurgery* 20:759-766, 1987.
6. Golden JB, Kramer RA: The angiographically occult cerebrovascular malformation: Report of three cases. *J Neurosurg* 48:292-296, 1978.
7. Höök O, Johanson C: Intracranial arteriovenous aneurysms: A follow-up study with particular attention to their growth. *Arch Neurol Psychiatry* 80:39-54, 1958.
8. Kramer RA, Wing SD: Computed tomography of angiographically occult cerebral vascular malformations. *Radiology* 123:649-652, 1977.
9. Krayenbühl HA: Angiographic contribution to the problem of enlargement of cerebral arteriovenous malformations. *Acta Neurochir (Wien)* 36:215-242, 1977.
10. Luessenhop AJ: Natural history of cerebral arteriovenous malformations, in Wilson CB, Stein BM (eds): *Intracranial Arteriovenous Malformations*. Baltimore, Williams and Wilkins, 1984, pp 12-23.
11. Mendelow AD, Erfurth A, Grossart K, Macpherson P: Do cerebral arteriovenous malformations increase in size? *J Neurol Neurosurg Psychiatry* 50:980-987, 1987.
12. Mori K, Murata T, Hashimoto N, Handa H: Clinical analysis of arteriovenous malformations in children. *Childs Brain* 6:13-25, 1980.
13. Olivecrona H, Riives J: Arteriovenous aneurysms of the brain: Their diagnosis and treatment. *Arch Neurol Psychiatry* 59:567-602, 1948.
14. Paterson JH, McKissock W: A clinical survey of intracranial angiomas with special reference to their mode of progression and surgical treatment: A report of 110 cases. *Brain* 79:233-266, 1956.
15. Patil AA: Angiographically occult arteriovenous malformation of the brain: A case report. *Acta Neurochir (Wien)* 58:99-104, 1981.
16. Prakash B, Beohar PC, Misra RC: Low flow (cryptic) arteriovenous malformation and spontaneous haematoma. *Acta Neurochir (Wien)* 69:61-67, 1983.
17. Sano K, Ueda Y, Saito I: Subarachnoid hemorrhage in children. *Childs Brain* 4:38-46, 1978.
18. Shenkin HA, Spitz EB, Grant FC, Kety SS: Physiologic studies of arteriovenous anomalies of the brain. *J Neurosurg* 5:165-172, 1948.
19. Spetzler RF, Wilson CB: Enlargement of an arteriovenous malformation documented by angiography: Case report. *J Neurosurg* 43:767-769, 1975.
20. Terao H, Hori T, Matsutani M, Okeda R: Detection of cryptic vascular malformations by computerized tomography: Report of two cases. *J Neurosurg* 51:546-551, 1979.
21. Waltimo O: The change in size of intracranial arteriovenous malformations. *J Neurol Sci* 19:21-27, 1973.
22. Watanabe E, Nagamune A, Masuzawa H, Sano K: A case of cerebral arteriovenous malformation with presented remarkable enlargement during 13 years. *No To Shinkei* 29:45-49, 1977 (in Japanese).
23. Wilson CB, Martin NA: Deep supratentorial arteriovenous malformations, in Wilson CB, Stein BM (eds): *Intracranial Arteriovenous Malformations*. Baltimore, Williams and Wilkins, 1984, pp 184-208.

COMMENTS

Morioka et al., in their report of a single case, document extremely well the development of an AVM in an area where none was previously demonstrated, although there had been a hemorrhage. This certainly indicates that these abnormalities, previously thought to be congenital, can be acquired, and it underscores the fact that they can grow. In this case, considerable growth was witnessed. In my personal experience, I have not had a case where an AVM was proven to be absent at one point in time and subsequently present. The growth in AVMs that we have witnessed, which occurs rarely, has generally been subtle. In this particular case, the AVM, for all intents and purposes, was nonvisualized and then appeared as a large lesion.

Bennett M. Stein
New York, New York

Dr. Morioka et al. have demonstrated another dramatic example of the enlargement of an AVM. Although numerous such cases have been identified, the growth of this lesion over a 7-year period is striking. I have thought over the past 10 years that our whole concept of arteriovenous malformations may be inappropriate. The exceedingly small rate of incidental arteriovenous malformations in large pediatric angiographic series suggests that these lesions may grow during childhood and young adulthood and are not all present at birth. The more patients with multiple arteriograms separated over years, the more it becomes apparent that arteriovenous malformations are often dynamic lesions. Certainly, this additional case highlights the dramatic changes in AVMs that may occur over time.

Robert F. Spetzler
Phoenix, Arizona