

Clinical Reports

Transient global amnesia and left frontal haemorrhage

Daniel E. Jacome¹ and Gonzalo F. Yanez²

¹*Department of Medicine, Palmetto General Hospital, Hialeah Hospital and Palm Springs General Hospital, Hialeah, Florida, and* ²*Department of Neurology, University of Miami School of Medicine, Miami, Florida, USA.*

Summary: A patient developed spontaneous, acute, dominant frontal lobe haemorrhage neighbouring on a zone of pre-existing post-traumatic encephalomalacia manifesting clinically as transient global amnesia. Amnesia can be secondary to disease of the frontal lobe, affecting pathways interconnecting the basal forebrain and hippocampus of the temporal lobe.

Introduction

Transient global amnesia (TGA) denotes rarely recurring episodes of retrograde amnesia, inability to form memories, and repetitive queries.¹⁻³ The patient is able to carry on most normal activities during the attack. If other symptoms occur, they are commonly referable to dysfunction of structures supplied by the posterior circulation. Several precipitants are recognized.⁴ We wish to report a patient with TGA secondary to an intracranial haemorrhage of an unusual location.

Case report

A 68 year old, right-handed, male factory worker was brought to the emergency room after he started acting 'strange' while eating breakfast. Initially he was irritable, uncooperative and mildly agitated. When first examined, he had no recollection of what had happened, repetitively inquired where he was, and could not form new memories. He completely recovered after 3 hours. He was left with a frontal headache and still had no recollection of the incident, only of feeling dizzy before losing his memory.

Pertinent history included head trauma 4 years previously causing a left maxillary sinus displaced

fracture associated with loss of consciousness, but with no residual neurological complications.

Routine laboratory studies were normal including standard and 24-hour electrocardiograms. Computerized tomography (CT) of the head on admission showed an acute haemorrhage affecting the anterior segments of the left superior and middle frontal gyri, and subcortical oedema impinging upon the ipsilateral gyrus rectus (Figure 1a). There was also one area of anterior superior parasagittal cystic encephalomalacia and an old displaced fracture of the left maxillary sinus (Figure 1b). An electroencephalogram (EEG) one day later showed slow wave generalized episodes, but three days following onset of symptoms, a 24-hour EEG recording was normal. Left carotid arteriography showed no aneurysms or arteriovenous malformations. CT of the head several weeks after discharge revealed resolution of the haemorrhage.

Discussion

TGA has been described in association with a variety of conditions.¹⁻³ Single examples of glioma, glioblastoma, meningioma, pituitary adenoma, and metastatic bladder carcinoma to the brain, impinging on the temporal lobe or the limbic system have been found in patients presenting with TGA.⁵⁻⁹ One individual with TGA and left temporal haemorrhage sparing the hippocampus was described.¹⁰ TGA is, therefore, a syndrome of

Correspondence: D.E. Jacome, M.D., Palmetto Medical Plaza, Suite 401, 7100 West 20th Avenue, Hialeah, Florida 33016, USA.

Accepted: 17 September 1987

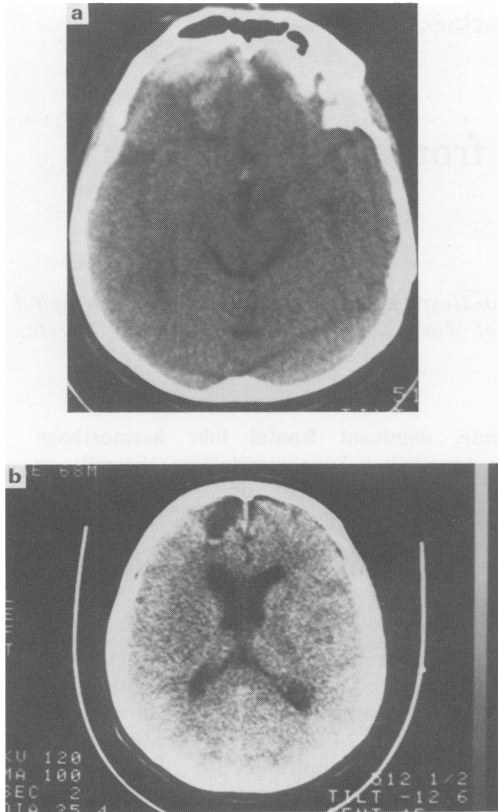


Figure 1 Non-enhanced computerized tomographies of the head. (a) Acute left frontal haemorrhage affecting the superior and middle frontal gyri with subcortical white matter oedema impinging on the ipsilateral gyrus rectus can be observed. (b) View of area of old post-traumatic encephalomalacia over the anterior parasagittal convexity of the left frontal lobe.

diverse aetiologies with most authors favouring an ischaemic pathogenesis due to posterior circulation atherosclerotic disease³ or due to migraine vasospasms.¹¹ Fewer authors support an epi-

leptiform hypothesis² often based on findings in interictal EEGs or response to anti-convulsants.¹²⁻¹³ The mechanisms implied in tumour-related TGA include focal seizures, spreading cortical depression, oedema, transient peaks of intracranial hypertension and blood flow disturbances.⁷ In the single patient with temporal lobe haemorrhage, a pathogenetic functional transient disconnection of the hippocampus was implied.¹⁰ Recently, Damasio *et al.* reported 5 patients with basal forebrain damage and permanent memory deficits.¹⁴ One patient had isolated unilateral haemorrhage of the dominant basal frontal lobe, a second had surgical resection of the same areas due to an arteriovenous malformation, and a third had ischaemic infarction in the anterior cerebral artery territory which included the caudate nucleus. However, 3 of the 5 patients had concomitant subarachnoid haemorrhage.

Our patient's atypical delayed haemorrhage mostly involved the left superior and middle frontal gyri with subcortical frontal oedema impinging over the gyrus rectus. A previously acquired cystic encephalomalacia of the anterior parasagittal convexity area was also present. The fact that this patient developed TGA rather than permanent amnesia favours an acute ischaemic or epileptic pathogenesis affecting the adjacent memory zones. Seemingly, no additional intrinsic tissue destruction occurred to account for a residual deficit, but quantitative memory testing was not performed after the ictus. Damasio *et al.* postulated a residual dysfunction of pathways interconnecting the frontal lobe and hippocampus as the ultimate mechanism leading to amnesic syndrome in their patients.¹⁴

Acknowledgement

Juan Leborgne M.D. reviewed the CT scans.

References

1. Fisher, C.M. & Adams, R.D. Transient global amnesia. *Acta Neurol Scand* 1964, **40** (suppl 9): 1-83.
2. Shuping, J., Rollinson, R. & Tolle, J. Transient global amnesia. *Ann Neurol* 1980, **7**: 281-285.
3. Miller, J.W., Petersen, R.C., Metter, E.J., Millikan, C.H. & Yanagihara, T. Transient global amnesia: Clinical characteristics. *Neurology* 1987, **37**: 733-737.
4. Fisher, C.M. Transient global amnesia. Precipitating activities and other observations. *Arch Neurol* 1982, **39**: 605-608.
5. Boudin, G., Pepin, B., Mikol, J., Haguemau, M. & Vernant, J. Gliome du systeme limbique posterieur, revele par une amnesia globale transitoire. *Rev Neurol (Paris)* 1975, **131**: 157-163.

6. Lisak, R. & Zimmerman, R. Transient global amnesia due to a dominant hemisphere tumor. *Arch Neurol* 1977, **34**: 317-318.
7. Meador, K.J., Adams, R.J. & Flanigin, H.F. Transient global amnesia and meningioma. *Neurology* 1985, **35**: 769-771.
8. Hartley, T., Heilman, K. & Garcia-Bengochea, F. A case of transient global amnesia due to a pituitary tumor. *Neurology* 1974, **58**: 998-1000.
9. Findler, G., Feinsod, M., Lijovetzky, G. & Hadani, M. Transient global amnesia associated with a single metastasis in the non-dominant hemisphere. *J Neurosurg* 1983, **58**: 303-305.
10. Landi, G., Giusti, M.C. & Guidotti, M. Transient global amnesia due to left temporal hemorrhage. *J Neurol Neurosurg Psychiatry* 1982, 1062-1063.
11. Caplan, L., Chedru, F., Lhermitte, F. & Mayman, C. Transient global amnesia and migraine. *Neurology* 1981, **31**: 1167-1170.
12. Rowan, A.J. & Protass, L.M. Transient global amnesia: clinical and electroencephalographic findings in 10 cases. *Neurology* 1979, **29**: 869-872.
13. Pritchard, P.B., Holmstrom, V.L. & Roitzsch, J.C. Epileptic amnesic attacks: differentiation from transient global amnesia and benefit from antiepileptic drugs. *Neurology* 1984, **34** (suppl 1): 161.
14. Damasio, A.R., Graff-Radford, N.R., Eslinger, P.J., Damasio, H. & Kassell, N. Amnesia following basal forebrain lesions. *Arch Neurol* 1985, **42**: 263-271.