



Case Report

Major cerebral hypoperfusion on an internal carotid loop during an otologic surgery: A case report

Florent Carsuzaa^a, Xavier Dufour^{a,d}, Tyffanie Houpert^b, Jean-Claude Ferrié^c, Michel Sapanet^{b,d}, Alexia Delbreil^{b,d,*}

^a Service ORL, chirurgie cervico-maxillo-faciale et audiophonologie, CHU de Poitiers, France

^b Institut médico-légal, CHU de Poitiers, France

^c Service de radiologie diagnostique et interventionnelle, CHU de Poitiers, France

^d Université de Poitiers, Faculté de médecine et de pharmacie, Poitiers, France

ARTICLE INFO

Keywords:

Internal carotid artery
Loop
Kinking
Cerebral hypoperfusion

ABSTRACT

An aberrant course of the internal carotid artery, such as a carotid loop or kinking, is a rare type of malformation. These malformations are typically asymptomatic, their occurrence is unpredictable, and they can exacerbate clinical disorders such as heart failure. We report the case of a seven-year-old child who died consecutively to cardiac arrest during otologic surgery for a cholesteatoma. After rapid and effective cardiopulmonary resuscitation, the child was transferred to a paediatric intensive care unit. In the following days, pronounced cerebral hypoperfusion led to the death of the child. The autopsy revealed a right carotid loop and a left carotid kink that presumably led to the cerebral hypoperfusion.

1. Background

The internal carotid arteries are a major source of blood supply to the brain along with contributions from the vertebral arteries.

An aberrant course of the internal carotid artery is thought to occur in 10% of the population; however, the incidence of variations that cause symptomatic cerebrovascular insufficiency is less high [1]. These aberrations include internal carotid loops and kinking.

2. Case report

We report the case of a seven-year-old child who had a congenital cholesteatoma of the right middle ear. At five years of age, the child underwent the first stage of surgery for exeresis of the cholesteatoma. This initial surgery did not result in either cardiac or neurological failure.

Secondarily, the child had a cholesteatoma recurrence in the right middle ear. This required a second stage of surgery, which was performed under general anaesthesia.

After one hour of surgery, the child suffered cardiorespiratory arrest. Cardiopulmonary resuscitation was performed immediately (low flow = 0 min) with cardiac massage and intravenous injection of adrenaline, resulting in renewed heart activity with ventricular

tachycardia or fibrillation. The child was then subjected to an electric shock, which resulted in the recovery of sinus rhythm after four minutes. Cardiac echocardiography was performed, and it revealed cardiogenic shock with myocardial stunning. The child was then transferred to the paediatric intensive care unit of the Poitiers university hospital.

Cardiovascular examinations did not find any cardiac arrest aetiology. The child did not have any new episodes of heart failure, thus allowing reduction of the doses of the inotropic treatment. The patient then exhibited neurological symptoms (generalised tonic-clonic seizures and was unresponsive to nociceptive stimuli).

A CT scan and an MRI were performed, which revealed the presence of ischemic lesions in the brain, predominantly in the right hemisphere, linked with major cerebral hypoperfusion. A loop of the internal right carotid and a kink in the left internal carotid were noted on the CT scan, the MRI, and the carotid ultrasound imaging (Fig. 1). The neurological status deteriorated with signs of increased intracranial pressure due to cerebral oedema (anisocoria, bradycardia, and high blood pressure). The child had reduced mobility of the limbs, was unresponsive to nociceptive stimuli, and exhibited fluctuating osteotendinous reflexes. Electroencephalograms were generally slow, non-reactive, with signs of greater distress predominating in the right side. At day 4 (D4), symptoms of brain death started to appear (hyperthermia, polyuria, fixed

* Corresponding author at: Institut médico-légal – CHU de Poitiers, 2 rue de la Milétrie – CS 90577, 86021 Poitiers Cedex, France.

E-mail address: alexia.delbreil@chu-poitiers.fr (A. Delbreil).

<https://doi.org/10.1016/j.legalmed.2019.101636>

Received 6 May 2019; Received in revised form 1 August 2019; Accepted 21 September 2019

Available online 11 November 2019

1344-6223/ © 2019 Elsevier B.V. All rights reserved.

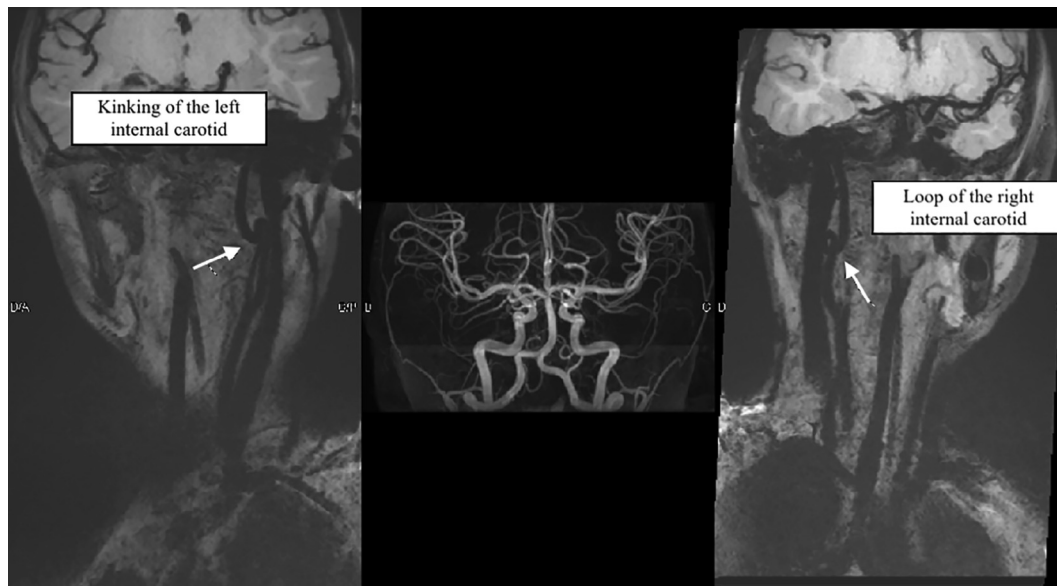


Fig. 1. MRI imaging showing a loop of the right internal carotid and a kinking of the left internal carotid.

dilated pupils, non-spontaneous ventilation, and an abnormal heart rate). After a thorough assessment of their prognosis by the medical team, the decision was made to stop all resuscitation therapeutics. The young patient died on the fifth-day post-surgery (D5).

Due to the child's death in the absence of a particular medical history, and in light of the fact that they had undergone a surgical procedure, a formal investigation was initiated, and post-mortem CT scan and a medicolegal autopsy were performed. These found stigmata of middle ear surgery, without haemorrhaging or an inflammatory state. A loop of the internal right carotid and a kink in the left internal carotid were noted (Fig. 2). There were no dysmorphic features or macroscopic malformations of the organs.

The anatomopathological examination found signs of cerebral hypoperfusion (anoxia) with smoothed circumvolutions, ischaemic neurons with nuclear pyknosis, and congestive meninges. The internal right carotid artery formed a complete loop, without artery crushing, and the internal left carotid formed an incomplete loop without artery crushing (kinking). All of the layers of the wall of the arteries were respected.

The various organs exhibited moderate levels of oedema.

The toxicological examination found traces of the resuscitation treatments.

A genetic analysis was performed in an attempt to identify a genetic mutation responsible for congenital heart arrhythmia (e.g., Brugada syndrome, congenital QT syndrome). Analysis of 51 genes failed to find a causal mutation.

Input was sought from several medical experts (an anaesthesiologist and an ENT surgeon). The principal conclusions were that this death was due to major cerebral hypoperfusion linked with the cardiac arrest (quickly resuscitated) associated with perioperative hypoperfusion. Indeed, when an otologic surgery is performed, blood pressure is typically reduced to limit bleeding. This was associated with a cervical rotation in order to facilitate the surgical procedure. These factors, associated with the internal carotid artery malformations, resulted in perioperative cerebral hypoperfusion.

3. Discussion

The incidence of tortuosities of the internal carotid artery ranges from 10 to 40%; however, the incidence of variations that cause symptomatic cerebrovascular insufficiency is between 4 and 16% [1,2]. Carotid loops or kinks constitute one type of such malformations. As a result of the loss of arterial wall elasticity due to hypertension or

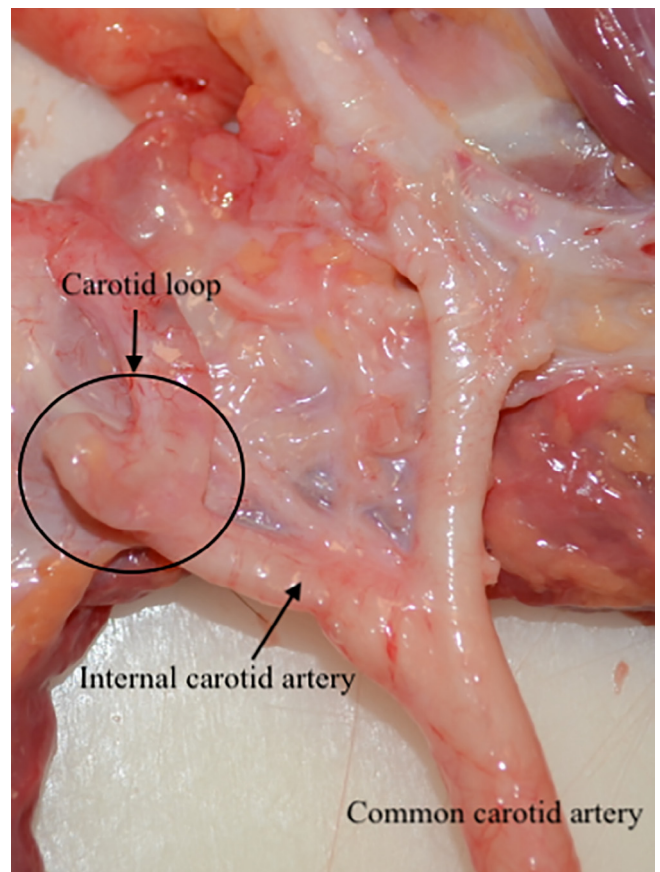


Fig. 2. Internal carotid malformations during autopsy. a: Loop of the right internal carotid artery. b: Kinking of the left internal carotid artery.

atherosclerosis, they occur more frequently in the elderly.

The internal carotid artery is derived from a coiled third aortic arch and the dorsal aortic root. Congenital tortuosity arises when uncoiling fails to take place at the embryonic stage.

It is more frequent in men (3:2), and 71% of cases occur bilaterally [1]. They mostly form at the intersection between the internal carotid artery and the XIIth cranial nerve.

The formation of a kink, which is the most frequently reported type of carotid abnormalities has been described as an acute angulation of the internal carotid artery and classified according to the severity of the angle between the two segments forming the kink [3]. Carotid kinking is present in 38% of the individuals with no history of atherosclerotic disease, diabetes, or hypertension [4].

Carotid loops are reported less frequently and they constitute a 360° loop of the internal carotid artery.

These anomalies can be associated with atherosclerotic stenosis and may be complicated by carotid dissection or aneurysmal dilatation. Coiling of the carotid artery can produce luminal narrowing, which can lead to turbulent blood flow and subsequent intimal ulceration and embolization. It is known to cause various adverse effects, including syncope, blackout, dizziness, and vertigo; it can also result in episodes of cerebrovascular insufficiency related to head positions [5].

When one of these anomalies is diagnosed, vascular imaging is necessary to determine whether there is merely looping or kinking without blood flow obstruction, or a complex malformation with obstruction of the blood flow.

The main treatment consists of surgery whereby resection of the redundant internal carotid artery is performed with reimplantation and thromboendarterectomy of any associated plaque.

To perform an otologic surgery properly, the operating position requires a contralateral cervical hyper-rotation. It may be stabilised by gelosis or sheets. An initial surgery for exeresis of a cholesteatoma can take up to three or four hours, and this position is conserved throughout the entire surgery, and the head cannot be moved because the surgery is performed under a microscope.

During an otologic surgery, reduced bleeding is necessary to identify anatomical landmarks. This is why anaesthesia for otologic surgery requires arterial hypotension. This objective is achieved by injection of adrenaline and use of a proclive position (permitting reduction of venous pressure at the operating site) under anaesthesia that is maintained with halogen derivatives (isoflurane or sevoflurane).

In this particular case, the surgery was performed on the right ear. During the surgical procedure, the head was turned to the left for greater comfort. The cerebral hypoperfusion may be explained by a reduction in the flow rate of the right carotid artery by a combination of the loop of the right carotid artery and the cervical rotation to the left. Another possible explanation could be a reduction in the flow rate of the left carotid artery due to stenosis of the left carotid artery by a

combination of the kinking and the cervical rotation to the left.

This cerebral hypoperfusion had not been noted two years prior, during the first surgery. The first assumption to explain this new event is a structural modification of these malformations during the child's development (the first surgery was performed two years prior and the internal carotid artery loop may have become more compressed over time). The second assumption is that the cervical rotation was associated with a backward arching of the neck.

4. Conclusion

The presented case shows that internal carotid loops or kinks can exacerbate clinical disorders, particularly heart failure.

The medical experts did not consider that the outcome in this case was due to medical malpractice. The relevant guidelines regarding good practice for anaesthesia, operating position, and the surgical procedures were followed. These malformations, which were fully asymptomatic in addition to being unpredictable in a young child, could not have been foreseen at the start of the surgery and it was not possible to adjust the surgery to account for these malformations.

Declaration of Competing Interest

The authors declare that they have no known competing financial interests or personal relationships that could have appeared to influence the work reported in this paper.

References

- [1] F. Paulsen, B. Tillmann, C. Christofides, W. Richter, J. Koebe, Curving and looping of the internal carotid artery in relation to the pharynx: frequency, embryology and clinical implications, *J. Anat.* 197 (Pt 3) (2000) 373–381.
- [2] G. La Barbera, G. La Marca, A. Martino, R. Lo Verde, F. Valentino, D. Lipari, et al., Kinking, coiling, and tortuosity of extracranial internal carotid artery: is it the effect of a metaplasia? *Surg. Radiol. Anat.* SRA 28 (2006) 573–580, <https://doi.org/10.1007/s00276-006-0149-1>.
- [3] H. Metz, R.M. Murray-Leslie, R.G. Bannister, J.W. Bull, J. Marshall, Kinking of the internal carotid artery, *Lancet Lond. Engl.* 1 (1961) 424–426.
- [4] C. Macchi, M. Gulisano, F. Giannelli, C. Catini, C. Pratesi, P. Pacini, Kinking of the human internal carotid artery: a statistical study in 100 healthy subjects by echocolor Doppler, *J. Cardiovasc. Surg. (Torino)* 38 (1997) 629–637.
- [5] M. Aleksic, G. Schütz, S. Gerth, J. Mulch, Surgical approach to kinking and coiling of the internal carotid artery, *J. Cardiovasc. Surg. (Torino)* 45 (2004) 43–48.