

Pure Agraphia and Gerstmann's Syndrome as a Visuospatial-Language Dissociation: An Experimental Case Study

DAVID N. LEVINE, RANJIT B. MANI, AND RON CALVANO

Neurology Services, Spaulding Rehabilitation Hospital and Massachusetts General Hospital, Boston, Massachusetts 02114; and Department of Neurology, Harvard Medical School, Boston, Massachusetts 02115

A right-handed man suffered a left parieto-occipital cerebral infarction, causing agraphia with Gerstmann's syndrome but without major aphasia, alexia, or apraxia. Oral spelling was superior to written spelling. Experiments were performed involving (1) analysis of errors in writing, (2) tasks of visual imagery, and (3) identifying letters drawn without leaving a visual trace. The results suggest that the agraphia and Gerstmann's syndrome are due to a dissociation of language skills and visuospatial skills caused by a dominant parieto-occipital lesion. © 1988 Academic Press, Inc.

INTRODUCTION

Loss of the ability to write may occur in relative isolation after brain damage (Pitres, 1884; Wernicke, 1903). Severe agraphia may be accompanied by little or no aphasia, alexia, or limb apraxia (Goldstein, 1910; Gerstmann, 1924, 1927, 1930; Herrmann and Pötzl, 1926; Lange, 1930; Klein, 1931; Zangwill, 1954; Leonhard, 1962; Dubois, Hecaen, & Marcie, 1969; Assal, Chapuis, & Zander, 1970; Kinsbourne & Rosenfield, 1974; Aimard, Devic, Lebel, Trouillas, & Boisson, 1975; Basso, Taborelli, & Vignolo, 1978; Rosati & deBastiani, 1979; Laine & Marttila, 1981; Auerbach & Alexander, 1981; Kapur & Lawton, 1983; Baxter & Warrington, 1986). Although written spelling may be severely impaired, oral spelling may be relatively preserved (Pitres, 1884; Lange, 1930; Klein, 1931; Zangwill, 1954; Dubois et al., 1969; Assal et al., 1970; Kinsbourne & Rosenfield, 1974; Aimard et al., 1975; Auerbach & Alexander, 1981; Kapur & Lawton, 1983; Baxter & Warrington, 1986).

Many patients with such isolated agraphia—that is with minimal aphasia,

Please address reprint requests to David N. Levine, Massachusetts General Hospital, Behavior Laboratory, Burnham 802, Boston, MA 02114.

alexia, or limb apraxia and relatively preserved oral spelling—show characteristic abnormalities in writing. Although able to hold a pen well and to make fairly firm strokes, they do not write fluidly, appearing uncertain about how to form letters. False starts and pauses are frequent, and the patient may give up after only a stroke or two. If he perseveres, many letters may be illegible or erroneous because of perseveration, substitution, transposition, omission, or condensation of strokes within a letter or of letters within a word. The patients may be aware of the errors, but are usually unable to correct them. Copying, although usually imperfect, is done better than writing spontaneously or to dictation, and composing words from block letters is usually impaired. The agraphia affects both hands, with similar difficulties in each. (Lange, 1930; Klein, 1931; Zangwill, 1954; Dubois et al., 1969; Assal et al., 1970; Kinsbourne & Rosenfield, 1974; Auerbach & Alexander, 1981; Kapur & Lawton, 1983; Baxter & Warrington, 1986).

Most of these patients are quite homogeneous with regard to associated cognitive abnormalities and location of the underlying lesions. The other elements of the Gerstmann syndrome—finger agnosia, right-left confusion, and acalculia—are usually present (Lange, 1930; Klein, 1931; Zangwill, 1954; Dubois et al., 1969 (Cases 1 and 3); Kinsbourne & Rosenfield, 1974), and performances on tests of visual memory and visuospatial analysis are often at least mildly impaired. The lesions, usually strokes or tumors, are localized to the parietal or parieto-occipital region of the dominant hemisphere (Lange, 1930 (Case 2); Klein, 1931; Zangwill, 1954; Dubois et al., 1969 (Cases 1 and 3); Kinsbourne and Rosenfield, 1974; Kapur & Lawton, 1983; Baxter & Warrington, 1986).

Many theories have been proposed to account for isolated agraphia. They can be grouped along two dimensions: First, some theories postulate loss of specific skills (here referred to as “center” theories, because of loss of a specific brain center), while others postulate a dissociation of skills (“dissociation” theories because two brain centers are disconnected). Second, some theories are narrow in scope, stating that the agraphia is truly isolated, while other theories are broader in scope, the agraphia being only one manifestation of a more general disorder.

Narrow-Scope Center Theories

The earliest authors (Exner, 1881; Pitres, 1884) to report isolated agraphia attributed the problem to loss of “motor memories” specific to writing. The patient had lost the stored information that mediated the movements constituting “knowing how to write.” This theory has been recently restated by Kapur and Lawton (1983). Such a theory might predict unskilled or amorphous movements affecting only writing and sparing other motor and all nonmotor skills.

Wide-Scope Center Theories

Gertmann's reports (1924, 1927, 1930) that isolated agraphia was frequently accompanied by finger agnosia, right-left confusion, and acalculia stimulated several broader explanations. Gerstmann himself believed that a disorder of "body schema" (the cerebral apparatus mediating the ability to appreciate one's body as a spatially articulated structure), localized to the hand, explained the agraphia and associated defects. The inability to name or to orient to individual fingers conferred constraints on their freedom of directed movement, causing agraphia. Klein (1931) postulated a dedifferentiation or regression of the hand to a primitive organ of prehension, like the hand of a child or an ape. Both of these views might predict primitive, unskilled, or amorphous writing, not unlike the "loss of motor memories" theory. However, the lack of skill should extend to all acts involving movements of individual fingers.

Lange (1930) explained isolated agraphia and the other elements of Gerstmann's syndrome as a loss of the "concept of direction in space." The patient could no longer adopt a stable, invariant spatial coordinate system to govern the creation of articulated forms. This theory might predict errors consisting of spatially misarticulated and maloriented forms in writing and on all other visuospatial tasks.

Wide-Scope Dissociative Theories

When Liepmann (1900) introduced the concept of apraxia, in which "motor memories" were not destroyed but were instead disconnected from other brain centers, dissociative theories of agraphia were introduced. Wernicke (1903) postulated a disconnection of visual from motor centers. Motor engrams for written letters, although intact, could not be consistently regulated by visual engrams. In terms of error type, this theory and other dissociative theories might predict the substitution of one correctly written letter for another since the motor engrams remain intact. The defect would involve not only writing, but all acts requiring visual-motor integration.

Goldstein (1910) described "amnestic apraxic" agraphia, and postulated a disconnection between the auditory language cortex and the visual cortex of the dominant hemisphere. The patient hearing the letter name could not form a visual image sufficient to write it. Defective visual imagery for letters was essential according to Goldstein's dissociative theory, whereas Wernicke's (1903) theory of visual-motor dissociation would predict intact imagery, because no auditory-visual dissociation was present.

Other language-visual dissociations similar to Goldstein's were later proposed. Kinsbourne and Rosenfield (1974) suggested that the defect in their patient was in the transformation of data from a linguistic "su-

praordinate letter selection system" into visual terms. Thus all forms of visual spelling—writing, sequencing of block letters, and typing—were impaired, but oral spelling was preserved. Margolin (1984), in discussing Kinsbourne and Rosenfield's (1974) case, adopted a similar position in classifying the disorder within an information-processing schema for writing and spelling. The linguistic processes, which generate a letter or sequence of letters in an "orthographic buffer" are preserved. The defect lies in the "physical letter code" which "specifies the acceptable (visually based) versions of the letter specified in the orthographic buffer." The physical letter code can no longer properly activate the motor programs for writing and typing, although these motor programs are preserved.

Narrow-Scope Dissociative Theories

When it became clear that isolated agraphia could be severe in the absence of limb apraxia, some of the apraxia theories became narrower in scope, postulating disconnection of motor memories for writing but not for other motor skills. Leonhard (1962) spoke of "ideokinetic agraphia," analogous to but distinct from the ideomotor apraxia of Liepmann (1900). Recently, Baxter and Warrington (1986) described "ideational agraphia" in which "access to the appropriate motor programs or sequences for producing the letter form" is impaired. Such theories might predict dissociative phenomena, such as letter-substitution errors, but restricted to writing and not involving other visuomotor skills, even other graphic activities such as drawing.

We have studied a patient with isolated agraphia in the hope of elucidating the nature of the writing difficulty. To distinguish among the various theories, we have studied the nature of the errors in writing, the performances on a variety of other graphic and visuospatial tasks, and performances in tasks of visual imagery. Our results require a new theory, synthesizing the "center" and "dissociative" views. The theory is broad in scope, explaining not only the agraphia but also the other components of the Gerstmann syndrome.

CASE REPORT

A 65-year-old right-handed man, in good health except for adult-onset diabetes mellitus, began to lose his way while driving. On a few occasions he drove on the wrong side of a divided highway. At home he uncharacteristically forgot about a fire he had lit in the fireplace. He tired easily when reading, his eyes became unusually sensitive to light, and he began to wear dark glasses. Six weeks after the onset of the symptoms, he awoke with slurred speech and right facial numbness and was admitted.

Neurologic examination was normal except for a harsh left carotid bruit and questionable mild hypalgesia of the right side of the face. A CT scan of the brain showed only a small low-density lesion of the right

putamen consistent with an old lacunar infarction. Selective left common carotid arteriography showed severe (more than 90%) stenosis of the left internal carotid artery at its origin. On his third hospital day he underwent left internal carotid endarterectomy. His postoperative course was smooth, and on discharge home neurologic examination was normal.

Five months later, he again developed slurred speech and difficulty recognizing objects by sight. On admission, there were no obvious abnormalities on neurologic examination and his CT scan was unchanged. Carotid angiography showed nearly complete occlusion of the left internal carotid artery, but during angiography he became aphasic. He received heparin for 10 days, gradually improved, and then underwent patch angioplasty of the left carotid artery with an unremarkable postoperative course. The CT scans 3 and 14 days after angiography showed evolution of a left parieto-occipital infarction (Fig. 1).

He was transferred to a rehabilitation hospital 2 weeks after surgery (1 month after the stroke during angiography). He was alert and aware that he was in a hospital because he had suffered a stroke. Speech was fluent and somewhat hesitant because of word-finding difficulty, but he could communicate his needs effectively. Repetition was intact, even for difficult phrases such as "no ifs, ands, or buts." Comprehension of conversation was good. He obeyed two-step commands but had trouble with three-step commands. He recognized visual objects but had mild difficulty naming them. For example, on one occasion he called a pen a pencil, and then he named a cup, a comb, and a thermometer correctly; but finally he called a paper napkin a "paper something." Reading was mildly impaired. Single letters were usually promptly named, but he made occasional (10%) errors. Single words, even complex ones such as "consolidate" or "expression" were always read promptly and accurately. Reading of sentences and paragraphs was hesitant, marred by occasional word substitutions, additions, and deletions. He frequently lost his place, but often corrected himself, and he complained of visual "blocking" or "fragmentation."

Agraphia was extremely severe (Fig. 2). He could not form single letters correctly, and either perseveratively reproduced the same letter or produced a nonletter form. Writing of sentences was slightly better. Occasionally, correctly formed letters and even words were produced, but the writing tended to be compressed toward the left side of the page, alignment of the word-sequence was impaired, i.e., not a uniform horizontal line, and many letters were severely disfigured. Copying of single letters was far better than writing to dictation, but occasional errors still occurred.

There was no major oral or limb apraxia. He performed even difficult movements, such as clucking his tongue and making the "tsk-tsk" sound accurately, and with either limb he demonstrated beckoning, waving good-bye, throwing a ball, saluting, and crossing himself to command

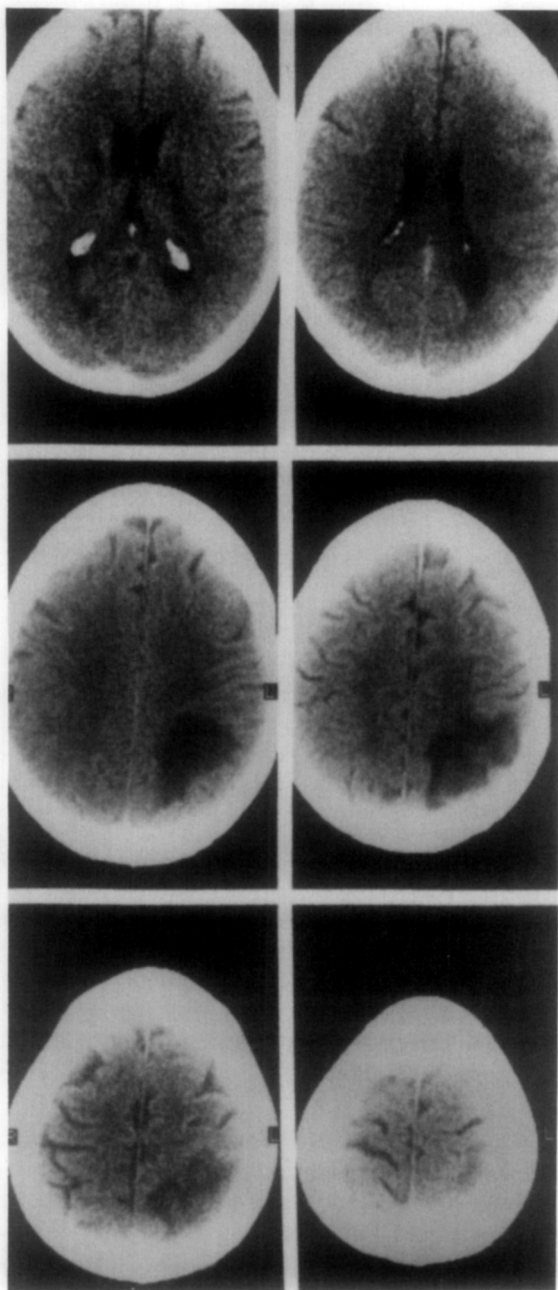


FIG. 1. CT 2 weeks after stroke. In each section the left side of the brain is to the viewer's right. The lowest section illustrated is at the top left, the second lowest section is at the top right, and the most superior section is at the bottom right. Note the infarction of the left inferior parietal lobule visible in both sections of the middle row and in the section at the bottom left. The only other visible lesion is a small infarct in the anterior limb of the right internal capsule, or the head of the caudate nucleus, in the section at the top left.




Fig. 2. Writing to dictation at 4 weeks (above) and at 11 weeks (below) after the stroke. On the left are attempts to write in print (second column) and script (third column shown only at 4 weeks) the single letters shown in the first column at the extreme left. Perseveration was prominent at 4 weeks, but improvement at 11 weeks was significant, and errors were now letter substitutions. On the right are attempts to write sentences. At 4 weeks, the line is not fully extended to the right. The dictated sentence was "The lazy dog jumped over the fence." AT 11 weeks, the writing is somewhat more legible and is not crowded to the left. Alignment of the script is still imperfect. The dictated sentence was "The weather in Boston is cooler than in New York City."

and on imitation. However, in pantomiming object use he tended to use body parts to represent tools (for example, two extended fingers to represent a scissors).

In contrast to his relatively preserved gestural abilities, he had mild difficulty using some real objects, such as a key to open a lock and a scissors to cut paper. He often began to write with the wrong end of a pen, but always corrected himself. He was severely impaired in dialing a telephone number and he also had difficulty sorting objects, such as putting different kinds of tools in separate boxes.

Finger agnosia was pronounced. For example, in pointing to named fingers, after first correctly pointing to the ring finger, he pointed to the middle when asked for the index, and to the ring finger when asked for the middle. He made errors in naming his fingers, even when encouraged to consult a life-size drawing on which the finger names were written.

Right-left confusion was also pronounced. He often showed the wrong

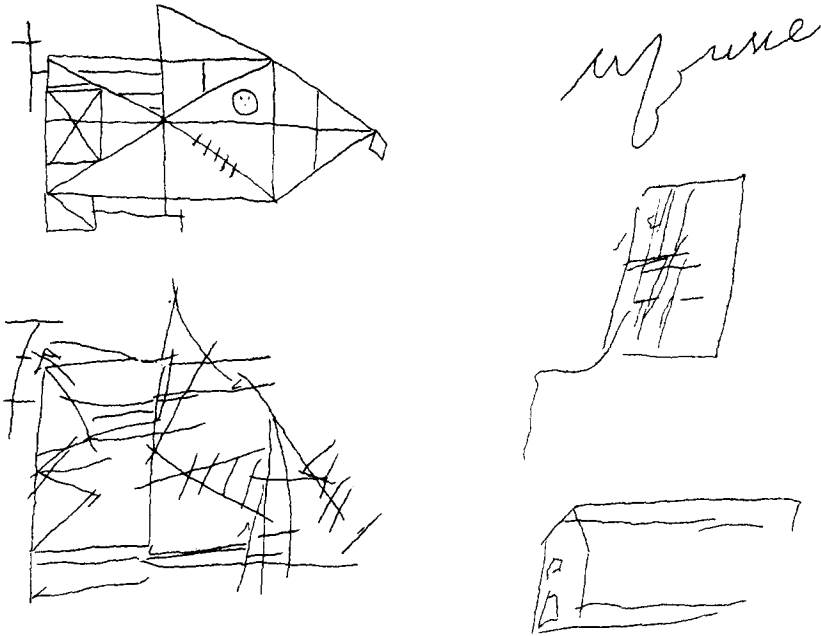


Fig. 3. Left: Copy (below) of the Rey-Osterrieth geometric figure (above). Right: Drawings from memory of a house at 4 weeks (top), 6 weeks (middle), and 10 weeks (bottom) after stroke.

side in hearing or using the words “right” and “left,” whether on his own body or on someone else’s.

Mental and written calculations were severely impaired. He was unable to solve even the simplest mental problems (such as $7 + 5$ or $9 - 4$), and he severely misread simple written calculations, perseverating both on numbers and on the arithmetic operations used in previous problems.

There was no visual agnosia. He identified objects well, even though he occasionally misnamed them. Color naming was intact. He recognized faces of people familiar to him and of celebrities.

There was significant constructional apraxia (Fig. 3). He could not copy a cube or the complex Rey-Osterrieth figure. Although mild right-spatial neglect was present in writing and in crossing out lines scattered on a page, it was evident that this spatial neglect was not the basis for the constructional difficulty.

There were no inaccuracies in reaching for visual objects. Aside from occasional mild collisions with obstacles on his right, he could find his way in his room without difficulty. There was no dressing apraxia.

Performances on standardized cognitive tests were as follows: On the Wechsler Adult Intelligence Scale (Wechsler, 1981) verbal IQ was 75

TABLE 1
 PATIENT'S PERFORMANCE ON WECHSLER ADULT INTELLIGENCE SCALE (AGE-SCALED SCORES)

	Patient		Patient
Information	7	Picture completion	7
Vocabulary	8	Picture arrangement	7
Digit span	8	Block design	6
Arithmetic	3	Object assembly	3
Similarities	6	Digit symbol	—
Comprehension	5		
Verbal IQ	75	Performance IQ	74

and performance IQ was 74 (Table 1). On the Wechsler Memory Scale (Wechsler, 1945) the (prorated) memory quotient was 72. He was severely impaired on the Hooper Visual Organization Test (Hooper, 1958). He was also severely defective in the Wisconsin Card Sorting Test (Berg, 1948).

Oral spelling, while not intact, was markedly superior to his written performances. On the oral spelling subtest of the Wide Range Achievement Test (Jastak & Jastak, 1965) he performed at a fourth grade level.

The only other abnormality on neurologic examination was a homonymous right inferior quadrantanopsia. There was no facial or limb weakness, and somatic sensation was intact.

SPECIAL STUDIES OF THE AGRAPHIA

We studied the patient longitudinally from 4 weeks after his left parieto-occipital stroke to 13 weeks after the stroke. During this period, his agraphia improved considerably (Fig. 2).

Error Analysis

We analyzed the errors of our patient in writing single letters of the alphabet to dictation. The nature of the errors changed markedly during the period of observation (Fig. 2). Initially, at 4 weeks after stroke, he only rarely wrote a letter correctly (4/26). Instead, he perseveratively reproduced the same letter with slight variations on successive trials, or he produced nonmeaningful, but letter-like shapes that also tended to recur perseveratively. Only rarely were errors spatially closely related to the correct target. However, within a week perseveration decreased notably, fewer nonletters occurred, and there were fewer errors. The errors now consisted largely of real letter forms, but not the ones corresponding to the dictated letter names. Moreover, the letter-form produced usually seemed to bear a visuospatial resemblance to the dictated letter.

To test the impression that wrong letters had a visuospatial resemblance to the correct letters, the patient's errors were analyzed in the following

way. Capital letters were divided into three groups: those composed of straight lines only, those composed of curved lines only, and those composed of a combination of straight and curved lines. Errors were classified as belonging to the same group as the correct letter or to a different group.

In two sessions 5 and 9 weeks after onset, he made 21 errors in 36 trials. Eighteen errors belonged in the same group, and only 3 were in a different group. In 2 of 3 errors belonging to a different group, the initial stroke was correct but subsequent strokes were either wrong or omitted (for example, Q was begun correctly, but was left at O).

Thus, when the agraphia was most severe, the errors were largely perseverative, and nonletter or deformed letter errors were common. As the agraphia improved, the errors were largely substitutions of visuospatially similar real letters.

Visual Imagery

We analyzed the ability of our patient to describe verbally the form of a letter of the alphabet in the absence of the printed letter itself. A letter name was dictated, and the patient was asked the following questions: Does it consist of straight lines, curved lines, or both? How many lines, straight or curved, does it have? Are there any closed loops, with either straight or curved boundaries? Are there any sharp (acute) angles? A total of 100 questions—4 per letter with the letter I omitted—was asked.

At 4 weeks after onset of his stroke, he was severely impaired, and performed at chance level. At 13 weeks following stroke, his performance had improved, and he answered 83% of the questions correctly.

Despite the difficulty he had with the task, the nature of his errors suggested that defective imagery was not the *cause* of his writing difficulty. There was no strict correlation between his ability to write the letter and his ability to answer the verbal questions about its form. For example, he might incorrectly state that an F had two lines while correctly tracing the form of an F in the air.

Other defects in visuospatial imagery were present. At 4 weeks following his stroke, he could not reliably state the direction in travelling from one major U.S. city to another even though he had traveled widely. At 8 weeks after his stroke, he performed nearly at chance level when given the names of two body parts (such as ear and shoulder, or elbow and knee) he had to state which was the higher off the ground in a standing individual. Finally, he could not state the middle letter of dictated three-letter words even though he could orally spell all of these dictated words flawlessly.

In contrast to visuospatial imagery, visual imagery for colors and faces was intact. He made few errors in naming the colors of objects from

TABLE 2
IDENTIFICATION OF LETTERS FROM GRAPHIC MOVEMENTS COMPARED TO WRITING LETTERS TO
DICTATION IN PATIENT AND CONTROLS

		Visual	Tactile	Kinesthetic	Writing to dictation
Patient	(4 weeks)	2 ^a	—	—	3
Patient	(5 weeks)	5	5	3	12
Patient	(8 weeks)	9	—	—	10
Controls		25.6 (25–26)	22.8 (17–26)	25.2 (24–26)	

^a Entries represent the number correct with a maximum score of 26.

memory and in selecting from a list the correct features of a variety of animals and of faces of celebrities.

Identification of Graphic Movements

Our patient had difficulty proceeding from a letter name (dictated to him) to the graphic production of the letter form. We attempted to ascertain whether a defect in the opposite direction was also present. Could the patient, given a graphic movement, identify the letter? Because he was able to identify single printed letters, the graphic stimulus had to leave no visible trace. We used three distinct tests—visual, tactile, and kinesthetic—and compared the patient's performances to a group of eight controls, aged 19–67, without neurologic damage.

A. Visual—The patient watched the examiner's fingertip trace out a letter on a tabletop.

B. Tactile—The patient, with eyes closed, identified a letter traced on his palm.

C. Kinesthetic—The patient, with eyes closed, identified the letter traced by his own fingertip on a tabletop as his arm was passively moved by the examiner.

The results are shown in Table 2. The patient was impaired on all of the tests, and the degree of impairment corresponded approximately to the severity of his agraphia.

The nature of the patient's errors was investigated by asking him, when he identified a letter wrongly on the visual test, to trace the form that the examiner had just traced. At 4 weeks after his stroke, he could not trace the letter-form if he could not identify it. However, when retested 8 weeks after the stroke, he successfully traced the letter that he could not identify on 10 of 12 trials.

Thus, the dissociation between letter name and graphic movements was two way. In addition to agraphia, there was a corresponding multimodal defect in the identification of graphic movements when not buttressed by a visual trace of the letter itself.

In contrast to recognition of graphic movements, there was no difficulty recognizing expressive gestures (beckoning, waving good-bye, threatening) or pantomimes of the use of tools (sawing, writing, hammering). On a test consisting of 21 such movements, he identified them all promptly and successfully.

Variations of Graphic Activity (Fig. 2)

He preferred cursive script to print, and made more errors with the less preferred mode of writing. Copying writing was better than writing to dictation or spontaneously as long as he attended carefully to the model. At 4 weeks after stroke, he copied 8/8 single printed letters successfully in the same session where he could write 0/12 to dictation. However, when given a sentence in cursive script to copy, he did not attend closely to the model. Instead, he first read the sentence and then attempted to write it as though the model were not there. The result was no better than writing to dictation.

Writing words and sentences, although faulty, was better than one would expect from his performance with single letters. For example, at a time when he could write 0/12 letters to dictation, he produced four legible words in writing a seven-word sentence. In writing sentences, the errors consisted not only of letter substitutions and distortions but also of faulty alignment of writing on the page. He crowded his writing toward the left side of the page and did not keep to a uniform horizontal line. Spacing between words was erratic.

The agraphia affected both hands. Except for more coarseness of form and diminished firmness of stroke there was no difference in writing with the nonpreferred left hand.

There was also no beneficial effect on writing by having the patient close his eyes. To assess whether visual interference by the form being created might be accounting for the errors, we compared the ability to write single letters to dictation with eyes closed to the same task with eyes open. There was no difference. Thus, the agraphia was not due to visual interference.

Composing words from block letters was impaired. At 4 weeks after his stroke, he could not select from a 4×4 array of letter cubes the single letter whose name was dictated to him. Thus, he was completely unable to select the letter cubes needed to compose a word. Even when he was given the relevant letter cubes only, so that he did not have to worry about selecting them from the array, he was often unable to put them in the correct order, although he correctly spelled the word orally. By 6 weeks after his stroke, his ability to select a single letter cube from the array had improved, but he still often sequenced the letters wrongly in composing words.

Typing was difficult, primarily because of trouble finding the desired letter on the keyboard. He had not typed previously and could not access

letters automatically, having to rely on his defective visual search. As he sought a letter, he spelled aloud the remaining letters in the word, and frequently, encountering a letter appearing later in the word, he typed it prematurely.

Scope of the Defect

The graphic defect, while most severe for alphabetic letters, was not confined to them. He could usually write single numerals to dictation, but he made errors with multidigit numbers. He was severely impaired in writing numbers with more than three digits, and he had difficulty reading them as well. He also had difficulty writing punctuation marks or arithmetic signs and drawing simple geometric figures in response to a dictated name. The errors were often substitutions of one sign or form for another; although in the early weeks after his stroke, he also made several unrecognizable shapes. As was the case in writing alphabetic characters, perseveration was often evident, and he often recognized his errors.

He also made errors in drawing more complex forms, such as objects, from memory (Fig. 3). In each case, drawings from memory were far worse than copying the same forms from a model. At 4 weeks following his stroke, he could only agraphically *write* the word *man* when asked to draw a picture of a man, and he behaved similarly when asked to draw a picture of a house (Fig. 3) or a bicycle. A week later, he no longer wrote the name of the form, but instead produced either an extremely primitive, but recognizable drawing or a primitive unrecognizable shape. By 8 weeks after stroke, his drawings were recognizable but very primitive.

DISCUSSION

The clinical features of our patient resemble those of many previously reported cases of relatively isolated agraphia. Although not entirely free of aphasia, alexia, and apraxia, these defects were quite mild, leaving the severe agraphia conspicuously isolated. Oral spelling, while not normal, was far superior to written spelling. The other features of Gerstmann's syndrome—finger agnosia, right-left confusion, and acalculia—were also present. We were fortunate to be able to study the patient's agraphia over a 2-month period after stroke, during which time it improved considerably. We were thus afforded a view of many of its features over a considerable range of severity. Cases similar to that of our patient, either early in his course or later when his agraphia improved, have been described under several labels. These include "literal agraphia" (Wernicke, 1903), "amnestic-apraxic agraphia" (Goldstein, 1910), "isolated agraphia with finger agnosia" (Gerstmann, 1927), "ideokinetic agraphia" (Leonhard, 1962), "pure agraphia" (Dubois et al., 1969), and "ideational agraphia" (Baxter & Warrington, 1986).

The Nature of the Defect

Our observations are best explained by a theory that synthesizes the "center" and the "dissociation" viewpoints. Our patient had defective visuospatial skills and hence a "center" defect. By "visuospatial skills" we mean those activities that involve the explicit, or conscious, analysis of the relative positions and orientation of objects in space or the creation of forms from components placed in a particular spatial arrangement. Thus, he had difficulty copying complex figures and he made visuospatial errors in writing. We also include under visuospatial skills, the conscious spatial analysis and synthesis of *imagined* objects or components. Thus, he was impaired in certain tasks of visuospatial imagery, such as stating the middle letter of a dictated three-letter word.

However, defective visuospatial skills caused by a damaged visuospatial "center" is not sufficiently specific to explain our patient's agraphia. In tasks that were largely independent of language skills the visuospatial defect was only partial. He could fixate visual objects, reach accurately for them, find his way about his room, and dress himself. It is not uncommon to encounter patients whose visuospatial defects in such tasks are far more severe but who do *not* have a major agraphia. In the "spatial agraphia" (Hecaen & Albert, 1978) associated with nondominant parieto-temporo-occipital lesions the letter distortions, substitutions, and perseverations observed in our patient do not occur.

We believe that the visuospatial defect in our patient, although mild for tasks not dependent upon language, was extremely severe for tasks requiring the integration of visuospatial and language skills. By "language skills" we mean speaking and comprehending speech, again both overt and mental. Our patient had no major impairment of these skills. He could speak, understand speech, and read, although there were mild difficulties with all of these. But the nearly intact language skills could not be integrated with visuospatial skills. A spoken word, such as the name of a letter, could not activate a visuospatial mechanism so the letter could be written. And a visuospatial pattern, such as a letter form drawn in the air, could not activate a language mechanism so the letter could be named. A dissociation between language skills and visuospatial skills was present. This dissociation, together with the mild defect in nonverbal visuospatial skills, is sufficient to explain our patient's agraphia.

The anatomic basis of this theory is a parieto-occipital lesion of the dominant hemisphere. This causes a visuospatial defect that varies in severity with the type of task. The defect in visuospatial skills that are independent of language is only partial, because the nondominant parieto-occipital region and its connections in the right hemisphere are intact. However, the defect in skills requiring the integration of visuospatial and language skills is maximal. Such skills require coactivation of the left

hemisphere language zone and one or both parieto-occipital regions. The *uncrossed* pathway connecting the *left* parieto-occipital region with the language zone is probably the more effective, because skills mediated by pathways confined to one hemisphere are learned more efficiently (Myers, 1965; Levine & Calvano, 1980) than skills requiring cross-hemisphere integration. This uncrossed pathway is destroyed by the left parieto-occipital lesion. The *crossed* pathway, connecting the right parieto-occipital cortex with the left hemisphere via the corpus callosum, is also partially destroyed, because the homotopical connections (Pandya & Vignolo, 1969; Jones & Powell, 1968) between the two parieto-occipital regions are destroyed by the lesion. The damaged left parieto-occipital region is thus an integral node of both the crossed and the uncrossed pathways. No mechanism to integrate visuospatial and language zones remains except for crossed connections between the nonhomologous (Pandya & Vignolo, 1969) right parieto-occipital region and the left hemisphere language zone, which, it would appear, are insufficient.

Applications of the Theory

The theory that we have proposed can explain many of the clinical and experimental observations we have made. We shall now consider (a) the nature of the patient's errors in writing, (b) his identification of graphic patterns, (c) the scope of our patient's problems, (d) his imagery defects, and (e) the variations in his competence with different types of graphic tasks.

Error Analysis

In the acute stage, errors in writing letters to dictation were dominated by perseveration, and deformed letters were common. Later in the course of recovery, substitution of spatially similar letters was the predominant type of error. We interpret the acute stage as the period when the visuospatial-language dissociation was most severe. Perseveration was the result of a complete visuospatial-language dissociation, in which the left hemisphere, deprived of all visuospatial capacity, merely activated the prepotent response, which was the letter just written. Deformations were perseverative responses, which the patient often futilely attempted to modify toward a correct response, because reading was preserved and the patient could recognize his error. Later in recovery the visuospatial-language dissociation was less severe. The left hemisphere was no longer totally deprived of visuospatial capacity and so was no longer limited to perseverative repetition of the same letter. However, visuospatial-language integration was still defective, and mild nonverbal visuospatial defects were still present. Thus, the errors consisted of letter substitutions, with the output bearing a visuospatial resemblance to the correct letters.

These error patterns would not be predicted by either the pure "center"

theories or the pure "dissociative" theories that have been previously proposed. With regard to the "center" theories, the amorphous scribbles predicted by theories of loss of "motor memories" (Pitres, 1984; Kapur & Lawton, 1983), loss of body schema (Gerstmann, 1924), or regression of hand function (Klein, 1931) did not occur. We did see deformations and visuospatial resemblances that are consistent with a pure visuospatial theory (Lange, 1930), but such a theory would not predict the perseverations, which were an integral part of the deformations or, later, the substitutions that were an integral part of the visuospatial errors. With regard to the pure dissociative theories, perseverations and substitutions are consistent with these, but such theories would not predict that errors would bear a visuospatial resemblance to the intended letters.

Identification of Graphic Forms

Our patient was not only unable to write letters of the alphabet to dictation, but he was also unable to name letters when the letter form was traced in the air or on a tabletop. In the early, severe stage, he was unable to reproduce the examiner's tracings. Later, he could reproduce the tracings fairly consistently but was still unable to name the letters.

These observations can be accounted for by the theory we have proposed. In the severe stage, the nonverbal visuospatial defect was sufficiently pronounced to impair the patient's copying the tracings. As recovery progressed and the nonverbal visuospatial defect improved, copying of the tracing could be mediated by remaining pathways at least partly within the nondominant hemisphere. This uncovered a striking dissociative defect, in which the patient could reproduce but not name the traced letter. The spatial pattern could not activate a language response, because the required visuospatial-language integration was compromised.

None of the previous theories of pure agraphia can account for the inability to name graphic tracings. A pure "center" theory cannot explain naming errors with preserved reproduction in the recovery phase, and a pure "dissociative" theory cannot explain the inability to copy the traced letters at the outset. Moreover, those theories stressing a motor or apraxic explanation, such as "loss of motor memories" (Pitres, 1884; Kapur & Lawton, 1983) or "inadequate access to motor programs" (Baxter & Warrington, 1986), cannot explain the inability to perform a task in which no motor skill was required.

Scope of the Graphic Defect

In addition to difficulty in writing letters of the alphabet to dictation, our patient committed similar errors in writing punctuation marks and in drawing geometric figures. Drawing of objects from memory (i.e., in response to hearing the name of the object) was also impaired.

This breadth of scope is consistent with our hypothesis. Each of these

tasks requires the creation of spatial forms in response to language stimuli. It is widely believed that writing evolved from drawing pictures from memory and began to diverge from drawing less than 6000 years ago (Gelb, 1966). It is therefore highly plausible that many of the same areas of the brain important in writing are also important in drawing objects from memory. Our observations are not consistent with those theories asserting that isolated agraphia results from damage to or disconnection of a brain substrate that is highly specific to the act of writing.

The Imagery Defect

Our patient had defects in some but not all tasks involving visual mental imagery. He could not answer questions about the forms of letters or the relative positions of body parts. Nor could he state the middle letter of three-letter words that he could spell easily. In contrast, imagery for the features of the faces of familiar people and for the colors of familiar objects was relatively preserved.

This pattern of performance on imagery tasks is consistent with our hypothesis of a partial visuospatial defect and a visuospatial–language dissociation. There is considerable evidence, from both clinical (Newcombe & Russell, 1969; Levine, Calvanio, & Wolf, 1980) and experimental (Ungerleider & Mishkin, 1982) literature, that two functionally and anatomically distinct cortical visual systems operate in parallel and can be damaged independently. The dorsal system, which integrates visual information with limb motor activity, is essential for visually guided movement and for the complex visuospatial skills that develop therefrom, including writing, drawing, and other constructional activities. The ventral system, integrating visual information with the more ventrally situated oral motor or limbic structures, is essential for visual recognition, and for the complex categorical skills that derive therefrom, including the multiletter visual comprehension essential for fluent reading (Levine & Calvanio, 1978, 1980). Thus, a dorsal, parieto-occipital lesion can impair writing but leave reading relatively spared, as occurred in our patient. A recent study (Levine, Warach, & Farah, 1985) has shown that the same distinction between visual recognition skills and visuospatial skills carries over into the realm of visual imagery. Imagination of visuospatial acts is impaired by bilateral dorsal parieto-occipital lesions, while imagination of faces and colors is affected by bilateral ventral temporo-occipital lesions.

We interpret the imagery defect of our patient, due to dominant hemisphere dorsal parieto-occipital damage, as a partial defect of visuospatial imagery. The defect was not as severe as in those patients with large *bilateral* dorsal parieto-occipital lesions. The imagery loss was more limited and selective, involving those spatial imagery tasks depending heavily on visuospatial-language integration. Thus, the ability to visualize

the spatial relationships of nameable components of an articulated whole—such as the letters of a word or the parts of a body—was severely impaired.

The only other theory admitting defects of imagery is that of Goldstein (1910), who postulated that language stimuli could not activate visual imagery, which was essential for writing. Goldstein, however, did not distinguish between face or color imagery and visuospatial imagery. In addition, he believed that defective activation of imagery *caused* the agraphia. Our observations indicate that this was not the case. In our patient, there was no strict correlation between the ability to describe the form of a letter and the ability to write it correctly. The defective imagery and the agraphia were thus not causally related. Instead both were manifestations of a common underlying disorder, which we suggest is a visuospatial–language dissociation coupled with a partial defect in visuospatial skills themselves.

Variations on Writing

Our patient's impairment in forming written words varied greatly with the nature of the task. Writing to dictation was more impaired than copying, which itself was partially impaired, especially if the patient did not slavishly heed the model. Composing words from block letters and typing were impaired, but not as severely as writing to dictation.

The advantage of copying over writing to dictation parallels a previous report (Hecaen & Assal, 1970) that the presence of a visual model facilitates the drawings of patients with left-hemisphere lesions but not the drawings of patients with right-hemisphere lesions. We explain these observations by suggesting that copying requires less spatial–language integration than writing to dictation and may be more fully mediated by the preserved nondominant hemisphere. However, the partial visuospatial defect caused by left parieto-occipital damage would render even copying partially impaired.

Composing a dictated word from block letters also requires language–spatial integration and was impaired. The impairment was somewhat less severe than writing to dictation in our patient, although the difference was not as marked as in some other cases (Kapur & Lawton, 1983). We believe that composing words from block letters is less impaired than writing to dictation because of the reduced demand on visuospatial skills. One need only select letters in an orderly fashion from an array, and is not required to create the letter forms. Typing too requires only the ordered selection of letters from an array and is even easier than composing words from block letters, because no manipulation of the letter is required. Only in the most severe state, early in our patient's course, were these simpler tasks completely impossible.

An Explanation of the Gerstmann Syndrome

The scope of our hypothesis extends beyond the agraphia and related disorders previously discussed. It predicts that *all* tasks involving the integration of visuospatial and language skills will be especially severely affected. In particular, it predicts the occurrence of the other elements of the Gerstmann syndrome: finger agnosia, right-left confusion, and acalculia. These were present in our patient and in others with a similar agraphia.

Finger agnosia (Gerstmann, 1924) involves the inability to name fingers on the patient's or someone else's hand. It also involves the inability to point out or show a finger given its dictated name. These two tasks require visuospatial-language integration. The fingers are distinguished from each other primarily by their spatial positions rather than by any "physiognomic" characteristics. Naming a finger is applying a linguistic label to the results of a spatial analysis, similar to naming a letter whose form is traced in the air. Showing a finger in response to its dictated name requires performing a spatial analysis in response to a linguistic stimulus, similar to writing a letter of the alphabet to dictation.

Experimental studies (Poeck & Orgass, 1969) have shown that defective finger naming and defective comprehension of finger names are highly correlated. These defects correlate less well with defects in finger identification based on matching a finger touched out of view to a schematic hand and do not correlate at all with the more purely spatial, nonverbal tests of "hand structure" of Kinsbourne and Warrington (Kinsbourne & Warrington, 1962). Poeck and Orgass (1969) interpret these results as indicating that the basis of finger agnosia (defective naming and name comprehension of fingers) is aphasia. We would reinterpret these results as suggesting that the basic defect in these cases is defective visuospatial-language integration.

A similar argument can be made that right-left confusion, as a component of Gerstmann's syndrome, is also a manifestation of defective visuospatial-language integration. The patient with Gerstmann's syndrome does not falsely lateralize objects by, for example, reaching to the left for an object on his right. Nor does he necessarily put his shoes on the wrong feet or malorient his garments, like a patient with dressing apraxia. All of these tasks, while requiring the ability to distinguish lateral directions, do not require the integration of this spatial ability with language skills. Moreover, the patient with Gerstmann's syndrome can recognize the words "right" and "left" as English words which pertain to body-centered lateral directions in space. He can repeat these words and use them to some extent in conversation. These abilities are retained because the patient is *not* severely aphasic, and these language skills do not require integration with visuospatial abilities. However, the patient with Ger-

stmann's syndrome cannot name the side of a body part which is touched, nor can he show the appropriate side of the body given the words "right" or "left." These are tasks requiring the integration of a visuospatial analysis with a language stimulus or response.

The final element of Gerstmann's tetrad, acalculia, is more complex, but it too can be understood in terms of visuospatial-language dissociation. A part of the acalculic defect in Gerstmann's syndrome is difficulty in reading and writing multidigit numbers. The numerals of such numbers have values that are determined by their spatial positions—their "place values." The patient with Gerstmann's syndrome cannot read or write multidigit numbers well because he confounds the spatial positions of the numerals. There is thus a dissociation between the name of a multidigit number and its visuospatial representation. Another part of the acalculic defect in Gerstmann's syndrome is an inability to perform the simplest of mental or written calculations, with the possible exception of a few that have been learned by rote. The ability to add or subtract simple one-digit numbers seems like a purely verbal task, but this is deceiving. It is generally acknowledged that numbers were historically first represented by repeated lines or notches (Smith & LeVeque, 1966), and calculations involved the joining or separation of such spatial arrays. Only later did special symbols evolve for certain of these arrays, such as V (an open hand) for 5 or X (two hands) for 10. Ontogenetically, too, the calculations of the young child usually involve the display of selected fingers that are joined to or removed from others. Arithmetic skills are therefore not only verbal but also spatial. They involve the combination of two or more verbal items to yield another, equivalent, verbal item by means of an explicit or implicit rearrangement of spatially extended elements. Verbal and visuospatial skills must be integrated.

Thus, visuospatial-language dissociation can cause Gerstmann's syndrome. But when present, it will cause more than just Gerstmann's tetrad. Defective drawing of shapes and objects from memory, impaired performance on some tests of visuospatial imagery, and other disabilities discussed previously will also be present. Furthermore, mild to moderate defects in the purely visuospatial realm will also be present, because the left-parieto-occipital lesion leaves only the nondominant parieto-occipital region for tasks of spatial analysis. Thus, Benton (1961), in questioning the cohesiveness of the Gerstmann syndrome, pointed out that defects in constructions and in visual memory for geometric shapes were as highly correlated with the Gerstmann symptoms as the Gerstmann symptoms were with each other.

We do not propose that visuospatial language dissociation is the *only* cause of Gerstmann's tetrad. Either severe nonverbal visuospatial difficulty or marked aphasia can cause impairment in all of the tasks comprising Gerstmann's tetrad. Each of these conditions will be associated with its

own distinctive pattern of errors and associated defects. We do believe, however, that when aphasia and alexia are minimal and nonverbal visuospatial defects are mild, that Gerstmann syndrome associated with a dominant parieto-occipital lesion (as in the patients originally described by Gerstmann) is caused by visuospatial–language dissociation.

The Preservation of Reading and Praxis

The theory of visuospatial–language dissociation, if it is to be taken seriously, must account not only for the functions that were impaired but also for those that were preserved. Two of the most conspicuous of the relatively preserved functions, in our patient and in previously reported cases, were reading and praxis.

In reading, our patient had little difficulty identifying letters and no difficulty identifying words. We have previously alluded to the evidence that these capacities are mediated by a separate, more ventrally situated pathway. However, it is still necessary to question why this is so, because reading letters and words does involve the integration of visual and language skills.

We believe that the reason reading of words was spared is that the visual process in reading words is different from the visual process that is affected in Gerstmann's syndrome. The process affected in Gerstmann's syndrome is explicit *spatial analysis and synthesis*. This involves assessing the locations of an item in an array or constructing an item by putting elements into specific spatial relationships. In contrast, the prevailing visual process in reading words is *identification or closure*. The subject gets an overview of the word as a whole, in a single glance, without performing an explicit spatial analysis or synthesis. There is evidence that closure and spatial analysis are two distinct aptitudes in the normal population (Ekstrom, French, & Harman, 1976) and that they are mediated by distinct neural systems (Newcombe & Russell, 1969; Levine et al., 1980, 1985).

Although many alternative hypotheses can be entertained, the behavior of our patient in various reading tasks supports the above view. It might be postulated, for example, that identifying printed words does not involve knowledge of body structure (Gerstmann, 1927) as do the functions that are compromised in Gerstmann's syndrome. Or the representation of visual words in the brain might be thought highly material-specific and distinct from the representation of elements critical to calculation or finger knowledge. Against these views is the observation that with identical stimulus material, our patient could succeed or fail depending upon the task. If asked to *identify* a word or a single letter, he was successful. If asked for a *spatial analysis or synthesis*, he failed. He could not select a named letter from an array, find the middle letter of a word, or sequence block letters to construct a word.

The observation that our patient had much more difficulty reading multidigit numbers than words is also of significance. The digits of a multidigit number can be spatially permuted in any manner and still form a meaningful number. In contrast, the letters of a word usually admit to few if any spatial permutations to remain meaningful. Thus, reading numbers may require more spatial ability than reading words. It would be of interest to see if patients such as ours had more difficulty identifying words that were highly spatially permutable (e.g., post) than words which were not (e.g., port).

Praxis was also relatively preserved in our patient, at least in so far as it involved meaningful gestures to spoken command or imitation. Like the identification of printed words, the performance of familiar gesture does not involve explicit, conscious spatial analysis or synthesis. When one is asked to make a fist or salute, it is done without any explicit spatioconstructive activity. While a *theory* of gesture may require gestures to be "constructed" of more simple elements in spatiotemporal sequence, such construction has no conscious counterpart. A child of 3–4 years has a large repertoire of gestural praxis with extremely primitive capacity for explicit spatial analysis and synthesis (Piaget & Inhelder, 1967). Thus, it is not surprising that the performance and comprehension of familiar gestures is spared with visuospatial–language dissociation.

In contrast to such familiar gestures, our patient was mildly impaired in some tasks involving the use of actual objects. The errors that were observed, such as initially holding a pen upside down, were clearly visuospatial in nature and consistent with the mild nonverbal visuospatial defect we have postulated.

In other tasks involving the use of actual objects, our patient was severely impaired. These included dialing a telephone and sorting objects (such as tools) by category. It is interesting to compare these activities with an equally complex but preserved activity such as dressing. Dialing and sorting involve sequential accessing of positions in a spatial array that are determined by the (verbal) identity of a numeral or object, respectively. Like showing the position of a finger on a hand in response to the dictated finger name, it is a task that requires visuospatial–language integration. In contrast, the ability to put on a robe or a pair of pants may involve even more complex spatial analysis in orienting the garment to the body. However, the spatial activity need not be integrated with verbal activity as in dialing or sorting.

Thus, the pattern of errors in motor skills is consistent with our theory. Gesture, which is not a conscious spatial activity, is relatively preserved; so ideomotor apraxia is minimal. The nature of the errors in handling objects is consistent with a mild nonverbal visuospatial defect. The severe impairment in dialing and sorting with relative preservation of dressing is attributable to loss of visuospatial–language integration even though nonverbal visuospatial skills are only mildly affected.

Neuroanatomic Qualifications

Our patient had a cerebral infarction in the left parieto-occipital region of the dominant hemisphere, as required by the theory we have proposed. However, there was also a small infarct in the putamen of the right hemisphere. We do not believe that the latter infarct played a significant role in our patient's clinical picture. First, it was present on the initial CT scan 5 months before his parietal stroke, and at that time there was no agraphia or Gerstmann's syndrome. Second, the left parieto-occipital lesion in our case is similar in location to the lesions of previously reported patients with agraphia and Gerstmann's syndrome who did not necessarily have other lesions (Critchley, 1953). Despite the evidence to the contrary, however, we cannot definitively exclude some role of the small right putamenal lesion, probably of a "permissive" or "synergistic" nature, in our patient's symptoms.

Our theory of isolated agraphia is limited to those cases with parieto-occipital lesions, in whom the agraphia is generally accompanied by other elements of the Gerstmann syndrome. Isolated agraphia has also been reported in association with other lesions of the dominant hemisphere, including the parietal lobe white matter more anteriorly—at the level where the arcuate fasciculus intersects the somatosensory radiations (Wernicke, 1903)—and the foot of the second frontal gyrus (Exner, 1881). Indeed, Hermann and Pötzl (1926) proposed an arciform cerebral region, corresponding roughly to the distal vascular fields of the superior division of the middle cerebral artery, from the parieto-occipital region posteriorly to the foot of the second frontal gyrus anteriorly, that participates in mediating writing. It is unlikely that a single theory can account for all of the agraphias that can result from lesions in this extensive territory. For example, the patient of Aimard et al. (1975) had isolated agraphia characterized primarily by lack of impulse to write, without the perseverations, distortions, and substitutions of letters seen in our patients. Their patient was presumed to have a lesion of the second frontal gyrus. A full understanding of the possible varieties of isolated agraphia requires further studies.

REFERENCES

- Aimard, G., Devic, M., Lebel, M., Trouillas, P., & Boisson, D. 1975. Agraphic pure (dynamique?) d'origine frontale. *Revue Neurologique*, **131**(7), 505–512.
- Assal, G., Chapuis, G., & Zander, E. 1970. Isolated writing disorders in a patient with stenosis of the left internal carotid artery. *Cortex*, **6**, 241–248.
- Auerbach, S. H., & Alexander, M. P. 1981. Pure agraphia and unilateral optic ataxia associated with a left superior parietal lobule lesion. *Journal of Neurology, Neurosurgery and Psychiatry*, **44**, 430–32.
- Basso, A., Taborelli, A., & Vignolo, L. A. 1978. Dissociated disorders of speaking and writing in aphasia. *Journal of Neurology, Neurosurgery and Psychiatry*, **41**, 556–563.

- Baxter, D. M., & Warrington, E. K. 1986. Ideational agraphia: A single case study. *Journal of Neurology, Neurosurgery and Psychiatry*, **49**, 369–74.
- Benton, A. L. 1961. The fiction of the Gerstmann syndrome. *Journal of Neurology, Neurosurgery and Psychiatry*, **24**, 176–181.
- Berg, E. A. 1948. A simple objective test for measuring flexibility of thinking. *Journal of General Psychology*, **39**, 15–22.
- Critchley, M. 1953. *The parietal lobes*. New York: Hafner Press. Pp. 203–224.
- Dubois, J., Hecaen, H., & Marcie, P. 1969. L'agraphie "pure." *Neuropsychologia*, **7**, 271–286.
- Ekstrom, R. B., French, J. W., & Harman, H. H. 1976. *Manual for kit of factor-referenced cognitive tests*. Princeton, NJ: Educational Testing Service.
- Exner, S. 1881. *Untersuchungen über die Lokalisation der Funktionen in der Grosshirnrinde des Menschen*. Vienna: Wilhelm Braumüller.
- Gelb, I. J. 1966. Writing. In *Encyclopedia Britannica*. Chicago: Encyclopedia Britannica. Vol. 23, pp. 813–815.
- Gerstmann, J. 1924. Fingeragnosie: Eine umschriebene Störung der Orientierung am eigenen Körper. *Wiener Klinische Wochenschrift*, **37**, 1010–12.
- Gerstmann, J. 1927. Fingeragnosie und isolierte Agraphie-ein neues Syndrom. *Zeitschrift für die gesamte Neurologie und Psychiatrie*, **108**, 152–177.
- Gerstmann, J. 1930. Zur Symptomatologie der Hirnlasionen im Übergangsgebiet der unteren Parietal- und mittleren Occipital Windung. *Nervenarzt*, **3**, 691–695.
- Goldstein, K. 1910. Über eine amnestische Form der apraktischer Agraphie. *Neurologisches Zentralblatt*, **29**, 1252–55.
- Herrmann, G. V., & Pötzl, O. 1926. Über die Agraphie. *Abhandlungen aus der Neurologie, Psychiatrie, Psychologie, und ihren Grenzgebieten*, **35**, 1–380.
- Hecaen, H., & Albert, M. L. 1978. *Human neuropsychology*. New York: Wiley. Pp. 66–67.
- Hecaen, H., & Assal, G. 1970. A comparison of constructive deficits following right and left hemispheric lesions. *Neuropsychologia*, **8**, 289–304.
- Hooper, H. E. 1958. *The Hooper visual organization test manual*. Los Angeles: Western Psychological Services.
- Jastak, J. F., & Jastak, S. R. 1965. *The wide range achievement test manual*. Wilmington, DE: Guidance Associates.
- Jones, E. G., & Powell, T. P. S. 1968. The commissural connexions of the somatic sensory cortex of the cat. *Journal of Anatomy*, **103**, 433–455.
- Kapur, N., & Lawton, N. F. 1983. Dysgraphia for letters: A form of motor memory deficit? *Journal of Neurology, Neurosurgery and Psychiatry*, **46**, 573–575.
- Kinsbourne, M., & Rosenfield, D. B. 1974. Agraphia selective for written spelling: An experimental case study. *Brain*, **1**, 215–225.
- Kinsbourne, M., & Warrington, E. K. 1962. A study of finger agnosia. *Brain*, **85**, 47–66.
- Klein, R. 1931. Zur Symptomatologie des Parietallapens. *Zeitschrift für die gesamte Neurologie und Psychiatrie*, **10**, 590–608.
- Laine, T., & Marttila, R. J. 1981. Pure agraphia: A case study. *Neuropsychologia*, **19**, 311–316.
- Lange, J. 1930. Fingeragnosie und Agraphie. *Monatschrift für Psychiatrie und Neurologie*, **76**, 129–188.
- Leonhard, K. 1962. Das Bild der ideokinetischen Agraphie. *Deutsche Zeitschrift für Nervenheilkunde*, **183**, 502–516.
- Levine, D. N., & Calvanio, R. 1978. A study of the visual defect in verbal alexia-simultanagnosia. *Brain*, **101**, 65–81.
- Levine, D. N., & Calvanio, R. 1980. Visual discrimination after lesion of the posterior corpus callosum. *Neurology*, **30**, 21–30.

- Levine, D. N., Calvaneo, R., & Wolf, E. 1980. Disorders of vision following bilateral posterior lesions. *Psychological Research*, **41**, 217-234.
- Levine, D. N., Warach, J., & Farah, M. 1985. Two visual systems in mental imagery: Dissociation of "what" and "where" in imagery disorders due to bilateral posterior cerebral lesions. *Neurology*, **35**, 1010-1018.
- Liepmann, H. 1900. Das Krankheitsbild der Apraxie ("motorischen asymbolie"). *Monatschrift fur Psychiatrie und Neurologie*, **8**, 15-44, 102-132, 181-197.
- Margolin, D. I. 1984. The neuropsychology of writing and spelling: Semantic, phonological, motor, and perceptual processes. *The Quarterly Journal of Experimental Psychology*, **36A**, 459-489.
- Myers, R. E. 1965. The neocortical commissures and interhemispheric transfer of information. In E. G. Ettliger (Ed.), *Functions of the corpus callosum*. Boston: Little, Brown. Pp. 1-17.
- Newcombe, F., & Russell, W. R. 1969. Dissociated visual perceptual and spatial deficits in focal lesions of the right hemisphere. *Journal of Neurology, Neurosurgery and Psychiatry*, **32**, 73-81.
- Pandya, D. P., Vignolo, L. A. 1969. Interhemispheric projections of the parietal lobe in the Rhesus monkey. *Brain Research*, **15**, 49-65.
- Piaget, J., & Inhelder, B. 1967. *The child's conception of space*. New York: Norton.
- Pitres, A. 1884. Considerations sur l'agraphie. *Revue de Medicine (Paris)*, **4**, 855-873.
- Poeck, K., & Orgass, B. 1969. An experimental investigation of finger agnosia. *Neurology*, **19**, 801-807.
- Rosati, G., & deBastiani, P. 1979. Pure agraphia: A discrete form of aphasia. *Journal of Neurology, Neurosurgery and Psychiatry*, **42**, 266-269.
- Smith, D. E., & LeVeque, W. J. 1966. Numerals and numeral systems. In *Encyclopedia Britannica*. Chicago: Encyclopedia Britannica. Vol. 16, pp. 756-760.
- Ungerleider, L. G., & Mishkin, M. 1982. Two cortical visual systems. In D. I. Ingle, M. A. Goodale, & R. J. W. Mansfield (Eds.), *Analysis of visual behavior*. Cambridge, MA: MIT Press. Pp. 549-586.
- Wechsler, D. 1981. *WAIS-R manual*. New York: Psychological Corp.
- Wechsler, D. 1945. A standardized memory scale for clinical use. *Journal of Psychology*, **19**, 87-95.
- Wernicke, C. 1903. Ein Fall von isolierter Agraphie. *Monatschrift Fur Psychiatrie und Neurologie*, **13**, 242-265.
- Zangwill, O. L. 1954. Agraphia due to a left parietal glioma in a left-handed man. *Brain*, **77**, 510-520.