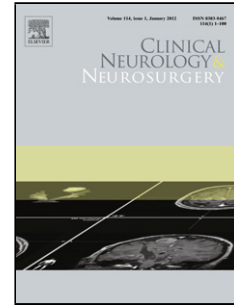


Journal Pre-proof

Hemiballism: unusual clinical manifestation in three patients with frontoparietal infarct

Masina Cotroneo, Antonio Ciacciarelli, Domenico Cosenza, Carmela Casella, Cristina Dell'Aera, Francesco Grillo, Maria Carolina Fazio, Paolino La Spina, Rosa Fortunata Musolino



PII: S0303-8467(19)30408-1
DOI: <https://doi.org/10.1016/j.clineuro.2019.105612>
Reference: CLINEU 105612
To appear in: *Clinical Neurology and Neurosurgery*
Received Date: 27 September 2018
Revised Date: 9 October 2019
Accepted Date: 13 November 2019

Please cite this article as: Cotroneo M, Ciacciarelli A, Cosenza D, Casella C, Dell'Aera C, Grillo F, Fazio MC, La Spina P, Musolino RF, Hemiballism: unusual clinical manifestation in three patients with frontoparietal infarct, *Clinical Neurology and Neurosurgery* (2019), doi: <https://doi.org/10.1016/j.clineuro.2019.105612>

This is a PDF file of an article that has undergone enhancements after acceptance, such as the addition of a cover page and metadata, and formatting for readability, but it is not yet the definitive version of record. This version will undergo additional copyediting, typesetting and review before it is published in its final form, but we are providing this version to give early visibility of the article. Please note that, during the production process, errors may be discovered which could affect the content, and all legal disclaimers that apply to the journal pertain.

© 2019 Published by Elsevier.

Hemiballism: unusual clinical manifestation in three patients with frontoparietal infarct.

Masina Cotroneo^{1*}, Antonio Ciacciarelli¹, Domenico Cosenza¹, Carmela Casella¹, Cristina Dell'Aera¹, Francesco Grillo¹, Maria Carolina Fazio¹, Paolino La Spina¹, Rosa Fortunata Musolino¹.

¹Department of Clinical and Experimental Medicine, University of Messina, Messina, Italy

* Corresponding author: Masina Cotroneo, cotroneomasina@gmail.com, Stroke Unit, University Hospital of Messina "G. Martino", via Consolare Valeria 1 - 98124 Messina (ME).

Highlights

- Hemiballism was considered a sign of a lesion in the subthalamic nucleus
- We described cases of hemiballism with no lesions of subthalamic nucleus
- The frontoparietal cortex may be involved in the genesis of hemiballism

Keywords

- Hemiballism; Hemichorea; Movement disorder; Hyperdirect way; Frontoparietal cortex, acute stroke.

Introduction

Hemiballism is a rare movement disorder characterized by involuntary movements, often violent, described as uncontrollable jerking, flinging, flailing or kicking, involving proximal muscles of a limb. The involvement of distal extremities with continuous jerking movements on one side only usually defines hemichorea. Given the overlap between these conditions the term hemichorea-hemiballism (HCHB) is often preferred.

The acute development of HCHB has been associated with lesions in the contralateral basal ganglia and subthalamic nucleus (STN). Possible involvement of frontoparietal lobes, thalamus, internal capsule, and cerebellar lobes have also been reported [1].

Many different diseases, such as vascular lesions, infections, cancers, demyelinating lesions, head trauma, neurodegenerative disorders, metabolic disorders, and drugs can cause a lesion in those structures and lead to HCHB. Among these, vascular lesions and nonketotic hyperglycemia are the most frequent [1–2]. However, acute stroke rarely manifests with HCHB, leading to a delay in the proper diagnosis and prompt treatment.

Case reports

We describe three cases of acute onset of HCHB with similar radiological features of frontoparietal abnormalities in the Diffusion-Weighted Imaging (DWI) MRI sequences.

CASE no. 1

A 64-year-old man presented to the emergency department with sudden onset of involuntary movements on the proximal left arm and leg, on the left side of the face and the left side of the trunk. Past medical history was significant for type 2 diabetes mellitus, coronary artery disease, and peripheral artery disease.

Nonketotic hyperglycemia was ruled out. Brain MRI showed DWI hyperintensity in the right frontoparietal region (Fig. 1 a, b). We performed carotid ultrasound that showed evidence of internal carotid plaque ulceration on the right side, subsequently confirmed by Magnetic Resonance Angiography (MRA) (Fig. 1 c).

The patient was treated with recombinant tissue plasminogen activator (rtPA, 0,9mg/kg). The involuntary movements disappeared within one hour from the infusion. After 24 hours the patient was transferred to the vascular surgery unit and underwent internal carotid endarterectomy with no further complications. No further presence of abnormal movements was observed.

CASE no.2

A 76-year-old man presented dysarthria, mild left facial-brachial hemiparesis, and mild left dysmetria at the finger to nose. Past medical history was significant for chronic atrial fibrillation treated with Acenocoumarol, previous stroke (20 years earlier) and previous infarct to the left lower limb. Brain CT scan did not show any significant alterations.

24 hours after his initial presentation, the patient presented involuntary flinging movements on his left arm and leg that spontaneously resolved one day after. Brain CT scan performed after 24 hours showed a hypodensity area in the right frontoparietal and insular cortex and left parietal area. Carotid ultrasound showed fibrocalcific plaques on both internal carotid artery bifurcations with 35% stenosis on the right side and 40% stenosis on the left side. Brain MRI (Fig. 2 a, b) revealed some hyperintense lesions, in the DWI sequences affecting the right frontoparietal and insular cortex and an old posterior left parietal lobe infarction.

The patient was treated with direct oral anticoagulant (DOAC) at discharge. No further presence of abnormal movements was observed.

CASE no.3

A 76-year-old woman presented to the ER after a fall, subsequent to a sudden onset of violent involuntary movements of right upper extremity. She was affected by chronic atrial fibrillation treated with Acenocoumarol, arterial hypertension, dyslipidemia, aortic and mitral valve insufficiency.

Brain CT scan did not show any significant alterations. Brain DWI-MRI (Fig 3 a, b) showed some small hyperintense lesions in the left frontal-parietal-insular cortex and other small lesions in the right frontoparietal cortex on FLAIR weighted imaging.

After 48 hours the involuntary flinging movements spontaneously resolved.

Discussion

Acute HCHB is a rare hyperkinetic movement disorder. We presented three cases of acute onset of HCHB with a lesion in the frontoparietal area documented by DWI-MRI.

Originally, HCHB was considered as a pathognomonic sign of a lesion in the STN. The pathophysiological mechanism was proposed as a result of numerous experimental studies in which the loss of an excitatory subthalamic influence on the internal segment of the globus pallidus causes the characteristic movement disorder. However, in the following years, some cases of HCHB have been described with no lesions involving the STN [3–4], questioning the exclusivity of this mechanism. The well-studied direct and indirect pathways are considered central in the genesis of the movement. However, alongside the two aforementioned pathways, the “hyperdirect” way, in which the cortical signal reach directly the STN, has acquired increasing relevance in understanding voluntary movements initiated by cortical mechanisms [5], without the involvement of the striatum. Thus, a lesion in this way, especially in the frontoparietal cortex, may be one possible mechanism of HCHB disorder, and for the manifestation of the three presented cases.

However, caution is needed regarding the independent role of the frontoparietal region in the genesis of HCHB, since defect of perfusion in the basal ganglia without evident lesions on MRI have been identified in the study by Hwang and collaborators [4]. The carotid stenosis, indeed, especially on case no.1, may have been responsible for a defect of perfusion on the basal ganglia and STN, and contributed to the genesis of the symptom.

As previously studied [2], patients with cortical infarct have a better outcome compared with those with STN infarct. All our patients recovered completely during the hospital stay. The patient treated with intra-venous rt-PA presented immediate regression of the symptoms after the infusion. On the other hand, the other two patients recovered within 48 hours. However, we believe that an acute onset of HCHB should lead to rule out an acute stroke, considering the well-established and time-dependent benefit of the reperfusion therapies.

Conclusion

We presented three cases of unusual manifestation of acute stroke, with MRI-documented lesion in the frontoparietal region. For fast management and fast treatment, acute onset of HCHB should lead to think to an acute stroke. These cases also support the evidence of a role of the frontoparietal region in the genesis of the HCHB disorder, as suggested by others [3]. However, the independent role is difficult to determine, and further studies are needed to elucidate the debate.

Declarations of interest: None

Funding: This research did not receive any specific grant from funding agencies in the public, commercial, or not-for-profit sectors.

References

1. R. B. Postuma & A. E. Lang, Hemiballism: Revisiting a classic disorder. *Lancet Neurology*, **2** (2003) 661–668. [https://doi.org/10.1016/S1474-4422\(03\)00554-4](https://doi.org/10.1016/S1474-4422(03)00554-4).
2. S. Chung, J.-H. Im, M. Lee, & J. Kim, Hemichorea after stroke: Clinical-radiological correlation. *Journal of Neurology*, **251** (2004) 725–9. <https://doi.org/10.1007/s00415-004-0412-5>.
3. A. Daoud, P. Chand, & S. Cruz-Flores, Segmental ballism due to acute ischemic lesions of the caudate nucleus and parietal lobe: Case report and review of the literature. *Clinical Neurology and Neurosurgery*, **113** (2011) 898–900. <https://doi.org/10.1016/j.clineuro.2011.05.010>.
4. K. J. Hwang, I. K. Hong, T. B. Ahn, S. H. Yi, D. Lee, & D. Y. Kim, Cortical hemichorea-hemiballism. *Journal of Neurology*, **260** (2013) 2986–2992. <https://doi.org/10.1007/s00415-013-7096-7>.
5. A. Nambu, A new dynamic model of the cortico-basal ganglia loop. *Progress in Brain Research*, **143** (2004) 461–466. [https://doi.org/10.1016/S0079-6123\(03\)43043-4](https://doi.org/10.1016/S0079-6123(03)43043-4).

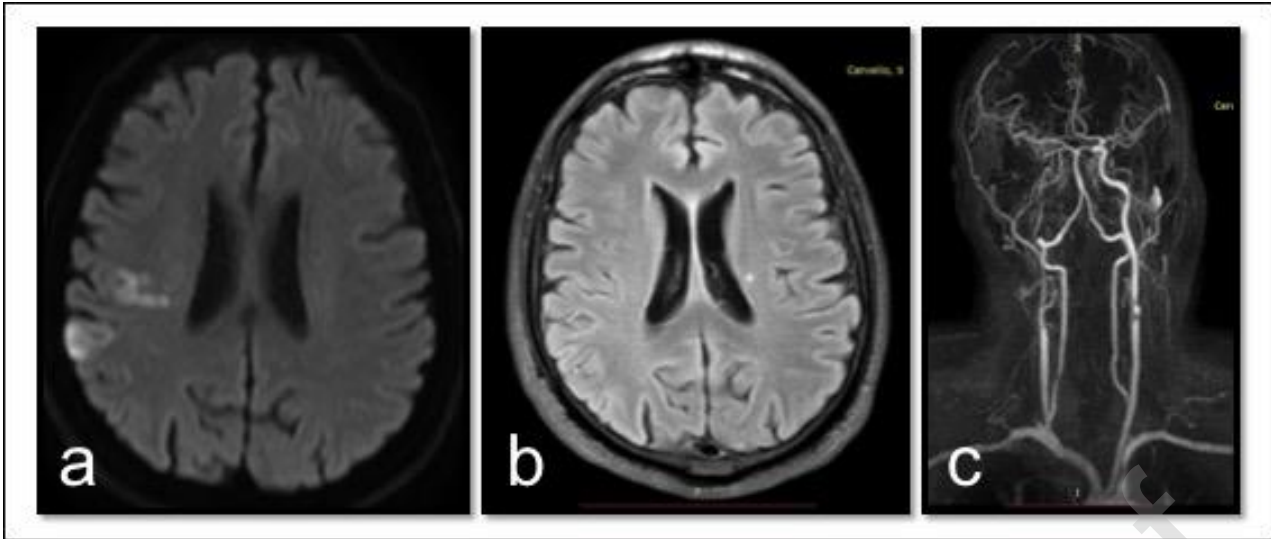


Figure 1: case 1 a) DWI-MRI b) FLAIR-MRI c) MRA

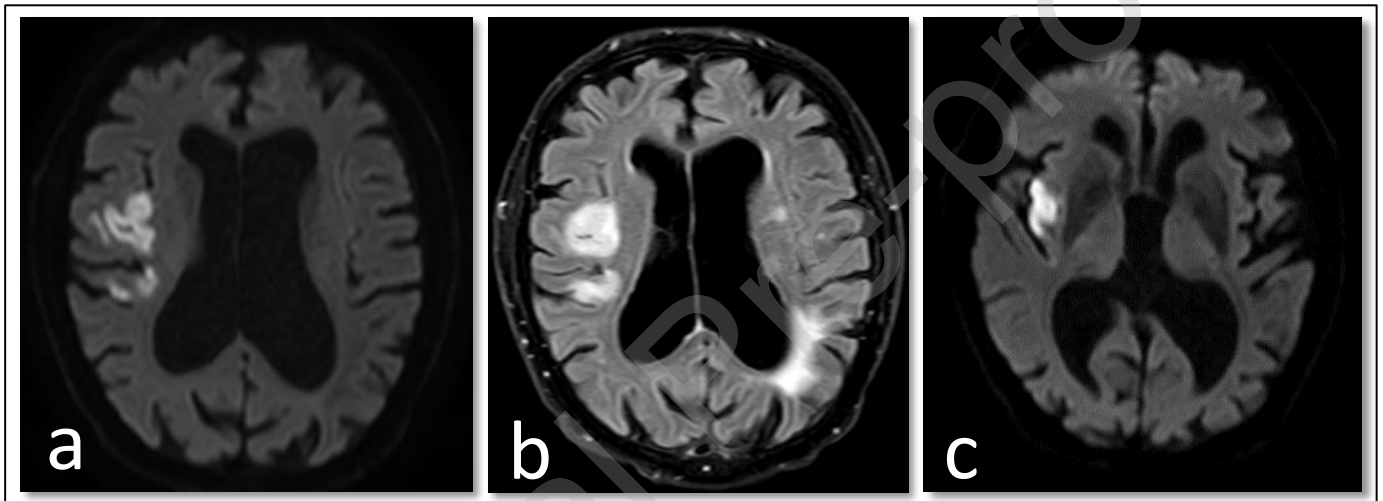


Figure 2: case 2 a) DWI-MRI b) FLAIR-MRI c) Lentiform nucleus DWI-MRI

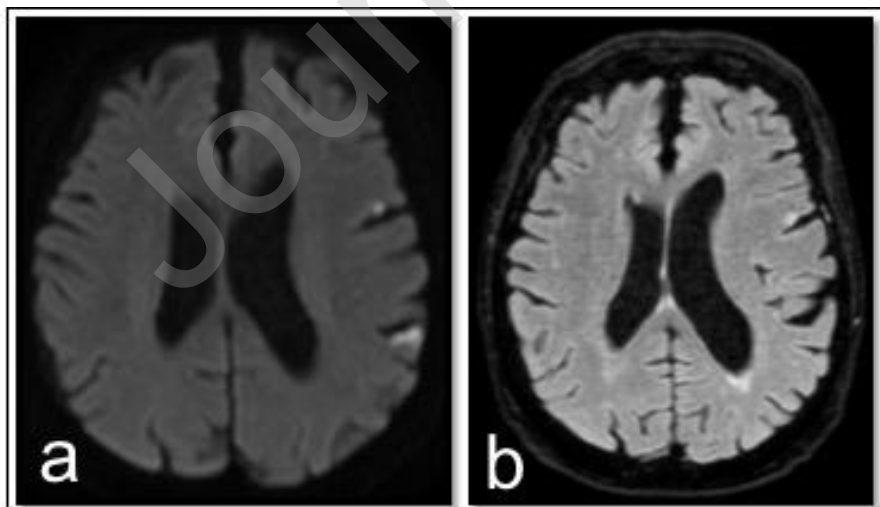


Figure 3: case 3 a) DWI-MRI b) FLAIR-MRI

Journal Pre-proof