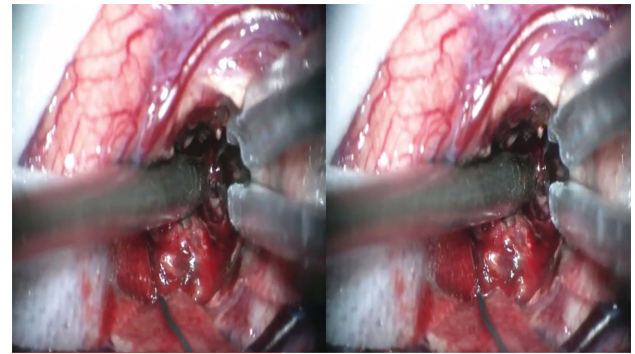


Localization and Microsurgical Resection of Left Postcentral Gyrus Spetzler-Martin Grade 3 Arteriovenous Malformation by Intraoperative Neuronavigation and Tracing of Subcortical Draining Vein: 3-Dimensional Operative Video

Qazi Zeeshan, MCh, Juan P. Carrasco Hernandez, MD, Laligam N. Sekhar, MD

Department of Neurosurgery, University of Washington, Seattle, Washington

Correspondence: Laligam N. Sekhar, MD, Department of Neurosurgery, Harborview Medical Center, University of Washington, 325 Ninth Ave, Box 359924, Seattle, WA 98104, USA. Email: lsekhar@uw.edu



Watch now at <https://academic.oup.com/ons/advance-article-abstract/doi/10.1093/ons/onz383>

This 42-yr-old man presented with a history of sudden right-sided facial and right arm weakness and dysarthria. Head computed tomography showed a left frontal-parietal blood clot. An intra-arterial digital subtraction angiography demonstrated a left subcortical postcentral, Spetzler-Martin Grade 3 arteriovenous malformation (AVM) with a diffuse nidus, measuring 2.1×1.5 cm, supplied by branches of the left MCA, and draining into a cortical vein and a deep vein, which was going toward the ventricle. Preoperative embolization was not possible.

The patient underwent left frontal-parietal craniotomy with intraoperative motor and sensory mapping. No arterialized veins were visible on the cortical surface. Neuronavigation localized the AVM in the subcortical postcentral gyrus. Through an incision in the postcentral sulcus, microdissection led to a yellowish gliotic plane. The large cortical vein was in the gliotic area and traced to the AVM. Circumferential microdissection was performed around the AVM. It had a very diffuse nidus; the arterial feeders

were cauterized and divided, and the superior superficial and inferior deep draining veins were finally occluded, and AVM was removed.

Postoperative angiogram showed total removal of the AVM. At discharge, his right arm weakness had improved (power 5/5), and facial weakness and dysarthria were improving (modified Rankin Scale (mRS) 2). At 1-yr follow-up, facial weakness and dysarthria had improved considerably, and patient returned to work (mRS 1).

This video shows microsurgical resection of an AVM by neuronavigation and tracing of the subcortical draining vein. The technique of cauterizing the perforating arteries after temporary clipping with flow arrest is shown in the video.

Informed consent was obtained from the patient prior to the surgery that included videotaping of the procedure and its distribution for educational purposes. All relevant patient identifiers have also been removed from the video and accompanying radiology slides.

Operative Neurosurgery 0:1–2, 2019

DOI:10.1093/ons/onz383

Received, June 14, 2019. Accepted, October 7, 2019.

Disclosures

The authors have no personal, financial, or institutional interest in any of the drugs, materials, or devices described in this article.

COMMENTS

The authors present a case of a ruptured, eloquent Spetzler-Martin Grade 3 (S1E1V1) arteriovenous malformation (AVM) treated with

surgical resection and an excellent clinical outcome. The technical nuances described include circumferential nidus dissection, temporary occlusion of feeding arterioles for more effective coagulation, dissection within the appropriate gliotic plane, and minimal manipulation of adjacent eloquent parenchyma. These are useful pearls for current and aspiring cerebrovascular surgeons, particularly with a diminishing exposure to open AVM microsurgery at most neurosurgical centers. The work is original, and addresses ultimately a very relevant, important question; should we be more aggressive with eloquent AVMs in general, and those in sensory cortex in particular, perhaps even in the unruptured setting? There is existing clinical data supporting the utility of definitive treatment (i.e. surgery or radiation) for unruptured, ARUBA (A Randomized trial of Unruptured Brain Arteriovenous malformations)-eligible patients,¹ including SM grade 3 AVMs,² but particularly for microsurgical resection in low grade (i.e. SM grades 1 and 2) AVMs.³ Additionally, there are clinical series demonstrating safety and efficacy of radiosurgery for motor and sensory AVMs (ruptured and unruptured),⁴ and microsurgery in motor-eloquent territory.⁵ Future studies might aim to (1) separate unruptured AVMs from ruptured ones, separate eloquent AVMs into specific-eloquent networks (i.e. speech, motor, sensory, vision, etc.), (2) clearly define pre and post-operative neurological, functional, and neuropsychological status, and (3) investigate AVMs with advanced neuroimaging both pre- and postoperatively.

Isaac Josh Abecassis
Seattle, Washington

-
1. Rutledge WC, Abela AA, Nelson J, et al. Treatment and outcomes of ARUBA-eligible patients with unruptured brain arteriovenous malformations at a single institution. *Neurosurg Focus*. 2014;37(3):E8.

2. Abecassis IJ, Nerva JD, Feroze A, et al. Multimodality management of Spetzler-Martin grade 3 brain arteriovenous malformations with subgroup analysis. *World Neurosurg*. 2017;102:263-274.
3. Nerva JD, Mantovani A, Barber J, et al. Treatment outcomes of unruptured arteriovenous malformations with a subgroup analysis of ARUBA (A Randomized Trial of Unruptured Brain Arteriovenous Malformations)-eligible patients. *Neurosurgery*. 2015;76(5):563-570.
4. Ding D, Yen CP, Xu Z, et al. Radiosurgery for primary motor and sensory cortex arteriovenous malformations: outcomes and the effect of eloquent location. *Neurosurgery*. 2013;73(5):816-824.
5. Lepski G, Honegger J, Liebsch M, et al. Safe resection of arteriovenous malformations in eloquent motor areas aided by functional imaging and intraoperative monitoring. *Neurosurgery*. 2012;70(2):276-288.

The authors describe the microsurgical resection of a Spetzler-Martin grade 3, Lawton grade 7 AVM located in the subcortical postcentral gyrus. The authors described the various localization tools utilized in AVM surgery and demonstrated multiple technical nuances in AVM resection achieving an excellent result. The value of this video is in its validation of the ability to achieve excellent outcome with microsurgical resection even in Lawton grade 7 AVMs. In the current era of cerebrovascular surgery with diminishing indications for microsurgical treatment of AVMs, it is imperative to impress the success that can be achieved from mastering the operative technicalities as those exhibited in this video.

Theresa A. Elder
Joseph G. Adel
Saginaw, Michigan