

Case Report

Bilateral Limb-Shaking Transient Ischemic Attacks

Brian Behdad Miremadi, MD,* An Tran, MD,† Lara C. Wadi, MD,‡
Shuichi Suzuki, MD,‡§ and Mark J. Fisher, MD,‡¶

Limb shaking is a rare manifestation of transient ischemic attacks (TIAs) associated with carotid occlusion, mostly unilateral events. We describe the case of a 69 year-old man who presented with repeated episodes of irregular jerking movements in the bilateral upper and lower extremities, precipitated by standing up. Cerebral angiograms revealed occlusion of both internal carotid arteries, and the patient's symptoms responded to targeted blood pressure management. Physicians should be mindful of bilateral limb-shaking TIAs when presented with bilateral paroxysmal events that can mimic seizures or orthostatic hyperkinesia.

Key Words: Transient ischemic attack—internal carotid artery—carotid stenosis—cerebral angiography—blood pressure
Published by Elsevier Inc.

Introduction

Limb shaking is a rare feature of transient ischemic attacks (TIAs), with transient involuntary movements due to carotid occlusive disease.¹ Reported episodes of limb-shaking TIAs have been mostly unilateral events.^{2,3} Here we describe a case of bilateral limb-shaking TIA, occurring in a patient with bilateral carotid occlusion.

Case Report

A 69 year-old white man with coronary artery disease, atrial fibrillation/flutter, sick sinus syndrome, hypertension, and hyperlipidemia, presented to the emergency

department with a 2-year history of progressive gait difficulty and falls. He experienced episodes of bilateral leg shaking and weakness precipitated by standing after prolonged sitting. These were followed by transient disorientation without loss of consciousness. There were no associated prodromal symptoms, incontinence, tongue biting, or history of seizures. Systolic blood pressure was as low as 93 mmHg (estimated mean arterial pressure 69 mmHg), and antithrombotic medications included aspirin, warfarin, and rivaroxaban. Neurological examination in the supine position was normal. Upon standing, the patient had repeated irregular high amplitude jerking movements, more pronounced in the bilateral lower extremities but also affecting upper extremities and trunk. He had transient confusion, but there was no seizure activity on EEG. Brain MRI showed loss of bilateral intracranial internal carotid artery (ICA) flow voids. Acute multifocal punctate ischemic lesions involving the superior frontal gyri and left frontal subcortical white matter were also seen (Fig 1). CT angiography demonstrated occlusion of the left ICA, with right ICA diminutive from cervical to cavernous segments and possible occlusion at the cavernous segment. Catheter arteriography confirmed bilateral ICA occlusion at the level of the bifurcation on the left, and at the cavernous segment on the right. Both vertebral arteries and the basilar were unremarkable, and there were robust collaterals from the posterior circulation via the posterior communicating arteries (Fig 1). Limb

From the *Department of Neurology, Harbor-UCLA Medical Center, Torrance, California; †Department of Neurology, VA Long Beach Healthcare System, Long Beach, California; ‡Department of Neurology, University of California Irvine, California; §Department of Neurosurgery, University of California Irvine, California; and ¶Department of Pathology & Laboratory Medicine, University of California Irvine, California.

Received June 14, 2019; revision received November 18, 2019; accepted November 24, 2019.

Grant Support: None.

Address correspondence to Mark Fisher, MD, UC Irvine Medical Center, 101 The City Drive South, Shanbrom Hall (Building 55), Room 121, Orange, CA 92868. E-mail: mfisher@uci.edu.

1052-3057/\$ - see front matter

Published by Elsevier Inc.

<https://doi.org/10.1016/j.jstrokecerebrovasdis.2019.104577>

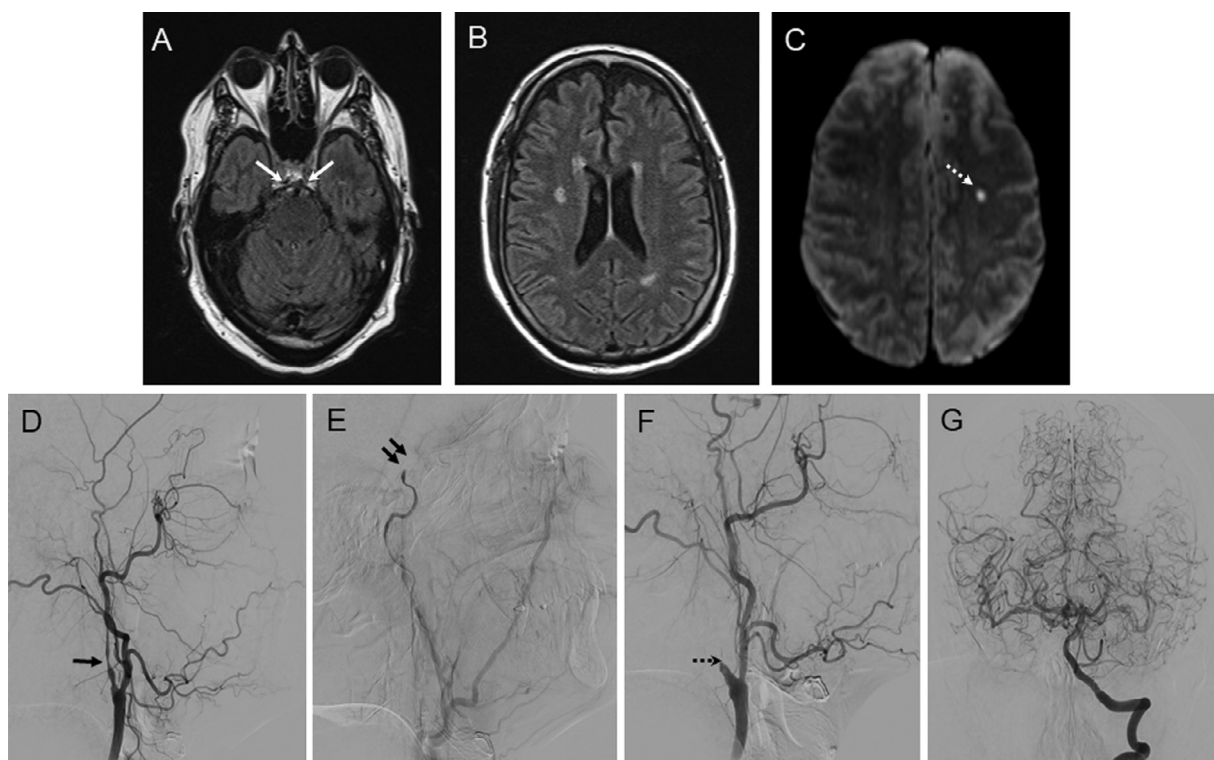


Figure 1. Brain MR images and cerebral angiographic findings of the patient with bilateral limb-shaking TIAs. A. FLAIR image of the brain demonstrates disappearance of flow void signal of the bilateral intracranial ICAs (arrows). B. FLAIR image also shows small high signal intensity regions in bilateral corona radiata, including likely chronic ischemic changes in the watershed area. C. Diffusion weighted imaging (DWI) reveals punctate ischemic lesion (dotted arrow) involving the frontal subcortical white matter. D. Right ICA injection early arterial phase shows trivial flow into the cervical segment (arrow). There is atherosclerotic wall irregularity and calcification at the bifurcation. E. In the late capillary phase, the right ICA is completely occluded at the cavernous segment (double arrow). There is no reconstitution of the distal ICA from the right ECA (external carotid artery) branches. F. Left ICA injection shows complete occlusion of the left ICA at the cervical bifurcation (dotted arrow). G. Collaterals from the posterior circulation to the bilateral anterior circulation with intact posterior communicating arteries.

shaking completely resolved with adjustment of antihypertensive medications to maintain a target systolic blood pressure of at least 120 mmHg, and the patient remained on aspirin and warfarin.

Discussion

Limb-shaking TIA was described by C. Miller Fisher and is associated with unilateral or bilateral carotid occlusive disease.¹⁻⁴ This entity should be differentiated from seizures and from orthostatic hyperkinesia; the latter consists of orthostatic myoclonus or primary orthostatic tremor, which manifest as involuntary leg movements (shaking, trembling, or jerking) while standing.^{5,6} Limb-shaking TIA should also be distinguished from the clonic limb movements occasionally observed with basilar artery occlusion.⁷; note that the DWI findings in our patient indicated anterior circulation ischemia. The presence of bilateral carotid occlusions and the temporal relationship between maneuvers that elicited relative brain hypoperfusion (ie, standing up) and jerking movements indicated a diagnosis of bilateral limb-shaking TIAs in our patient. The involuntary hyperkinetic movements seen in limb-shaking TIA are likely due to hemodynamic impairment

and transient cerebral hypoperfusion.⁸ Treatment to prevent more extensive brain ischemia may include adjustment of fluid intake, careful blood pressure management, and revascularization procedures.^{9,10} In this patient, aggressive blood pressure lowering due to coronary artery disease likely precipitated the symptoms; presence of bilateral carotid artery occlusions precluded recanalization procedures, and symptoms resolved with adjustment of hypertension treatment.

Conflict of Interest

The authors have no conflicts of interest to disclose.

References

1. Fisher CM. Concerning recurrent transient cerebral ischemic attacks. *Can Med Assoc J* 1962;86:1091-1099.
2. Javaid A, Alfishawy M. Internal carotid artery stenosis presenting with limb shaking TIA. *Case Rep Neurol Med* 2016;2016:3656859.
3. Schulz UG, Rothwell PM. Transient ischaemic attacks mimicking focal motor seizures. *Postgrad Med J* 2002;78:246-247.
4. Khan S, Chang E, Saniuk G, et al. Bilateral asymmetrical asterixis as limb-shaking transient ischemic attack in

- bilateral carotid stenosis. *J Stroke Cerebrovasc Dis* 2015;24:e29-e30.
5. Glass GA, Ahlskog JE, Matsumoto JY. Orthostatic myoclonus: a contributor to gait decline in selected elderly. *Neurology* 2007;68:1826-1830.
 6. van Gerpen JA. A retrospective study of the clinical and electrophysiological characteristics of 32 patients with orthostatic myoclonus. *Parkinsonism Relat Disord* 2014;20:889-893.
 7. Ropper AH. 'Convulsions' in basilar artery occlusion. *Neurology* 1988;38:1500-1501.
 8. Baumgartner RW, Baumgartner I. Vasomotor reactivity is exhausted in transient ischaemic attacks with limb shaking. *J Neurol Neurosurg Psychiatry* 1998;65:561-564.
 9. Leira EC, Ajax T, Adams Jr. HP. Limb-shaking carotid transient ischemic attacks successfully treated with modification of the antihypertensive regimen. *Arch Neurol* 1997;54:904-905.
 10. Carolei A, Modesti PA. Limb-shaking TIA: on the borders of evidence-based medicine. *Intern Emerg Med* 2017;12:675-677.