

Journal Pre-proof

Transient cerebral vasospasm after carotid artery stenting: A case report and literature review

Masashi Kuwabara, MD, Toshinori Nakahara, MD, Takafumi Mitsuhara, MD, Koji Shimonaga, MD, Masahiro Hosogai, MD, Kaoru Kurisu, MD, Shigeyuki Sakamoto, MD

PII: S1878-8750(19)33001-3

DOI: <https://doi.org/10.1016/j.wneu.2019.11.151>

Reference: WNEU 13820

To appear in: *World Neurosurgery*

Received Date: 25 September 2019

Accepted Date: 25 November 2019

Please cite this article as: Kuwabara M, Nakahara T, Mitsuhara T, Shimonaga K, Hosogai M, Kurisu K, Sakamoto S, Transient cerebral vasospasm after carotid artery stenting: A case report and literature review, *World Neurosurgery* (2020), doi: <https://doi.org/10.1016/j.wneu.2019.11.151>.

This is a PDF file of an article that has undergone enhancements after acceptance, such as the addition of a cover page and metadata, and formatting for readability, but it is not yet the definitive version of record. This version will undergo additional copyediting, typesetting and review before it is published in its final form, but we are providing this version to give early visibility of the article. Please note that, during the production process, errors may be discovered which could affect the content, and all legal disclaimers that apply to the journal pertain.

© 2019 Elsevier Inc. All rights reserved.



Transient cerebral vasospasm after carotid artery stenting: A case report and literature review

Masashi Kuwabara, MD¹, Toshinori Nakahara, MD², Takafumi Mitsuhara, MD¹, Koji Shimonaga, MD², Masahiro Hosogai, MD², Kaoru Kurisu, MD¹, and Shigeyuki Sakamoto, MD¹

¹ Department of Neurosurgery, Graduate School of Biomedical and Health Sciences, Hiroshima University, 1-2-3 Kasumi, Minami-ku, Hiroshima-shi, Hiroshima 734-8551, Japan

² Department of Neurosurgery, Hiroshima City Asa Hospital, 2-1-1 Kabe-minami, Asakita-ku, Hiroshima-shi, Hiroshima 731-0293, Japan

Corresponding author:

Masashi Kuwabara

Department of Neurosurgery, Graduate School of Biomedical and Health Sciences,

Hiroshima University, 1-2-3 Kasumi, Minami-ku, Hiroshima-shi, Hiroshima 734-8551,

Japan

Tel: +81-08-2257-5227; Fax: +81-08-2257-5229; Email: m214028@gmail.com

Abstract:

Background: Cerebral embolism after carotid artery stenting (CAS) is a well-known complication, but cerebral ischemia due to cerebral vasospasm after CAS is rare and has seldom been reported. We describe a patient with transient ischemic complications due to reversible cerebral vasospasm of the middle cerebral artery (MCA) after CAS.

Clinical description: A 74-year-old man presented with right hemiparesis by acutely scattered brain infarction in the left cerebral hemisphere. Magnetic resonance angiography (MRA) showed severe stenosis of the left cervical internal carotid artery origin. CAS under a distal filter protection was performed without any intraprocedural complications, but 12 hours later, the patient had aphasia and Gerstmann syndrome.

Urgent magnetic resonance image revealed no evidence of an intracranial hemorrhage or new cerebral infarction. However, MRA showed diffuse vasospasm of the left MCA.

His symptoms and imaging findings improved gradually by conservative treatment. The

patient was discharged without new neurological deficits and recurrent attack in 3 weeks after CAS.

Conclusion: In a patient with delayed neurological symptoms after CAS, the possibility of cerebral vasospasm should be kept in mind in order to select appropriate treatment.

Key Words: carotid artery stenting, cerebral vasospasm, ischemic complication

Introduction:

Various complications after carotid artery stenting (CAS) have been reported. These include internal carotid artery (ICA) complications such as intrastent thrombus formation, restenosis, and vascular dissection; neurological complications such as intracranial hemorrhage, hyperperfusion syndrome, or cerebral infarction due to thrombosis or debris from a plaque; and systemic complications such as contrast-induced encephalopathy, myocardial infarction, bradycardic hypotension, and cholesterol embolism⁶⁾. However, cerebral ischemia due to delayed cerebral vasospasm as a delayed post-CAS complication is rare and has seldom been reported^{3,4)}.

We describe a case with reversible cerebral vasospasm of the ipsilateral middle cerebral artery (MCA) after CAS for symptomatic left cervical ICA stenosis, and review literatures of cerebral vasospasm after CAS.

Case Report:

A 74-year-old man presenting with difficulty moving his right arm was referred to our hospital. Magnetic resonance image (MRI) showed an acute cerebral infarction in the left cerebral hemisphere (Fig. 1A). Head and neck magnetic resonance angiography (MRA) showed left cervical ICA stenosis (Figs. 1B and C). Carotid ultrasound showed an echolucent plaque with a maximum blood flow velocity of 257 cm/sec during systole. Neck CT angiography showed severe stenosis with a little calcification in left cervical ICA. Black-blood T1WI MRI showed high intensity signal in plaque. Single photon emission computed tomography (SPECT) at rest showed significantly reduced cerebral blood flow (CBF) in the left parietal lobe (Fig. 1D).

The patient received clopidogrel (75mg/day) and aspirin (100mg/day) orally, and CAS was proposed to prevent recurrent attacks at a later date. CAS procedure was performed using a distal filter protection device. After predilation, stent (Precise PRO RX stent system: Cordis Endovascular, Johnson & Johnson, Miami, FL, USA) was deployed. Postdilation was performed with a 5.5 × 40 mm PTA balloon catheter. Angiogram revealed excellent dilatation (Figs. 2A and B). During and after CAS, no

bradycardia, hypotension, seizures, or neurological symptoms developed. Post-CAS angiography also showed no intracranial abnormalities. However, 12 hours after CAS, the patient developed aphasia and Gerstmann syndrome. Urgent cranial MRI did not show abnormal findings such as acute cerebral infarction, but MRA showed poor visualization of the left distal MCA (Fig. 3A). Neck CT angiography showed a good patency in carotid stent, but cranial CT angiography revealed diffuse stenosis of the distal left MCA like MRA (Figs. 3B). These imaging findings suggested that the cause of the neurological symptoms was ischemia of the left cerebral hemisphere due to vasospasm of the left distal MCA.

Intravenous edaravone and a continuous intravenous infusion of milrinone and dopamine were immediately started. The patient's symptoms began to improve from day 2 after CAS. Cranial MRA and contrast CTA showed improved visualization of the distal left MCA (Figs. 3C and D). The symptoms resolved completely day 7 after CAS, and the patient was discharged without new neurological deficits at 3 weeks after CAS.

Discussion

In post-CAS complications, attention must certainly be paid to possible cerebral embolism from emboli that travel distally during CAS, but about 40% to 70% of ischemic complications are reported to occur a few hours after, rather than during, CAS. This highlights the need to also be alert for delayed ischemic complications^{3,4}. These include cerebral ischemia due to delayed cerebral vasospasm which is rare and has seldom been reported.

From our extensive review of the literature, delayed cerebral vasospasm has been reported in only 11 cases, including the present patient, after CAS or a carotid endarterectomy (CEA) (Table 1). This includes 6 cases after CEA and 5 cases after CAS, including 6 men and 5 women ranging in age from 49 to 74 years⁷⁻¹⁵. Many cases present predominantly with neurological symptoms in the territory supplied by the blood vessels affected by vasospasm. These reports include vasospasm only of the MCA, as in the present patient, whereas others include vasospasm of the anterior cerebral artery (ACA) and posterior cerebral artery (PCA). The time of post-procedure

symptom onset has ranged from 12 hours, as in the present patient, to a maximum of 30 days. Seven of the 11 patients had a cerebral infarction. Treatment varied, but most often included a calcium channel blocker. Seven of the 11 patients had complete recovery and a relatively good clinical course.

The mechanism of delayed cerebral vasospasm is not well understood. However, several possible mechanisms can be considered based on the literature. The first mechanism is that delayed scattering of small debris or thrombi from a plaque where a stent has been placed can cause vasospasm due to mechanical irritation. Of 111 patients who underwent CAS, Qureshi et al. reported 14 periprocedural ischemic complications, including 4 during the procedure and 10 within 48 hours after the procedure¹⁻⁴). Based on these findings, Rosenbloom et al. suggested that scattering of small debris and thrombi from a plaque even after stent placement can cause mechanical irritation and lead to vasospasm¹³). The second mechanism is a reversible cerebral vasoconstriction syndrome (RCVS). RCVS comprises a group of disorders, and its onset is characterized by a severe headache that is also known as a thunderclap headache¹⁶⁻¹⁹). Imaging

studies show diffuse cerebral vasospasm of a cerebral blood vessel, and clinically, neurological symptoms may occur in the territory supplied by the blood vessels affected by vasospasm. RCVS can occur with pregnancy, certain drugs, hypercalcemia, head trauma, carotid artery dissection, CEA, and CAS^{13,14}). The third mechanism involves chronically insufficient CBF associated with disruption in autoregulation of the cerebral vasculature. A post-procedure increase in CBF might then trigger the onset of vasospasm. The literature has described chronically insufficient CBF associated with disruption in autoregulation of cerebral vasculature in patients with severe ICA stenosis^{13,15}). When CEA or CAS is performed in such patients, transient post-procedure hyperperfusion has occasionally been reported to induce severe vasospasm in sensitive cerebral blood vessels^{7,8,13-15}).

In our case, MRA and CTA showed an acute course of cerebral vasospasm of the ipsilateral MCA with reversible changes in a very short time. The patient had an acute course without severe headaches that was not typical for RCVS. Pre-procedure SPECT at rest did show significantly reduced blood flow in the left parietal lobe. We speculated

that mechanism of transient cerebral vasospasm in our case was chronically insufficient CBF associated with disruption in autoregulation of the cerebral vasculature because pre-procedure SPECT at rest did show significantly reduced blood flow in the left parietal lobe.

Conclusion

In a patient with delayed neurological symptoms after CAS, the possibility of cerebral vasospasm should be kept in mind in order to select appropriate treatment.

Ethical approval

All procedures performed in studies involving human participants were in accordance with the ethical standards of the institutional and/or national research committee and with the 1964 Helsinki declaration and its later amendments or comparable ethical standards.

Informed consent

This article does not contain any studies with human participants performed by any of the authors.

Journal Pre-proof

References

1. Brott TG, Hobson RW 2nd, Howard G (2010) Stenting versus endarterectomy for treatment of carotid-artery stenosis. *N Engl J Med* 363: 11-23
2. Yadav JS, Wholey MH, Kuntz RE (2004) Protected carotid artery stenting versus endarterectomy in high-risk patients. *N Eng J Med* 351: 1493-1501
3. Coutts SB, Hill MD, Hu WY (2003) Hyperperfusion syndrome: toward a stricter definition. *Neurosurgery* 53: 1053-1058
4. Qureshi AI, Luft AR, Janardhan V (2000) Identification of patients at risk for periprocedural neurological deficits associated with carotid angioplasty and stenting. *Stroke* 31: 376-382
5. Ogasawara K, Sakai N, Kuroiwa T (2007) Intracranial hemorrhage associated with cerebral hyperperfusion syndrome following carotid endarterectomy and carotid artery stenting: retrospective review of 4494 patients. *J Neurosurg* 107: 1130-1136

6. Bates ER, Babb JD, Casey DE Jr (2007) ACCF/SCAI/SVMB/SIR/ASTIN 2007 clinical expert consensus document on carotid stenting: a report of the American College of Cardiology Foundation Task Force on Clinical Expert Consensus Documents. *J Am Coll Cardiol* 49: 126-170
7. Aghaebrahim A, Jadhav AP, Saeed Y, Totoraitis R, Jankowitz BT, Jovin TG, Molyneaux BJ (2014) Reversible cerebral vasoconstriction syndrome following carotid stenting. *Neurology* 83: 570-571
8. Arai M, Kuwayama N, Koide K, Takazawa H, Harada J, Koh M (2013) Transient right hemisphere hypoperfusion following right carotid artery stenting: a case report: *JNET* 7: 119-126
9. Brick JF, Dunker RO, Gutierrez AR (1990) Cerebral vasoconstriction as a complication of carotid endarterectomy. *J Neurosurg* 73: 151-153
10. Dagher HN, Shum MK, Campellone JV (2005) Delayed intracranial vasospasm following carotid endarterectomy. *Cerebrovasc Dis* 20: 205-206

11. Lopez-Valdes E, Chang HM, Pessin MS, Caplan LR (1997) Cerebral vasoconstriction after carotid surgery. *Neurology* 49: 303-304
12. Ohashi T, Okada H, Haraoka R, Oga Y, Nakamura T, Miki T (2012) Intracranial vasospasm following carotid artery stenting. *JNET* 6: 353
13. Rosenbloom MH, Singhal AB (2007) CT angiography and diffusion-perfusion MR imaging in a patient with ipsilateral reversible cerebral vasoconstriction after carotid endarterectomy. *AJNR Am J Neuroradiol* 28: 920-922
14. Soltanolkotabi M, Ansari S, Patel B, Shaibani A, Hurley M (2012) Reversible cerebral vasoconstriction syndrome following carotid artery stenting. *J Neurointervent Surg* 4: 49-50
15. Wu TY, Frith RW, Barber PA (2011) Reversible cerebral vasoconstriction following carotid endarterectomy. *J Clin Neurosci* 18: 1725-1728,

16. Bartynski WS, Boardman JF (2008) Catheter angiography, MR angiography, and MR perfusion in posterior reversible encephalopathy syndrome. *AJNR Am J Neuroradiol* 29: 447-455
17. Calabrese LH, Dodick DW, Schwedt TJ (2007) Narrative review: reversible cerebral vasoconstriction syndromes. *Ann Intern Med* 146: 34-44
18. Ducros A, Boukobza M, Porcher R (2007) The clinical and radiological spectrum of reversible cerebral vasoconstriction syndrome. A prospective series of 67 patients. *Brain* 130: 3091-3101
19. Fang HY, Kuo YL, Wu CJ (2009) Transient contrast encephalopathy after carotid artery stenting mimicking diffuse subarachnoid hemorrhage: a case report. *Catheter Cardiovasc Interv* 73: 123-126

Figure legends

Fig. 1

- A. Diffusion-weighted imaging showed scattered high-intensity in the left cerebral hemisphere.
- B. Cranial MRA showed a decrease in intensity on the left large vessels compared to the right.
- C. Cervical MRA showed severe stenosis at the origin of the left cervical internal carotid artery (arrow).
- D. SPECT at rest showed significantly reduced cerebral blood flow in the left parietal lobe (arrow).

Fig. 2

- A. Preoperative lateral view of digital subtraction angiogram showed severe stenosis in the left ICA.

- B. Postoperative lateral view of digital subtraction angiogram showed a dilated stenotic lesion after carotid artery stenting.

Fig. 3

- A. Post-CAS (12 h) MRA showed diffuse poor visualization of the distal left MCA.
- B. Post-CAS (12 h) contrast CTA showed diffuse poor visualization of the distal left MCA.
- C. MRA 2 days after starting treatment showed improved visualization of the distal left MCA.
- D. Contrast CTA day 2 after CAS showed improved visualization of the distal left MCA.

Table 1. Cases of patients with cerebral vasoconstriction following carotid stenting (CAS) or carotid endarterectomy (CEA)

Case	Author/ year	Age (y)/ sex	Surgery	Side of surgery	Neurologic symptoms	Vasoconstriction	Days after surgery	Acute infarction	Treatment	Outcome
1	Brick JF, 1990 ¹⁾	57/M	CEA	R	Confusion, paranoia	ACA, MCA	8	No	None	CR
2	Lopez V, 1997 ²⁾	50/M	CEA	R	Numbness	ACA, MCA	7	Yes	Corticosteroid	—
3	Lopez V, 1997 ²⁾	54/F	CEA	R	Hemianopia, nausea	MCA, PCA	8	Yes	Verapamil	MD
4	Dagher HN, 2005 ³⁾	62/M	CEA	L	Aphasia	ACA, MCA	5	No	Diltiazem	CR
5	Rosenblom MH, 2007 ⁴⁾	54/F	CEA	L	Aphasia, numbness	ACA, MCA	2	Yes	Nimodipine, magnesium	CR
6	Teddy YW, 2011 ⁵⁾	58/F	CEA	R	Weakness, visual blurring	ACA, MCA, PCA	3	Yes	Nimodipine	CR
7	Ohashi, 2012 ⁶⁾	69/M	CAS	L	Aphasia, weakness	MCA	1	Yes	Fasudil HCl	—
8	Soltanolkotabi M, 2012 ⁷⁾	49/F	CAS	L	Numbness, weakness	ACA, MCA, PCA	14	Yes	Verapamil	CR
9	Arai, 2013 ⁸⁾	72/M	CAS	R	Unilateral neglect,	ACA, MCA	0.5	Yes	Argatroban, dopamine	CR
10	Aghaebrahim A, 2014 ⁹⁾	60/F	CAS	R	Headache, weakness	ACA, MCA	30	—	Verapamil	—
11	present case 2015	74/M	CAS	L	Aphasia, agnosia	MCA	0.5	No	Milrinone, dopamine	CR

M: male, F: female, CEA: carotid endarterectomy, CAS: carotid artery stenting, CR: complete recovery, MD: moderate disability,

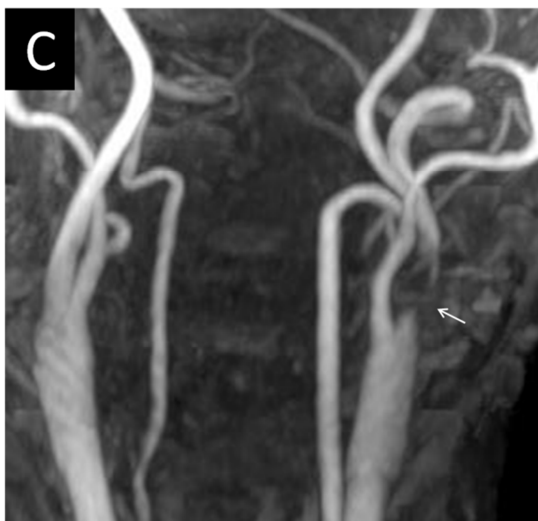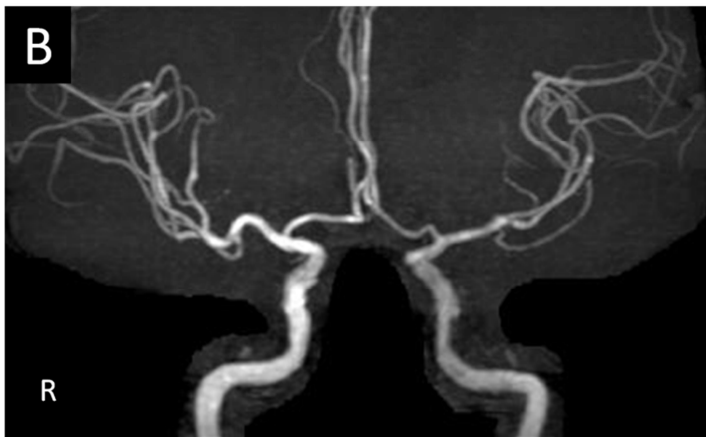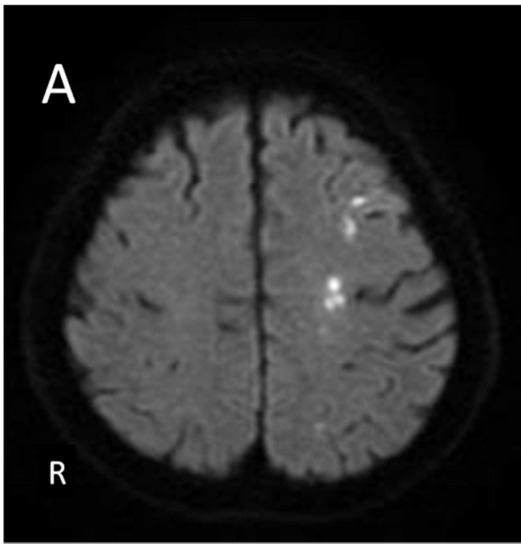
ACA: anterior cerebral artery, MCA: middle cerebral artery, PCA: posterior cerebral artery

Table.1 Cases of patients with cerebral vasoconstriction following carotid stenting (CAS) or carotid endarterectomy (CEA)

Case	Author/year	Age/sex	Surgery	Side of surgery	Neurologic symptoms	Vasoconstriction	Days after surgery	Acute infarction	Treatment	Outcome
1	Brick JF, 1990 ¹⁾	57/M	CEA	R	Confusion, paranoia	ACA, MCA	8	No	None	CR
2	Lopez V, 1997 ²⁾	50/M	CEA	R	Numbness	ACA, MCA	7	Yes	Corticosteroid	—
3	Lopez V, 1997 ²⁾	54/F	CEA	R	Hemianopia, nausea	MCA, PCA	8	Yes	Verapamil	MD
4	Dagher HN, 2005 ³⁾	62/M	CEA	L	Aphasia	ACA, MCA	5	No	Diltiazem	CR
5	Rosenbloom MH, 2007 ⁴⁾	54/F	CEA	L	Aphasia, numbness	ACA, MCA	2	Yes	Nimodipine, magnesium	CR
6	Teddy YW, 2011 ⁵⁾	58/F	CEA	R	Weakness, visual blurring	ACA, MCA, PCA	3	Yes	Nimodipine	CR
7	Ohashi, 2012 ⁶⁾	69/M	CAS	L	Aphasia, weakness	MCA	1	Yes	Fasudil hydrochlorid ^e	—
8	Soltanolkotabi M, 2012 ⁷⁾	49/F	CAS	L	Numbness, weakness	ACA, MCA, PCA	14	Yes	Verapamil	CR
9	Arai, 2013 ⁸⁾	72/M	CAS	R	Unilateral neglect,	ACA, MCA	0.5	Yes	Argatroban, dopamine	CR
10	Aghaebrahim A, 2014 ⁹⁾	60/F	CAS	R	Headache, weakness	ACA, MCA	30	—	Verapamil	—
11	present case 2018	74/M	CAS	L	Aphasia, agnosia	MCA	0.5	No	Milrinone, dopamine	CR

M : male, F : female, CEA : carotid endarterectomy, CAS : carotid artery stenting, CR : complete recovery, MD : moderate disability, ACA : anterior cerebral artery, MCA : middle cerebral artery, PCA : posterior cerebral artery.

Fig. 1



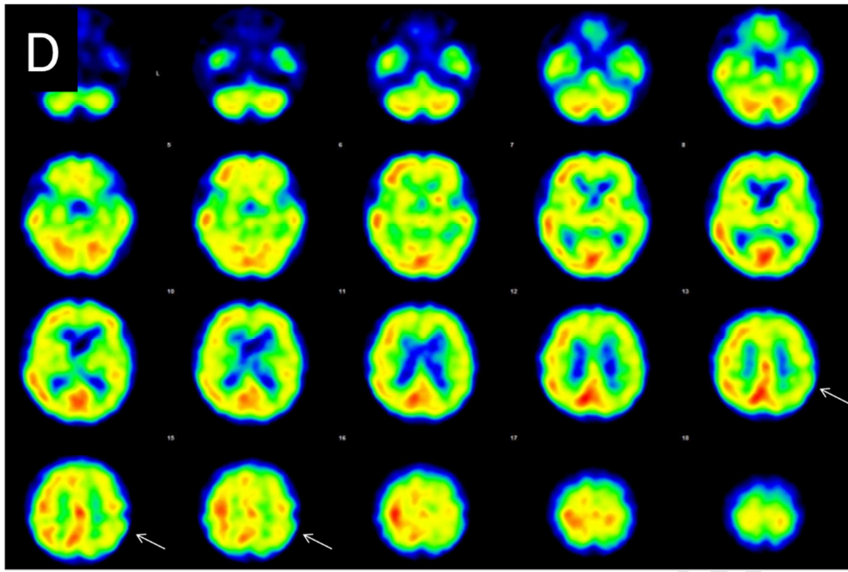
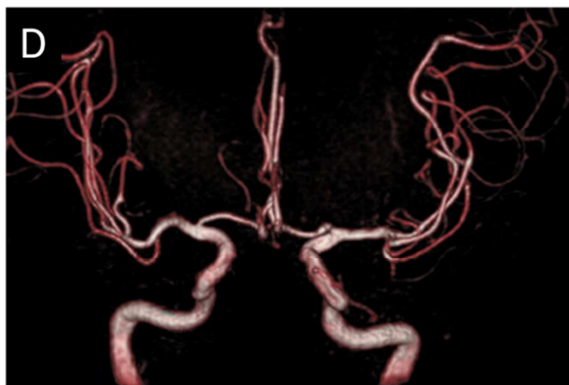
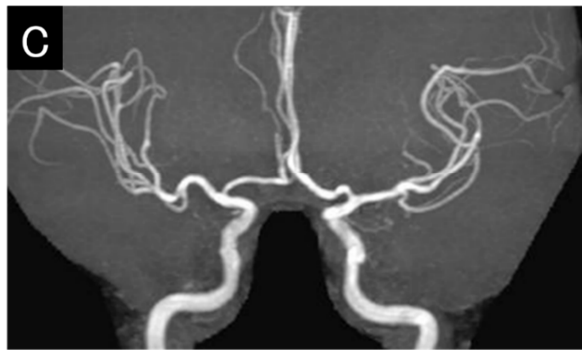
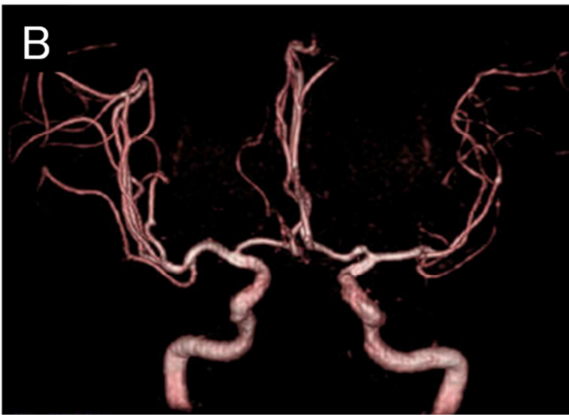
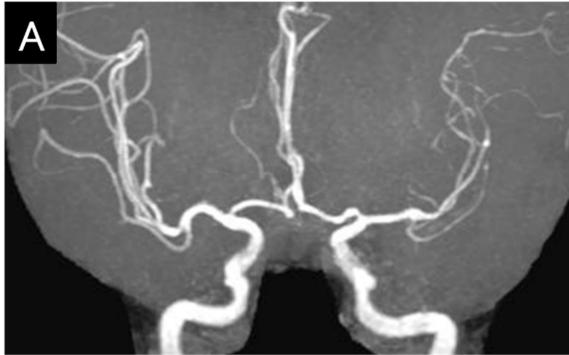


Fig. 2

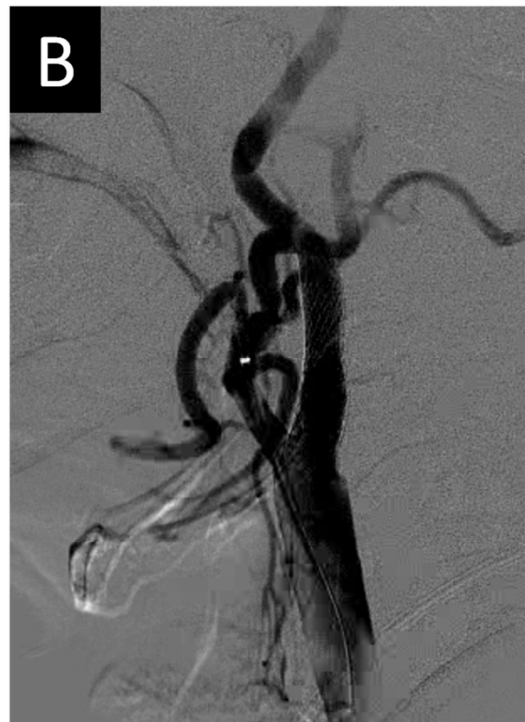
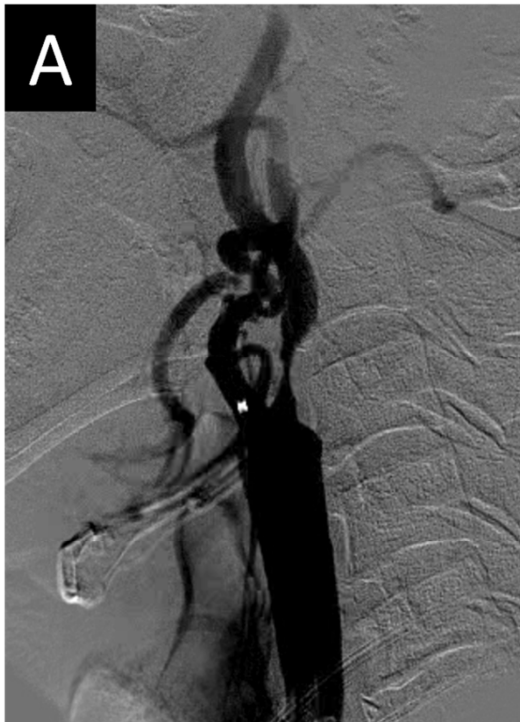
Fig. 3



Abbreviations:

- 1) CAS: Cerebral embolism after carotid artery stenting
- 2) MCA: middle cerebral artery
- 3) MRA: Magnetic resonance angiography
- 4) ICA: internal carotid artery
- 5) SPECT: Single photon emission computed tomography
- 6) CBF: cerebral blood flow
- 7) CEA: carotid endarterectomy
- 8) ACA: anterior cerebral artery
- 9) PCA: posterior cerebral artery
- 10) RCVS: reversible cerebral vasoconstriction syndrome
- 11) CTA: computed tomography angiography
- 12) M: male
- 13) F: female
- 14) CR: complete recovery

15) MD: moderate disability

Journal Pre-proof