

Acute ischemic stroke in a third trimester of pregnancy – cesarean section followed by mechanical thrombectomy

Marcin Wiącek, Rafał Kaczorowski, Antonina Oboz-Adaś, Katarzyna Kuźniar & Halina Bartosik-Psujek

To cite this article: Marcin Wiącek, Rafał Kaczorowski, Antonina Oboz-Adaś, Katarzyna Kuźniar & Halina Bartosik-Psujek (2019): Acute ischemic stroke in a third trimester of pregnancy – cesarean section followed by mechanical thrombectomy, International Journal of Neuroscience

To link to this article: <https://doi.org/10.1080/00207454.2019.1702539>



Published online: 16 Dec 2019.



Submit your article to this journal [↗](#)



View related articles [↗](#)



View Crossmark data [↗](#)

CASE REPORT



Acute ischemic stroke in a third trimester of pregnancy – cesarean section followed by mechanical thrombectomy

Marcin Wiącek^{a,b}, Rafał Kaczorowski^a, Antonina Oboz-Adaś^b, Katarzyna Kuźniar^b and Halina Bartosik-Psujek^{a,b}

^aDepartment of Neurology, Clinical Regional Hospital No. 2, Rzeszów, Poland; ^bFaculty of Medicine, University of Rzeszów, Rzeszów, Poland

ABSTRACT

Background: Acute ischemic stroke (AIS) in pregnancy, despite being a rare event, poses a serious risk for mother's and child's health. There are no strict treatment guidelines in this group of patients, with safety and efficacy of intravenous recombinant tissue-plasminogen-activator (rtPA) and mechanical thrombectomy (MT) being uncertain.

Case Presentation: We present a case of gravid 27-year-old patient with left middle cerebral artery (MCA) proximal occlusion causing AIS that was successfully treated with MT. Being in 35th gestational week, it was decided to perform caesarean section before endovascular treatment. The outcome of treatment was good, with no mother's neurological deficit and proper child development in the 5-year observation.

Conclusions: MT is probably safe and efficient treatment method in selected pregnant women. No harmful effects on further pregnancy course and parturition have been observed to date.

ARTICLE HISTORY

Received 6 September 2019
Accepted 26 November 2019

KEYWORDS

Mechanical thrombectomy; acute ischemic stroke; pregnancy; endovascular treatment

Background

Acute ischemic stroke (AIS) is one of the main causes of death and long-term disability in the developed countries [1]. AIS in women of childbearing potential is a rare event (incidence 4,3 to 8,3 per 100,000 women [2]), with the risk substantially elevated in pregnancy (34,2 per 100,000 pregnancies) [3]. It is responsible for 5% of maternal mortalities and significant morbidity [3]. While intravenous (IV) recombinant tissue-plasminogen-activator (rtPA) and mechanical thrombectomy (MT) are now approved methods of AIS treatment, no optimal therapy for pregnant women is defined. We present a case of large vessel occlusion (LVO) causing AIS in 3rd trimester of pregnancy, successfully managed with MT that followed emergent cesarean section.

Case report

A 27-year-old primigravid in 35th gestational week was admitted to the Neurology Clinic due to mild dysarthria and right brachiofacial paresis (National Institutes of Health Stroke Scale [NIHSS] 2 points). Non-contrast head CT scan revealed a hyperdense left middle

cerebral artery (MCA). Due to mild neurologic deficit reperfusion treatment was withheld. After 2 h of observation significant neurological deterioration occurred (massive dysarthria, motor aphasia, partial right-sided hemianopia and hemiparesis; NIHSS = 15). Due to sufficient gestational age, decision to perform immediate pregnancy termination by cesarean section (CS) preceding digital subtraction angiography (DSA) was made. After uneventful CS, proximal left MCA occlusion was confirmed and MT conducted. At 8 h 25 mins. after symptom onset successful recanalization was achieved (Thrombolysis in Cerebral Infarction [TICI] score 3; Figure 1). The significant early improvement after 24 h was noted (NIHSS = 7 points). Despite extensive diagnostics, the etiology of stroke was defined as cryptogenic. The woman was discharged on the 16th day after the procedure with NIHSS score 1. At 3-month follow-up no neurological deficit was noted (NIHSS = 0; modified Rankin Scale [mRS] = 0). The child, by age 5, was developed properly.

Discussion

The pregnant women constitute a very unique group of AIS patients, where safety of standard diagnostic

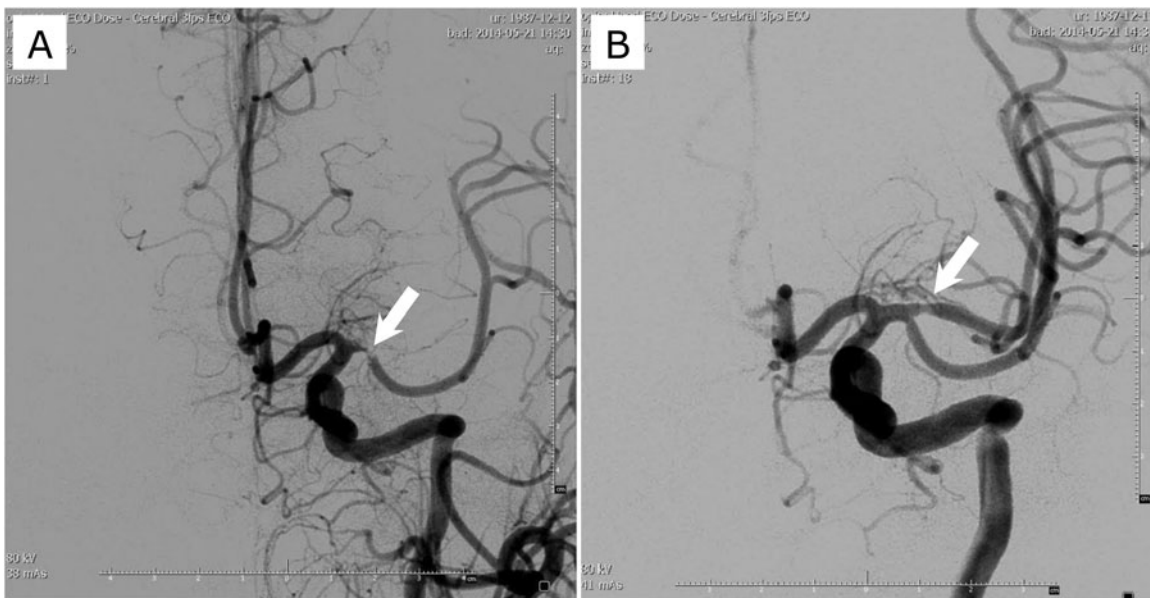


Figure 1. Digital subtraction angiography imaging showing proximal left middle cerebral artery occlusion (A) and vessel recanalization after clot removal (B).

and treatment procedures need to be carefully considered. Firstly, when selecting the neuroimaging method, foetal adverse effects should be taken into account. The non-contrast head computed tomography (CT) is related with only indirect scattered foetal radiation exposure, estimated to be <0.01 rad [4]. The radiation dose less than 5 rad has not been directly associated with the increased risk of spontaneous abortion, developmental malformations, or mental retardation and is believed to elevate the risk of childhood cancer by only a very small degree [5]. Magnetic resonance imaging (MRI) without contrast administration is thought to be safe for foetus and is preferable imaging method in pregnancy [6]. The iodine-based contrast, used in CT-angiography (CTA) and digital subtraction angiography (DSA), did not cause teratogenicity or mutagenicity in animal models [7]. Due to the hypothetical risk of neonatal hypothyroidism, which has not been confirmed in one study [8], it is recommended to avoid its usage whenever possible and to check neonatal thyroid function during first week of postpartum [9]. Gadolinium contrast agents may pose a risk of abortion or developmental abnormalities, as shown in animal studies, and should be avoided [9]. Therefore, non-contrast time-of-flight (TOF) magnetic resonance angiography (MRA) could be superior non-invasive cerebral vessel imaging in terms of safety comparing to contrast studies (CTA, MRA). In our case, non-contrast CT scan was taken, due to lack of MRI availability. Considering significant neurological deficit and hyperdense MCA sign CT-

angiography was withheld and DSA used to confirm the vessel occlusion.

MT and intravenous thrombolysis (IVT) with rtPA administration have been proven to be efficacious in selected AIS patients. However, safety of reperfusion treatment in pregnancy has not been extensively evaluated. Alteplase is a large molecule that does not cross the placenta and is not associated with teratogenicity in animal models [10]. In literature review by Sousa Gomes *et al.* 141 cases of pregnant women with serious thrombotic events treated with thrombolytic agents were identified. The major maternal bleeding, maternal death, miscarriage and preterm delivery was noted in 8, 3, 6 and 10% of cases respectively [11]. In another review 18 pregnant patients with thrombolytic therapy of AIS or venous sinus thrombosis were identified. No maternal deaths and major bleeding attributed to treatment and three foetal deaths or spontaneous abortion, probably unrelated to thrombolytic administration, were noted [12]. It appears that the added risk of IVT in pregnancy is relatively low, but has to be taken into consideration in planning of AIS management. According to recent American Heart Association/American Stroke Association (AHA/ASA) guidelines, IV rtPA administration may be considered in pregnancy when the anticipated benefits of treating moderate or severe stroke exceeds the anticipated risk of uterine bleeding [13]. The estimated absorbed dose during MT treatment is estimated to be 0.28 rad that is believed to be associated with a very low risk of adverse events [14]. The

Table 1. Case reports of acute ischemic stroke treated with mechanical thrombectomy in pregnancy.

References	Year	Method of treatment	Gestational age	Maternal outcome	Foetal outcome
Aaron et al. [15]	2015	MT	3 rd trimester	mRS = 0 after 6 months	healthy
Aaron et al. [15]	2015	MT	37 weeks	mRS = 2 after 6 months	healthy
Bhagal et al. [16]	2017	MT	24 weeks	mRS = 1 after 8 years	healthy
Bhagal et al. [16]	2017	rt-PA + MT	25 weeks	mRS = 1 after 1 day	pregnancy ongoing, ultrasound examination showed no complications
Zhu et al. [17]	2018	rt-PA + MT	9 weeks	NIHSS = 1 after 24 hours	healthy
Shah et al. [18]	2018	rt-PA + MT	9 weeks	mRS = 1 on discharge	pregnancy ongoing, ultrasound examination showed no complications
Watanabe et al. [19]	2018	rt-PA + MT	21 weeks	mRS = 1 after 6 months	healthy
Blythe et al. [20]	2019	MT	39 weeks	mRS = 0 after 6 weeks	healthy
Our case		CS + MT	35 weeks	NIHSS = 0 after 7 months	healthy

Abbreviations: MT – mechanical thrombectomy, rt-PA – recombinant tissue plasminogen activator, mRS – Pre-Stroke Modified Rankin Scale, NIHSS – National Institute of Health Stroke Scale, N/A – not available.

absorbed dose should, however, be minimized using abdominal lead shielding during procedure.

Up to date, 8 cases of AIS in pregnancy treated with MT have been published [15–20]. In 4 cases MT was preceded by IVT. All of them were successful in terms of vessel recanalization and maternal outcome (Table 1). In our case, due to sufficient gestational age, uneventful pregnancy course and lack of outlined cases of MT performed during pregnancy by the time of the event (2014), it has been decided to carry out caesarean section before MT treatment. In three published cases, with MT conducted in the 3rd trimester, no harmful effects on further pregnancy course and parturition was noted. Therefore, it appears that terminating pregnancy before MT procedure in such circumstances may not be necessary.

Conclusions

Acute ischemic stroke during pregnancy is a rare, challenging clinical problem. MT is probably safe and efficient treatment method in carefully selected cases. No harmful effects on further pregnancy course and parturition have been noted to date. There is, however, more data needed to prove safety of MT in pregnancy and define appropriate algorithms of AIS management in pregnant women.

Disclosure statement

The authors report no conflict of interest.

References

- [1] Kuklina EV, Tong X, George MG, et al. Epidemiology and prevention of stroke: a worldwide perspective. *Exp Rev Neurother.* 2012;12(2):199–208.
- [2] Nightingale AL, Farmer RD. Ischemic stroke in young women: a nested case-control study using the UK General Practice Research Database. *Stroke.* 2004; 35(7):1574–1578.
- [3] James AH, Bushnell CD, Jamison MG, et al. Incidence and risk factors for stroke in pregnancy and the puerperium. *Obstetrics Gynecol.* 2005;106:509–516.
- [4] Osei EK, Faulkner K. Fetal doses from radiological examinations. *Br J Radiol.* 1999;72(860):773–780.
- [5] Klein JP, Hsu L. Neuroimaging during pregnancy. *Semin Neurol.* 2011;31(04):361–373.
- [6] Kanal E, Barkovich AJ, Bell C, et al. ACR Blue Ribbon Panel on MR Safety. ACR guidance document for safe MR practices: 2007. *AM J Roengenol.* 2007;188(6): 1447–1474.
- [7] Nelson JA, Livingston GK, Moon RG. Mutagenic evaluation of radiographic contrast media. *Invest Radiol.* 1982;17(2):183–185.
- [8] Bona G, Zaffaroni M, Defilippi C, et al. Effects of iopamidol on neonatal thyroid function. *Eur J Radiol.* 1992;14(1):22–25.
- [9] Webb JAW, Thomsen HS, Morcos SK, Members of Contrast Media Safety Committee of European Society of Urogenital Radiology (ESUR). The use of iodinated and gadolinium contrast media during pregnancy and lactation. *Eur Radiol.* 2005;15(6): 1234–1240.
- [10] Tanaka M. Study in rats treated intravenously with GMK-527 (II) teratogenicity study in rats with GMK-527. *Yakuri Chiryō.* 1988;16:93–106.
- [11] Sousa Gomes M, Guimarães M, Montenegro N. Thrombolysis in pregnancy: a literature review. *J Mater-Fetal Neonatal Med.* 2019;32:2418–2428.
- [12] Gartman EJ. The use of thrombolytic therapy in pregnancy. *Obstet Med.* 2013;6(3):105–111.
- [13] Powers WJ, Rabinstein AA, Ackerson T, et al. Guidelines for the early management of patients with acute ischemic stroke: a guideline for healthcare professionals from the American Heart Association/American Stroke Association. *Stroke.* 2018;49(3): e46–e99. 2018
- [14] Ishii A, Miyamoto S. Endovascular treatment in pregnancy. *Neurol Med Chir.* 2013;53(8):541–548.

- [15] Aaron S, Shyamkumar NK, Alexander S, et al. Mechanical thrombectomy for acute ischemic stroke in pregnancy using the penumbra system. *Ann Indian Acad Neurol.* 2016;19:261–263.
- [16] Bhogal P, Aguilar M, AlMatter M, et al. Mechanical thrombectomy in pregnancy: report of 2 cases and review of the literature. *Intervent Neurol.* 2017;6(1-2): 49–56.
- [17] Zhu F, Gory B, Mione G, et al. Combined reperfusion therapy to treat cryptogenic acute ischemic stroke during the first trimester of pregnancy: case report and literature review. *Ther Clin Risk Manage.* 2018;14: 1677–1683.
- [18] Shah SS, Snelling BM, Brunet MC, et al. Transradial mechanical thrombectomy for proximal middle cerebral artery occlusion in a first trimester pregnancy: case report and literature review. *World Neurosurg.* 2018;120:415–419.
- [19] Watanabe TT, Ichijo M, Kamata T. Uneventful pregnancy and delivery after thrombolysis plus thrombectomy for acute ischemic stroke: case study and literature review. *J Stroke Cerebrovasc Dis.* 2019;28(1): 70–75.
- [20] Blythe R, Ismail A, Naqvi A. Mechanical thrombectomy for acute ischemic stroke in pregnancy. *J Stroke Cerebrovasc Dis.* 2019;28(6):e75–e76.