

Teaching Video NeuroImages: Acute hemichorea-hemiballism reverted after IV thrombolysis

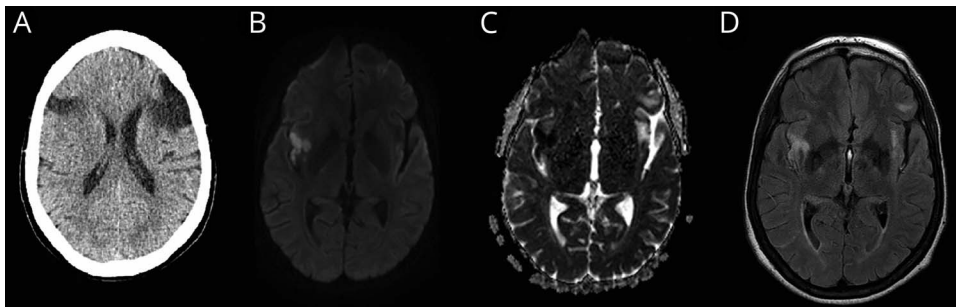
Caio Disserol, MD, Bárbara Alencar, MD, Jacy Parmera, MD, Adriana Bastos Conforto, MD, PhD, and Lécio Figueira Pinto, MD, PhD

Neurology® 2020;94:e121-e122. doi:10.1212/WNL.0000000000008706

Correspondence

Dr. Disserol
caio.disserol@hc.fm.usp.br

Figure Imaging



Head CT scan shows old infarcts (A) and brain MRI shows an acute stroke involving the right insular cortex and capsula extrema on diffusion-weighted (B), apparent diffusion coefficient map (C), and fluid-attenuated inversion recovery (D) images.

A 59-year-old woman was admitted with acute left hemichorea-hemiballism. Blood glucose level was 87 mg/dL. Head CT scan showed old infarcts (figure). The patient underwent thrombolysis with IV alteplase (0.9 mg/kg) within 86 minutes of symptom onset, evolving with partial improvement after 2 hours (video) and complete resolution after 24 hours without other treatments. Brain MRI showed an acute stroke in the right insula (figure), known to be functionally connected to the posterolateral putamen.¹ Hemichorea-hemiballism is an uncommon presentation of stroke and may be caused by insular, putaminal, and various other lesions connected to the same network.^{1,2}

Study funding

No targeted funding reported.

Disclosure

The authors report no disclosures relevant to the manuscript. Go to Neurology.org/N for full disclosures.

References

1. Laganier S, Boes A, Fox M. Network localization of hemichorea-hemiballismus. *Neurology* 2016;86:2187–2195.
2. Bembenek JP, Bilik M, Czlonkowska A. Successful treatment with intravenous recombinant tissue plasminogen activator in an acute stroke patient presenting with hemiballism. *Funct Neurol* 2015;30:71–72.

MORE ONLINE

▶ Video

→ Teaching slides

links.lww.com/WNL/B19

From the Department of Neurology, Hospital das Clínicas, University of São Paulo Medical School, Brazil.

Go to Neurology.org/N for full disclosures. Funding information and disclosures deemed relevant by the authors, if any, are provided at the end of the article.

Appendix Authors

Name	Location	Role	Contribution
Caio Disserol, MD	Hospital das Clínicas, University of São Paulo Medical School	Author	Wrote the manuscript, data collection, analysis, and interpretation
Bárbara Alencar, MD	Hospital das Clínicas, University of São Paulo Medical School	Author	Data collection, analysis, and interpretation
Jacy Parmera, MD	Hospital das Clínicas, University of São Paulo Medical School	Author	Conceptualization of the study, interpretation of the data, revision of the manuscript
Adriana Bastos Conforto, MD, PhD	Hospital das Clínicas, University of São Paulo Medical School	Author	Interpretation of the data, revision of the manuscript
Lécio Figueira Pinto, MD, PhD	Hospital das Clínicas, University of São Paulo Medical School	Author	Conceptualization of the study, interpretation of the data, revision of the manuscript

Neurology®

Teaching Video NeuroImages: Acute hemichorea-hemiballism reverted after IV thrombolysis

Caio Disserol, Bárbara Alencar, Jacy Parmera, et al.

Neurology 2020;94:e121-e122

DOI 10.1212/WNL.00000000000008706

This information is current as of December 30, 2019

Updated Information & Services	including high resolution figures, can be found at: http://n.neurology.org/content/94/1/e121.full
References	This article cites 2 articles, 1 of which you can access for free at: http://n.neurology.org/content/94/1/e121.full#ref-list-1
Subspecialty Collections	This article, along with others on similar topics, appears in the following collection(s): All Cerebrovascular disease/Stroke http://n.neurology.org/cgi/collection/all_cerebrovascular_disease_stroke Chorea http://n.neurology.org/cgi/collection/chorea MRI http://n.neurology.org/cgi/collection/mri
Permissions & Licensing	Information about reproducing this article in parts (figures, tables) or in its entirety can be found online at: http://www.neurology.org/about/about_the_journal#permissions
Reprints	Information about ordering reprints can be found online: http://n.neurology.org/subscribers/advertise

Neurology® is the official journal of the American Academy of Neurology. Published continuously since 1951, it is now a weekly with 48 issues per year. Copyright © 2019 American Academy of Neurology. All rights reserved. Print ISSN: 0028-3878. Online ISSN: 1526-632X.

