



Contents lists available at ScienceDirect

Journal of Clinical Neuroscience

journal homepage: www.elsevier.com/locate/jocn

Case report

Blepharospasm as the presenting feature of papillary thyroid cancer and parathyroid adenoma

Roland Dominic G. Jamora^{a,b,*}, Adrian I. Espiritu^{b,c}, Janet J. Santiago^d, Jocelyn J. Wohldorf^e, Joven R. Cuanang^d^a Movement Disorders Service and Section of Neurology, Institute for Neurosciences, St. Luke's Medical Center, Quezon City, Philippines^b Department of Neurosciences, College of Medicine, Philippine General Hospital, University of the Philippines Manila, Manila, Philippines^c Department of Clinical Epidemiology, College of Medicine, University of the Philippines Manila, Philippines^d Section of Neurology, Institute for Neurosciences, St. Luke's Medical Center, Quezon City, Philippines^e Section of Endocrinology, Department of Medicine, St. Luke's Medical Center, Quezon City, Philippines

ARTICLE INFO

Article history:

Received 9 September 2019

Accepted 16 December 2019

Available online xxxx

Keywords:

Blepharospasm

Papillary thyroid carcinoma

Parathyroid adenoma

Focal dystonia

Case report

ABSTRACT

Blepharospasm is a type of focal dystonia depicted by periodic and spontaneous closure of the orbicularis oculi and surrounding muscles. Typical secondary etiologies of blepharospasm may include ophthalmologic and structural brain lesions. In this article, we report a novel case of a patient with a biopsy-proven concurrent papillary carcinoma of the thyroid gland and adenoma of the parathyroid gland with blepharospasm as an exceptionally unique initial manifestation. This report showed that a diagnostic work-up for causes of blepharospasm may include a search for these neoplasm and surgical removal of these masses may offer significant symptomatic control of the focal dystonia.

© 2019 Elsevier Ltd. All rights reserved.

1. Background

Blepharospasm is a specific type of focal dystonia characterized by hyperactivity of the orbicularis oculi and muscles surrounding the eyes. This condition typically presents with stereotyped, bilateral, involuntary, synchronous eyelid narrowing or closure with associated with increased blinking rate and maneuvers which reduce the dystonic symptoms (termed as *sensory tricks*). Secondary blepharospasm is considered less common than primary or idiopathic blepharospasm. In this article, we report an exceptionally rare case of secondary blepharospasm associated with papillary thyroid cancer and parathyroid adenoma.

2. Case report

A 48-year-old Filipino female was referred to the movement disorder service due to involuntary closure of the eyelids. Two months prior to admission, she noted frequent, intermittent, involuntary blinking of the corner of her left eye after protracted hours of using her personal computer. She consulted an ophthalmologist

and an assessment of error of refraction was provided. She was prescribed with new set of eyeglasses which offered no improvement. Her symptoms gradually progressed which manifested with paroxysmal involuntary closure of the left eyelid that occurred anytime of the day. Then, 2 weeks prior to admission, the right eyelid became similarly involved which presented as intermittent, persistent spontaneous closure of both eyelids with associated difficulty in opening both eyes. Initial thyroid function tests from another institution revealed sub-clinical hypothyroidism. Thyroid ophthalmopathy was suspected which prompted admission to our institution for work-up. Pertinent past medical history was hypertension for ten years with good compliance to medications. Family history was non-contributory.

On physical examination, she was noted to be obese with Cushingoid features such as buffalo hump, fat pads in the supraclavicular area, and globular, flabby abdomen. She presented with evident repeated involuntary blinking of the bilateral eyelids. These abnormal movements are intermingled with recurrent and persistent closure of bilateral eyelids and subsequent difficulty in opening them. Wrinkling was apparent in the procerus and corrugator muscles. The rest of the neurologic examination was unremarkable.

Complete blood counts, initial blood chemistries and bleeding parameters were all within normal limits. A repeat thyroid function test showed normal results. Magnetic resonance imaging of

* Corresponding author at: Department of Neurosciences, College of Medicine, Philippine General Hospital, University of the Philippines Manila, Taft Avenue, Manila 1000, Philippines.

E-mail address: rgjamora@up.edu.ph (R.D.G. Jamora).

the brain showed a chronic microhemorrhage on the left external capsule. Repetitive nerve stimulation studies and chest computed tomography (CT) were unremarkable. Single-fiber electromyography was done which showed a significant increase in jitter values measured in the frontalis muscle.

Focal dystonia in the form of blepharospasm was entertained and she was then referred to the movement disorder service of our institution. However, a repeat blood electrolyte panel showed hypercalcemia at 1.38 mmol/L [normal value (NV): 1.05–1.25]. Further endocrinological workup showed increased parathyroid hormone level at 694 pg/mL (NV: 12–72), increased anti-thyroglobulin antibody at 250 IU/mL (NV: <40 IU/mL), increased anti-thyroperoxidase antibody at 975 IU/mL (NV: <35 IU/mL). Thyroid ultrasound showed bilateral multiple solid nodules of varying sizes (see Fig. 1A and B). Whole abdominal CT scan showed an enlarged uterus with multiple myoma, right ureterovesical junction

lithiasis with renal cyst on the left (see Fig. 1C and D). A pituitary imaging was also done to look for any sestamibi-avid lesion denoting the presence of pituitary adenoma, however the imaging was normal (see Fig. 1E to H). The patient underwent ultrasound guided biopsy of the left thyroid nodule, revealing a follicular neoplasm (see Fig. 2A). She underwent total thyroidectomy with left superior parathyroidectomy. The biopsy of the left superior parathyroid gland showed a parathyroid adenoma (see Fig. 2B and C); the left thyroid lobe and isthmus revealed follicular adenoma in a background of lymphocytic thyroiditis (see Fig. 2D and E), and the right thyroid lobe showed Hashimoto's Thyroiditis with calcifications, microfocus of papillary carcinoma, follicular variant (see Fig. 2F and G).

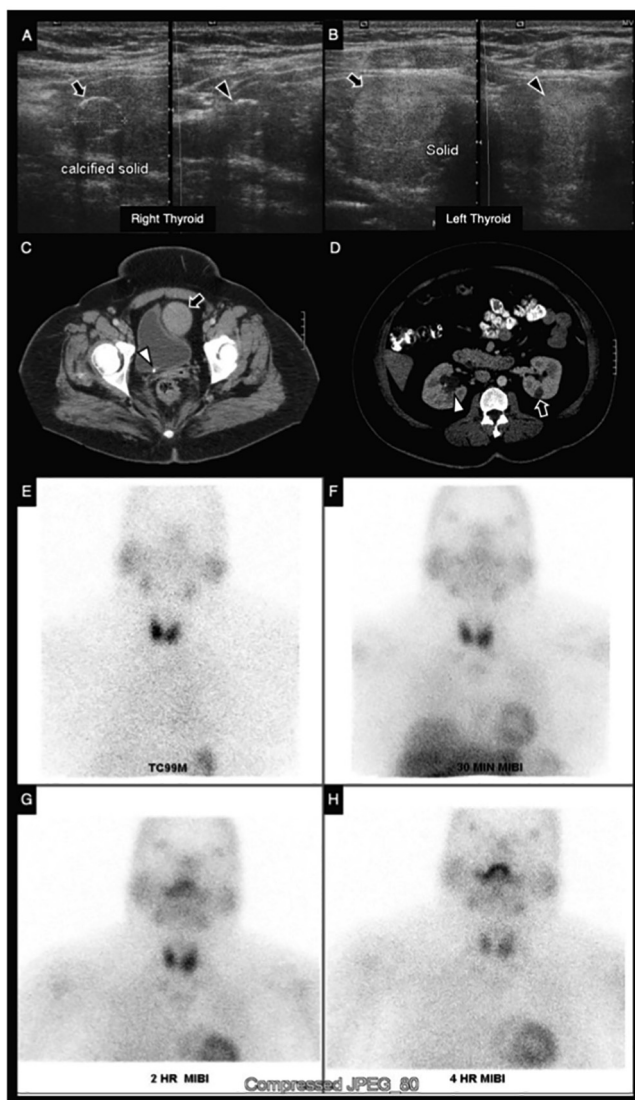


Fig. 1. Pertinent radiologic imaging of the case. The right lobe of the thyroid gland showed solid nodules with rim calcifications measuring $1.1 \times 0.9 \times 0.9$ cm at the upper third (A; arrow) and $0.4 \times 0.5 \times 0.4$ cm at the lower third (A; arrowhead). The left lobe of the thyroid glands displayed solid nodules measuring $2.2 \times 1.6 \times 1.6$ cm at the middle third (B; arrow) and $1.1 \times 0.7 \times 0.8$ cm at the lower third (B; arrowhead). Axial view of the abdominal CT scan demonstrated an enlarged uterus with a knobby outline suggestive of myoma formation (C; arrow), a right ureterovesical junction lithiasis (C; arrowhead), a left renal cyst (D; arrow) and mild hydronephrosis on the right (D; arrowhead). Parathyroid imaging with technetium 99 m (Tc99m) sestamibi (MIBI) scintigraphy showed normal imaging.

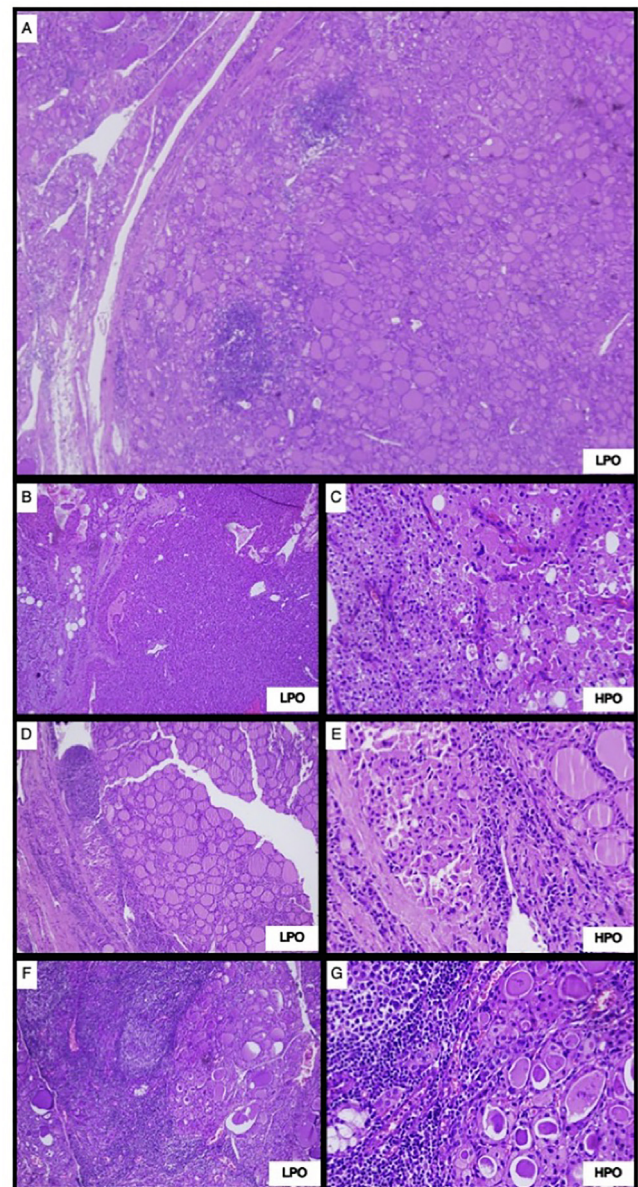


Fig. 2. Biopsy with hematoxylin-eosin stain of thyroid and parathyroid glands. Ultrasound-guided of the left thyroid nodule revealed a follicular neoplasm (A). Total thyroidectomy and left superior parathyroidectomy biopsy revealed the following: left superior parathyroid specimen showed a parathyroid adenoma (B and C); left thyroid lobe and isthmus specimen revealed follicular adenoma in the background of lymphocytic thyroiditis (D and E); and right thyroid lobe specimen displayed Hashimoto's thyroiditis with calcifications, microfocus of papillary carcinoma of follicular variant (F and G). HPO, high power objective magnification; LPO, low power objective magnification.

Post-operatively, an apparent gradual resolution of the involuntary closure of the eyelids was noted. Opening of both eyelids after a tight closure can now be done with ease. She was maintained on calcium carbonate 600 mg/tablet 2 tablets thrice per day and calcitriol 0.25 µg/capsule 1 capsule once daily. The patient underwent radioactive I-131 therapy with a dose of 100 mCi one month post-operatively. At present, 11 years later, the patient is doing well.

3. Discussion

Epidemiological studies on blepharospasm reported a varying prevalence ranging from 20 to 133 cases per million differing on geography [1,2]. The persistent eyelid closure in blepharospasm is frequently heralded by progressive increased blinking rate, which is considered the *forme fruste* of this condition [2]. Patients with blepharospasm usually experience eye irritation or photophobia prior to the onset of uncontrollable blinking [3]. The abnormal eyelid movements may be as a result of orbicularis oculi muscle spasms, or due to the apraxia of eyelid opening presenting as absence of levator palpebrae contraction [3]. Some central nervous system areas, which include the rostral brainstem, thalamus, and the basal ganglia, have been linked with the occurrence of blepharospasm [4]. A structural lesion, which trigger a dysfunction of the descending basal ganglia pathway leading to hyperexcitability of the interneurons of the brainstem, was associated with blepharospasm [5]. In neurophysiological studies of patients with blepharospasm, there was a reduction of inhibition of the R2 response by supra-orbital nerve electrical stimulation and there was note of an abnormality of plasticity in the blink reflex circuit [6,7].

The following differential diagnoses were deliberated as to the causation of the underlying problem in our patient: ophthalmologic, autoimmune, metabolic or endocrine, and possible association with malignancy.

Ophthalmologic disorders, such as blepharitis, may trigger spontaneous movements of the orbicularis oculi muscle via the trigeminal-palpebral reflex [8]. Blepharitis due to infection or allergies not evident in our case; hence, this was readily ruled-out.

Myasthenia gravis, an autoimmune disorder, was initially considered due to the absence of movement of the levator palpebrae muscle; however, the characteristic exercise-induced and fatigable weakness of myasthenia was not present in our case. An increase in jitter values in frontalis muscle during SF-EMG is not very specific for ocular myasthenia because these findings can also be present in other nerve or muscles diseases and other autoimmune conditions such as in thyroiditis. Therefore, both clinical and electrophysiological examinations must be compatible to lead to a diagnosis of myasthenia [9].

Malignancy is one of the differential causes of hypercalcemia [10]. The proximal cause of hypercalcemia in malignancy is due to increased bone resorption. Its clinical manifestations may include nausea, vomiting, constipation, polyuria and neurologic manifestations may range from weakness, lethargy, confusion and coma. When parathyroid hormone level is elevated in a patient with hypercalcemia and other causes have been eliminated, a primary hyperparathyroidism is considered [11]. Hyperparathyroidism is manifested by protracted rises in blood calcium, kidney stones and bone decalcification, and typically caused by a parathyroid tumor that secretes unregulated high levels of parathyroid hormone. The principal sign of thyroid carcinoma, on the other hand, is typically a painless palpable, firm, and non-tender nodule which could be solitary or a dominant one in a multinodular goiter. In the literature, blepharospasm has not been reported as an initial clinical presentation of both parathyroid and thyroid malignancies. The characteristic symptoms of parathyroid and thyroid tumors were not manifested in our patient but was diagnosed only after incidental findings of multiple nodular goiter, hypercalcemia and kidney stones.

Autopsy studies of patients with cranial dystonia, including blepharospasm, offered very limited information. Pathological report of the brains of few patients with this disorder appeared to be unremarkable or with nonspecific abnormalities [12]. There was a case report of a 68-year-old female who was diagnosed with poorly differentiated adenocarcinoma associated with blepharospasm, spasmodic dysphonia, and cervical dystonia. The patient died in the hospital and her brain was inspected under the microscope. Histological examination did not show abnormality but the amount of norepinephrine in the brainstem was peculiarly increased [13].

There are no proposed diagnostic work-up for blepharospasm. However, cranial imaging may be done if warranted. The treatment ranges from pharmacotherapy, botulinum toxin injections and surgery [2].

This study increases the awareness of a possible secondary cause of dystonia. This case also provides additional evidence of the vast clinical spectrum seen in papillary thyroid cancer and parathyroid adenoma. We suggest that patients presenting with focal dystonia in the form of blepharospasm, a thyroid and parathyroid should be considered.

4. Conclusion

To our knowledge, ours is a novel case documenting blepharospasm as an initial clinical manifestation prior to the detection of thyroid and parathyroid masses. Aside from the typical secondary etiologies of blepharospasm such as ophthalmologic, structural brain lesions, metabolic and endocrine causes, a diagnostic search for thyroid and parathyroid neoplasms may be considered. Our case revealed that a significant symptom improvement of the focal dystonia may be achieved by surgical removal of these neoplasms.

Role of funding source

This research did not receive any specific grant from funding agencies in the public, commercial, or not-for-profit sectors.

CRediT authorship contribution statement

Roland Dominic G. Jamora: Conceptualization, Data curation, Formal analysis, Investigation, Project administration, Supervision, Validation, Visualization, Writing - original draft, Writing - review & editing. **Adrian I. Espiritu:** Conceptualization, Data curation, Formal analysis, Investigation, Validation, Visualization, Writing - original draft, Writing - review & editing. **Janet J. Santiago:** Conceptualization, Data curation, Formal analysis, Investigation, Validation, Visualization, Writing - original draft, Writing - review & editing. **Jocelyn J. Wohldorf:** Conceptualization, Data curation, Formal analysis, Investigation, Validation, Visualization, Writing - original draft, Writing - review & editing. **Joven R. Cuanang:** Conceptualization, Data curation, Formal analysis, Investigation, Project administration, Supervision, Validation, Visualization, Writing - original draft, Writing - review & editing.

Declaration of Competing Interest

None. There are no conflicts of interest to declare in this research.

Appendix A. Supplementary data

Supplementary data to this article can be found online at <https://doi.org/10.1016/j.jocn.2019.12.025>.

References

- [1] Steeves TD, Day L, Dykeman J, Jette N, Pringsheim T. The prevalence of primary dystonia: a systematic review and meta-analysis. *Mov Disord* 2012;27:1789–96. <https://doi.org/10.1002/mds.25244>.
- [2] Defazio G, Hallett M, Jinnah HA, Conte A, Berardelli A. Blepharospasm 40 years later. *Mov Disord* 2017;32:498–509. <https://doi.org/10.1002/mds.26934>.
- [3] Hallett M, Evinger C, Jankovic J, Stacy M. Update on blepharospasm: report from the BEBRF International Workshop. *Neurology* 2008;71:1275–82. <https://doi.org/10.1212/01.wnl.0000327601.46315.85>.
- [4] Jankovic J. Blepharospasm with basal ganglia lesions. *Arch Neurol* 1986;43:866–8.
- [5] Grandas F, Elston J, Quinn N, Marsden CD. Blepharospasm: a review of 264 patients. *J Neurol Neurosurg Psychiatry* 1988;51:767–72. <https://doi.org/10.1136/innp.51.6.767>.
- [6] Berardelli A, Rothwell JC, Day BL, Marsden CD. Pathophysiology of blepharospasm and oromandibular dystonia. *Brain* 1985;108:593–608. <https://doi.org/10.1093/brain/108.3.593>.
- [7] Quartarone A. Enhanced long-term potentiation-like plasticity of the trigeminal blink reflex circuit in blepharospasm. *J Neurosci* 2006;26:716–21. <https://doi.org/10.1523/JNEUROSCI.3948-05.2006>.
- [8] Jankovic J. Etiology and differential diagnosis of blepharospasm and oromandibular dystonia. *Adv Neurol* 1988;49:103–16.
- [9] Sanders DB, Stålberg EV. AAEM minimonograph #25: single-fiber electromyography. *Muscle Nerve* 1996;19:1069–83. [https://doi.org/10.1002/\(SICI\)1097-4598\(199609\)19:9<1069::AID-MUS1>3.0.CO;2-Y](https://doi.org/10.1002/(SICI)1097-4598(199609)19:9<1069::AID-MUS1>3.0.CO;2-Y).
- [10] Bilezikian JP, Silverberg SJ. Asymptomatic primary hyperparathyroidism. *N Engl J Med* 2004;350:1746–51. <https://doi.org/10.1056/NEJMc032200>.
- [11] Hall TC, Schaiff RA. Update on the medical treatment of hypercalcemia of malignancy. *Clin Pharm* 1993;12:117–25.
- [12] Gibb WRG, Lees AJ, Marsden CD. Pathological report of four patients presenting with cranial dystonias. *Mov Disord* 1988;3:211–21. <https://doi.org/10.1002/mds.870030305>.
- [13] Jankovic J, Svendsen CN, Bird ED. Brain neurotransmitters in dystonia. *N Engl J Med* 1987;316:278–9. <https://doi.org/10.1056/NEJM198701293160515>.