



Methylprednisolone pulse therapy as an adjuvant treatment of *Streptococcus pneumoniae* meningitis complicated by cerebral infarction—a case report and review of the literature

Oi-Wa Chan¹ · Jainn-Jim Lin^{1,2,3} · Shao-Hsuan Hsia¹ · Chia-Ying Lin¹ · Kung-Lin Lin²

Received: 9 March 2018 / Accepted: 19 December 2019
© Springer-Verlag GmbH Germany, part of Springer Nature 2020

Abstract

Purpose The role of methylprednisolone pulse therapy as adjuvant treatment of *Streptococcus pneumoniae* meningitis complicated by cerebral infarction has rarely been reported.

Methods We reported a case report and also performed a systematic literature review.

Results A 1-year 2-month-old boy who presented with high fever, status epilepticus, and septic shock was diagnosed with cerebral infarction caused by *Streptococcus pneumoniae* meningitis on magnetic resonance imaging (MRI). He was treated with methylprednisolone pulse therapy and his clinical condition gradually improved thereafter. At the follow-up visit 1 year after discharge, he was able to sit without support, but he had moderate delays in speech and developmental milestones and epilepsy sequelae.

Conclusion In severe cases, the use of high-dose methylprednisolone should be considered to modulate the inflammatory response in patients with severe cerebral infarction caused by *Streptococcus pneumoniae* meningitis.

Keywords Methylprednisolone · *Streptococcus pneumoniae* · Meningitis · Cerebral infarction

Introduction

Acute severe bacterial meningitis is a medical emergency, and *Streptococcus pneumoniae* is a common cause. Extension into the brain parenchyma is often fatal or leads to severe neurological deficits [1, 6, 13, 15]. Even when antibiotic treatment is started early, severe neurological sequelae frequently occur, which may be caused by an intense inflammatory response of the host [13]. Corticosteroids have been proposed as adjuvant therapy for many years as they reduce the inflammatory

response [5], and meta-analyses of trial data now support treatment with dexamethasone as adjunctive therapy to significantly reduce neurological sequelae, although not overall mortality [3, 4]. However, once severe cerebral infarction, which is secondary vasculitis caused by *Streptococcus pneumoniae* meningitis, is observed on magnetic resonance imaging (MRI), very high immunosuppressive rather than anti-inflammatory doses of steroids may be required in order to modulate the marked inflammatory cascade [7, 12]. Herein, we report a pediatric patient with cerebral infarction caused by *Streptococcus pneumoniae* meningitis, and systematically review the literature with regard to methylprednisolone pulse therapy as adjuvant treatment in this situation [8–10, 14].

✉ Jainn-Jim Lin
lin0227@adm.cgmh.org.tw

¹ Division of Pediatric Critical Care Medicine and Pediatric Neurocritical Care Center, Chang Gung Children's Hospital and Chang Gung Memorial Hospital, Chang Gung University College of Medicine, Taoyuan, Taiwan
² Division of Pediatric Neurology, Chang Gung Children's Hospital and Chang Gung Memorial Hospital, Chang Gung University College of Medicine, Taoyuan, Taiwan
³ Graduate Institute of Clinical Medical Sciences, College of Medicine, Chang Gung University, Taoyuan, Taiwan

Case report

A 1-year 2-month-old previously healthy boy was admitted to our hospital due to a high fever with status epilepticus and septic shock. He had been followed for an upper respiratory tract infection for 7 days before admission. On admission, he was in a coma with a Glasgow Coma Scale (GCS) of 6/15 (E1V1M4). A detailed

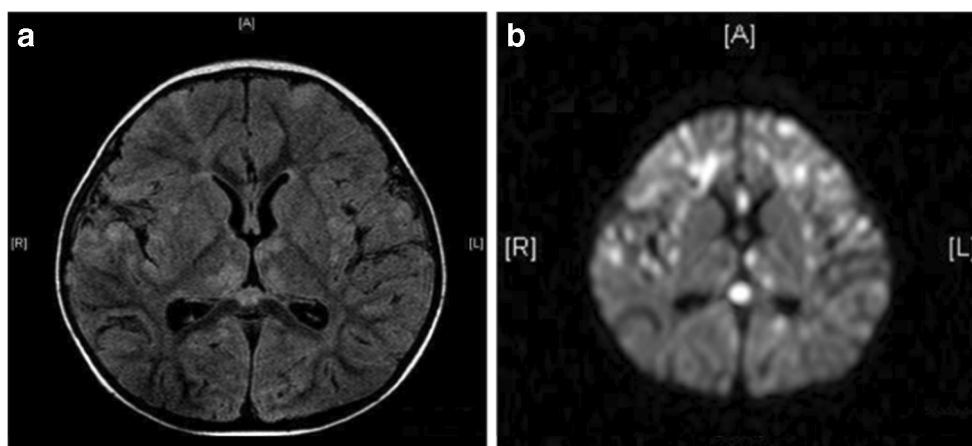


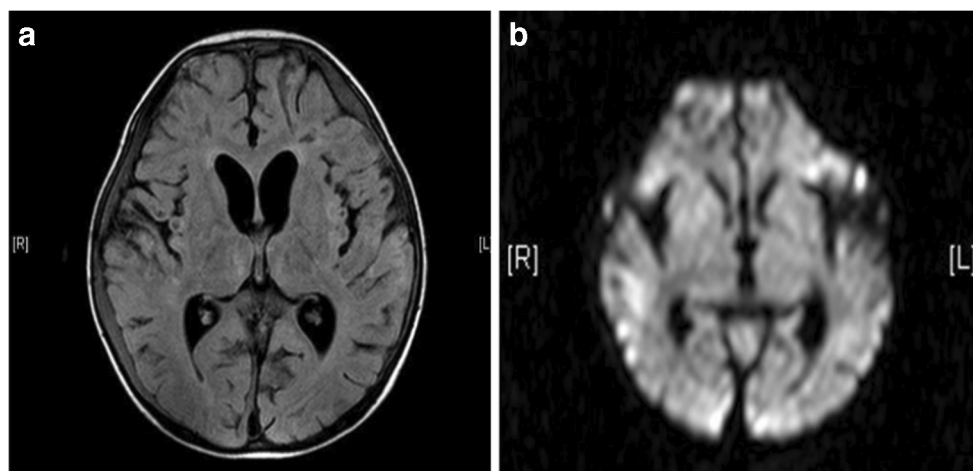
Fig. 1 Brain magnetic resonance imaging (MRI) on day 4 after admission revealed multiple asymmetrical patchy areas of hyperintensity on T2-weighted fluid-attenuated inversion recovery (T2-FLAIR) images, in both white and gray matter in bilateral hemispheres, bilateral lentiform nuclei, thalami, hypothalami, corpus callosum, and brainstem (white

arrow) (a). All of the lesions showed high signal intensity in diffusion-weighted imaging (DWI) (b), suggesting acute infarction. On the basis of these findings, the diagnosis of cerebral infarction caused by *Streptococcus pneumoniae* meningitis was made

neurological examination showed positive meningeal and Babinski signs, and hematological tests showed a white blood cell (WBC) count of 3500/ μ L and C-reactive protein (CRP) level of 29.05 mg/dL. Brain computed tomography (CT) findings on admission were normal. A cerebrospinal fluid (CSF) examination was initially refused by the family; however, they finally gave permission and the examination (performed on day 9) showed a high WBC count (16/ μ L), high total protein level (650.9 mg/dL), and low glucose level (64 mg/dL), suggesting bacterial meningitis. A blood culture grew *Streptococcus pneumoniae* serotype 6B; however, a CSF culture showed no growth. Other tests for viral infections such as CSF HSV PCR and serology for influenza virus, HSV, and mycoplasma were negative.

He was initially treated with intravenous antibiotics (vancomycin and ceftriaxone) and dexamethasone (0.6 mg/kg/day). Brain MRI 4 days after admission revealed multiple cerebral infarctions (Fig. 1), and the diagnosis of cerebral infarction caused by *Streptococcus pneumoniae* meningitis was made. Methylprednisolone pulse therapy 30 mg/kg/day for 3 days was prescribed, and his clinical condition gradually improved thereafter. Brain MRI 21 days after admission revealed improvement in the multiple cerebral infarctions (Fig. 2), and he was finally discharged 53 days after admission. At the follow-up visit 1 year after discharge, he had a GCS of 10/15 (E4V2M4), and a detailed neurological examination showed a muscle power of 4/5. He was only able to sit without support; however, he had moderate

Fig. 2 Post-treatment follow-up brain MRI at 21 days after admission revealed improvement in the multiple cerebral infarctions (a T2-FLAIR; b DWI)



delays in speech and developmental milestones and also epilepsy sequelae.

Discussion

Cerebral infarcts are not uncommon complications of severe bacterial meningitis and have been reported in 21.8% of adult cases [6]. We reviewed the English-language literature through searches of PubMed, Medline, Up To Date, Embase, and Cochrane evidence-based reviews from 1990 to 2016 using keywords related to methylprednisolone, *Streptococcus pneumoniae*, meningitis, meningoencephalitis, cerebral infarction, neurological sequelae, and encephalopathy. We only included cases that had MRI evidence of cerebral infarction and those who received methylprednisolone pulse therapy as adjuvant treatment [8–10, 14] (Tables 1 and 2).

Four reports including six cases and the current patient were reviewed (Table 1). Three patients were adults (> 18 years) and four were children (< 18 years). All of the cases were admitted with severe illness and experienced rapid neurological deterioration including altered consciousness in all patients, seizure/status epilepticus in five patients, and focal neurological abnormalities (anisocoria and hemiparesis) in three patients. All patients had positive *Streptococcus pneumoniae* blood and/or CSF cultures. Neuroimaging showed high signal abnormalities involving both gray and white matter on T2-weighted MRI images and restricted diffusion on diffusion-weighted MRI, reflecting local areas of ischemia with cytotoxic edema. Four patients were initially treated with adjunctive dexamethasone therapy. After clinical deterioration, six patients were treated with methylprednisolone pulse therapy and one patient received intravenous immunoglobulin followed by methylprednisolone pulse therapy. Four (57.1%) of the patients recovered to baseline, and the remaining three (42.8%) patients had neurological sequelae.

The early identification of rapid neurological deterioration and signs of encephalopathy is of utmost importance [1, 6, 15]. Brain MRI, especially diffusion-weighted imaging, may help in diagnosing the lesions [2, 9, 16]. In our review, all of the patients had rapid neurological deterioration and signs of encephalopathy, and they all had abnormal diffusion-weighted MRI findings. Therefore, the use of MRI in patients with a persistent coma due to *Streptococcus pneumoniae* meningoencephalitis is warranted, as it is useful to demonstrate the real extent of cerebral destruction.

The mechanism of cerebral infarction caused by acute bacterial meningitis has been suggested to be due to obliterating vasculitis with thrombosis resulting from inflammatory reactions [11, 13]. First-line therapy for CNS vasculitis in children is mainly based on corticosteroids and immunosuppressants [7, 12]; however, data

Table 1 Patient demographics, clinical features, magnetic resonance imaging, treatment, and outcomes of cerebral infarction caused by *Streptococcus pneumoniae* reported in the literature

Case	Age/sex	Past history	Presenting signs and symptoms			Treatment		Outcome
			Altered mental status	Sz	Other	Antibiotics	Adjuvant	
1 Jorens (2005)	36 y/F	Graves' thyroiditis	Yes (GCS 7)	No	Fever, blurring of vision, dystonia, mydriasis, anisocoria	Ceftriaxone	IVIg (day 5) MP pulse (day 10)	Recovery
2 Jorens (2005)	56 y/M	No	Yes (GCS 10)	No	Fever	Ampicillin, ceftriaxone	MP pulse (day 3)	Recovery
3 Jorens (2005)	67 y/M	Chronic atrial fibrillation	Yes (GCS 10)	SE	Neck stiffness, vomiting	Augmentin, ceftriaxone	Dexamethasone → MP pulse (day 4)	Recovery
4 Jorens (2008)	7 m/F	No	Yes	Yes	Fever, neck stiffness, hemiplegia	Augmentin, ceftriaxone, acyclovir	Dexamethasone → MP pulse (day 4)	Epilepsy, neurologic sequelae
5 Ilija (2011)	4 y/F	No	Yes	Yes	Fever, vomiting, neck stiffness	Vancomycin	Dexamethasone → MP pulse (day 11)	Mild right hemiplegia → recovery
6 Safadiéh (2012)	7 m/M	No	Yes	SE	Fever, dystonia, autonomic dysfunction	Vancomycin, ceftriaxone, acyclovir	MP pulse	Neurologic sequelae
7 Present (2015)	1 y 2 m/M	No	Yes (GCS 6)	SE	Fever, septic shock	Vancomycin, ceftriaxone, acyclovir	Dexamethasone → MP pulse (Day 5)	Neurologic sequelae

y, year; m, month; F, female; M, male; GCS, Glasgow Coma Scale; Sz, seizure; SE, status epilepticus; MP, methylprednisolone; IVIG, intravenous immunoglobulin

Table 2 Laboratory data of patients with cerebral infarction caused by *Streptococcus pneumoniae* reported in the literature

Case	Serum		CSF				Culture of <i>S. pneumoniae</i>		MRI	
	WBC/ μ L	CRP mg/dL	WBC cells/ μ L	PMN/Lym/Mono	Sugar mg/dL	TP mg/dL	Blood	CSF	T2 weight: high signal	DWI: restricted diffusion
1 Jorens (2005)	28,400	-	26	90/-/-	10	903	-	Yes	Yes	Yes
2 Jorens (2005)	18,300	16.2	70	100/-/-	< 10	770	-	Yes	Yes	Yes
3 Jorens (2005)	-	-	44	40/60	89	154	-	No*	Yes	Yes
4 Jorens (2008)	8400	36.3	69	90/-/-	20	254	-	Yes (6)	Yes	Yes
5 Ilia (2011)	11,100		155	-	1	325	-	Yes(23F)	Yes	Yes
6 Safadieh (2012)	10,200	48.7	100	82/-/-	< 3	320	Yes (19A)	Yes (19A)	Yes	Yes
7 Present (2015)	3500	29.05	16	32/66/2	64	650.9	Yes (6B)	No	Yes	Yes

Streptococcus pneumoniae serotypes are indicated in parentheses

WBC, white blood count; CRP, C-reactive protein; CSF, cerebrospinal fluid; PMN, polymorphonuclear; Lym, lymphocyte; Mono, monocyte; TP, total protein; *S. pneumoniae*, *Streptococcus pneumoniae*; MRI, magnetic resonance imaging; DWI, diffusion-weighted imaging

*Identified by a validated polymerase chain reaction (PCR) as *S. pneumoniae*

on the dosage of corticosteroids in children with CNS vasculitis secondary to bacterial meningitis are lacking. Meta-analyses of trial data now support treatment with dexamethasone as adjunctive therapy of acute bacterial meningitis to significantly reduce intense host inflammatory responses [3, 4]. However, once severe cerebral infarction occurs, which is secondary vasculitis, very high immunosuppressive rather than anti-inflammatory doses of steroids may be required in order to modulate the marked inflammatory cascade [7, 12]. In our case, all of the neurologic sequelae were secondary to cerebral infarction. In addition, the post-treatment follow-up MRI images showed improvement in the infarction lesions (Fig. 2). Therefore, the use of high-dose methylprednisolone should still be considered to modulate the inflammatory response in such patients.

Conclusions

Cerebral infarction caused by *Streptococcus pneumoniae* meningitis is not uncommon. In severe cases, the use of high-dose methylprednisolone should be considered to modulate the inflammatory response in patients with severe cerebral infarction caused by *Streptococcus pneumoniae* meningitis.

Acknowledgments This research was performed by the Pediatric Sepsis Study Group at Chang Gung Children's Hospital in Taoyuan, Taiwan.

Author contributions OWC and JLL conceived the study; CYL, JLL, OWC, SHH, and KLL participated in data collection; and OWC, CYL, and JLL participated in the design and coordination. OWC drafted the manuscript and JLL critically revised the manuscript for important intellectual content.

Funding information The authors disclosed receipt of the following financial support for the research, authorship, and/or publication of this article: The work was supported in part by grants from Chang Gung Memorial Hospital (grants: CMRPG3B0841, CMRPG3B0842, and CMRPG3B0843, IRB: 201600446B0).

Compliance with ethical standards

Conflict of interest The authors declared no potential conflicts of interest with respect to the research, authorship, and/or publication of this article.

References

1. Auburtin M, Porcher R, Bruneel F, Scanvic A, Trouillet JL, Bédos JP, Régnier B, Wolff M (2002) Pneumococcal meningitis in the intensive care unit. Prognostic factors of clinical outcome in series of 80 cases. *Am J Respir Crit Care Med* 165:713–717
2. Aviv RI, Benseler SM, DeVeber G, Silverman ED, Tyrrell PN, Tsang LM, Armstrong D (2007) Angiography of primary central nervous system angiitis of childhood: conventional angiography versus magnetic resonance angiography at presentation. *AJNR Am J Neuroradiol* 28:9–15
3. van de Beek D, Farrar JJ, de Gans J, Mai NT, Molyneux EM, Peltola H, Peto TE, Roine I, Scarborough M, Schultz C, Thwaites GE, Tuan PQ, Zwiderman AH (2010) Adjunctive dexamethasone in bacterial meningitis: a meta-analysis of individual patient data. *Lancet Neurol* 9:254–263
4. Brouwer MC, McIntyre P, Prasad K, van de Beek D (2013) Corticosteroids for acute bacterial meningitis. *Cochrane Database Syst Rev* 6:CD004405
5. de Gans J, van de Beek D (2002) The European dexamethasone in adulthood bacterial meningitis study investigators. Dexamethasone in adults with bacterial meningitis. *N Engl J Med* 347:1549–1556
6. Kastenbauer S, Pfister HW (2003) Pneumococcal meningitis in adults: spectrum of complications and prognostic factors in a series of 87 cases. *Brain* 126:1015–1025

7. Iannetti L, Zito R, Bruschi S et al (2012) Recent understanding on diagnosis and management of central nervous system vasculitis in children. *Clin Dev Immunol* 2012:698327
8. Iliá S, Spanaki AM, Raissaki M, Spoulou VI, Fitrolaki MD, Kanariou M, Tzanakaki G, Briassoulis G (2011) Complicated pneumococcal meningitis in a fully vaccinated child: value of magnetic resonance imaging monitoring. *Neuropediatrics* 42:240–244
9. Jorens PG, Parizel PM, Demey HE, Smets K, Jadoul K, Verbeek MM, Wevers RA, Cras P (2005) Meningoencephalitis caused by *Streptococcus pneumoniae*: a diagnostic and therapeutic challenge. Diagnosis with diffusion-weighted MRI leading to treatment with corticosteroids. *Neuroradiology* 47:758–764
10. Jorens PG, Parizel PM, Wojciechowski M, Laridon A, de Weerd A, Mertens G, Ceulemans B (2008) *Streptococcus pneumoniae* meningoencephalitis with unusual and widespread white matter lesions. *Eur J Paediatr Neurol* 12:127–132
11. Laky D, Filon V, Rădulescu M, Socolovschi S, Hălălău F (1992) Up-to-date aspects of meningoencephalitis. *Anatomo-clinical researches. Romanian J Morphol Embryol* 38:107–114
12. McDanel LM, Fields JD, Bourdette DN, Bhardwaj A (2010) Immunomodulatory therapies in neurologic critical care. *Neurocrit Care* 12:132–143
13. Mook-Kanamori BB, Geldhoff M, van der Poll T, van de Beek D (2011) Pathogenesis and pathophysiology of pneumococcal meningitis. *Clin Microbiol Rev* 24:557–591
14. Safadieh L, Sharara-Chami R, Dabbagh O (2012) Paroxysmal autonomic instability with dystonia after pneumococcal meningoencephalitis. *Case Rep Med* 2012:965932
15. Schutte C, van der Meyden C (1998) A prospective study of Glasgow Coma Scale (GCS), age, CSF-neutrophil count, and CSF-protein and glucose levels as prognostic indicators in 100 adult patients with meningitis. *J Inf Secur* 37:112–115
16. Teixeira J, Zimmerman RA, Haselgrove JC, Bilaniuk LT, Hunter JV (2001) Diffusion imaging in pediatric central nervous infections. *Neuroradiology* 43:1031–1039

Publisher's note Springer Nature remains neutral with regard to jurisdictional claims in published maps and institutional affiliations.