

Case Report

Nine-years follow-up of cavernoma located in basal ganglia mimicking Parkinson's disease

Raluca Mihaela Modreanu^{a,*}, Carsten Buhmann^b, Björn Hauptmann^{a,c}

^a Parkinson's Disease and Movement Disorders Unit, Department of Neurology, Segeberger Kliniken, Hamdorfer Weg 3, 23795 Bad Segeberg, Germany

^b Department of Neurology, University Medical Center Hamburg-Eppendorf, Martinistrasse 52, 20246 Hamburg, Germany

^c Department Performance, Neuroscience, Therapy and Health, Medical School Hamburg, Am Kaiserkai 1, 20457 Hamburg, Germany

ARTICLE INFO

Keywords:

Secondary parkinsonism
Brain cavernoma
DaTscan
Vascular parkinsonism
Apathy
Right caudate nucleus

1. Introduction

Secondary parkinsonism is a well described entity with a large variety of causes. However, there is a lack of data about parkinsonism caused by cavernoma in the basal ganglia, given its low prevalence (0,46 %) in the general old population, and even lower prevalence of symptomatic-ones (0.037 %) [1]. We report a 75-years-old female patient with 9-year history of non-progressive left parkinsonism and apathy due to a cavernoma in the right striatum.

2. Case report

Our patient was referred to neurologist in 2009 due to acute gait impairment after a severe coughing episode. The neurological examination assessed bradykinesia and rigidity of her left limbs, cogwheel phenomenon of the right upper-limb only by contralateral hand-activation, hypomimia and unsteady gait. The patient referred to a loss of interest in her hobbies in the preceding years and difficulties in initiating speech and movements. Because of her apathy she had been an inpatient in a psychosomatic clinic and received a high dose of a serotonin-norepinephrine reuptake inhibitor, without improvement.

Under the clinical suspicion of Parkinson's disease (PD) she underwent Magnetic Resonance Imaging (MRI), a Dopamine Transporter Single Photon Emission Computerized Tomography (DaTscan) and an olfactory-test. The Brain MRI revealed a 2 cm diameter cavernoma with

signs of subacute hemorrhage involving mainly the right caudate nucleus but also the right putamen, as well as bilateral microangiopathy in the basal ganglia and white matter. The DaTscan showed a severely reduced dopamine transporter uptake in the right striatum, predominantly in the caudate nucleus, and only mildly diminished left striatal binding. The olfactory-test ruled out hyposmia. Because of severe dizzy spells and nausea after 300 mg levodopa-intake, the levodopa-challenge-test was interrupted and therefore could not be assessed. Vascular risk factors such as hypertension, hyperglycemia and dyslipidemia were assessed by routine tests. The patient had no family history of neurodegenerative diseases and she has never taken medication causing secondary parkinsonism. Risk factors for cavernoma such as positive family history or cerebral radiotherapy were also inconspicuous.

She was diagnosed with PD based on her clinical picture and positive DaTscan and medicated with low-dose levodopa.

Since 2011 she has been seen as outpatient annually by the same specialist in movement disorders who has recorded the lack of progress of her left parkinsonism over the years. Only her apathy and gait-unsteadiness have got progressively worse. No rest tremor, motor fluctuations or dyskinesia have ever occurred. The patient claimed a lack of response to levodopa, even after the dosage was gradually raised to 750 mg per day. Symptomatic orthostasis, urinary incontinence, constipation, rapid eye movement behavior disorder (RBD), supranuclear oculomotor disturbance, falls, apraxia or alien limb were absent. There was

* Corresponding author at: Parkinson's Disease and Movement Disorders Unit, Segeberger Kliniken, Neurologisches Zentrum, Hamdorfer Weg 3, 23795, Bad Segeberg, Germany.

E-mail address: raluca.modreanu@segebergerkliniken.de (R.M. Modreanu).

<https://doi.org/10.1016/j.clineuro.2020.105664>

Received 23 July 2019; Received in revised form 22 October 2019; Accepted 1 January 2020

Available online 02 January 2020

0303-8467/ © 2020 Elsevier B.V. All rights reserved.

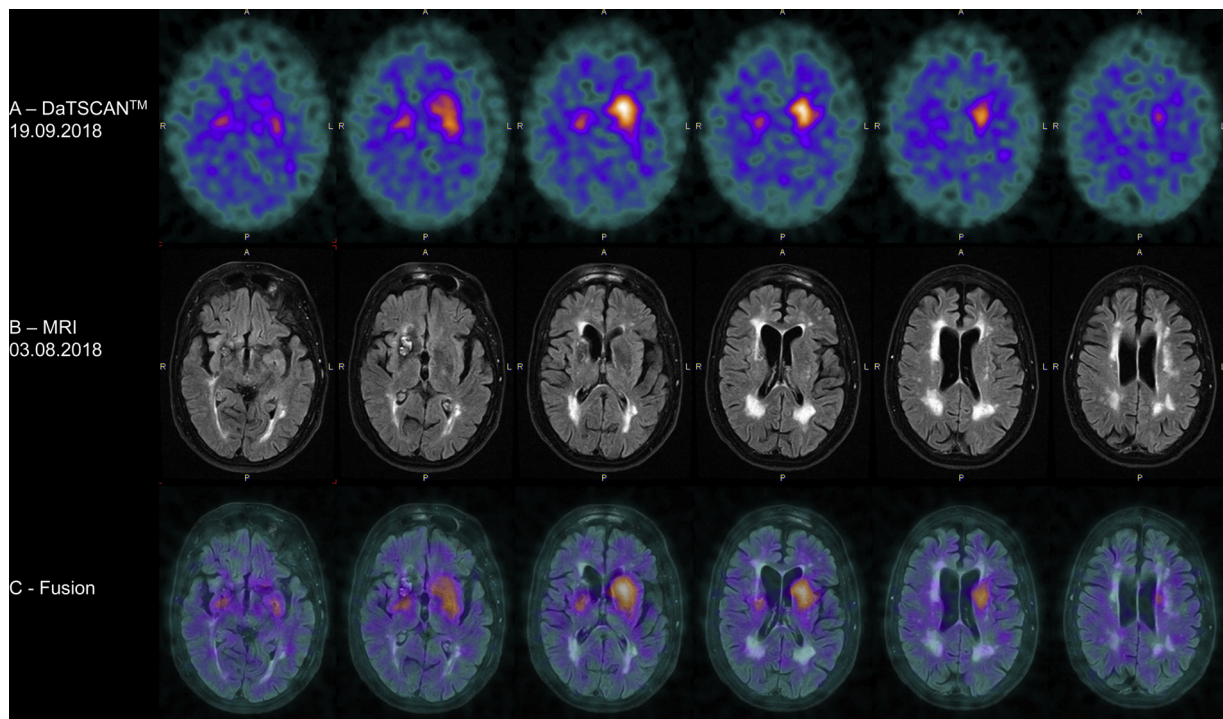


Fig. 1. A:DaTSCAN™. DaTSCAN™ shows severe decreased tracer (ioflupane 123) uptake in the right striatum (predominantly in the right caudate nucleus) and only mild decreased tracer in the left striatum. **B: MRI.** MRIFLAIR axial cutshows the cavernoma located in the right basal ganglia affecting mostly the right caudate nucleus, multiple microangiopathic lesions and lacunar infarcts in the striatum and white matter bilateral. **C: Fusion.** Fusion shows narrow correlation between MRI findings and DaTSCAN™.

no spasticity or other pyramidal signs bilateral.

In 2018 she was admitted to our movement disorders clinic as an inpatient. Because of the lack of progression of her parkinsonism over nine years and the referred lack of response to levodopa, we decided to re-evaluate her diagnostically. A 300 mg levodopa- as well as up to 6 mg apomorphin-challenge-tests were performed and both showed no improvement by UPDRS Scale Part 3. In off-medication we assessed bradykinesia and rigor of her left upper- and lower-limb. Besides cog-wheel-phenomenon by contralateral activation maneuver, no rigidity or bradykinesia of her right limbs were assessed in off-medication. Rest tremor was absent bilateral. A Brain MRI showed a slight enlargement of her cavernoma, affecting predominantly the right caudate nucleus, and a moderate increment of the microangiopathy. A hyper-echogenicity of the substantia nigra was excluded sonographically. Her medication was checked again to exclude any drugs which could cause secondary parkinsonism. We decided to repeat a DaTscan to assess a possible disease progression, which showed a mild-to-moderate worsening of the dopamine transporter uptake bilateral compared to 2011, affecting mostly the right caudate nucleus. Because of the negative levodopa- and apomorphin-test we decided to discontinue progressively her levodopa. After a week without levodopa, no worsening of her symptoms occurred.

Because of the negative levodopa- and apomorphin-test, no worsening of the symptoms after levodopa-discontinuation, one-sided parkinsonism contralateral to the hemangioma without bilateralization nine years after the first neurological assessment, no progression of her rigor and bradykinesia over nine years, negative brainstem sonography and absence of red-flags suggesting atypical parkinsonism, we diagnosed her with secondary parkinsonism caused by cavernoma.

3. Discussion

There are few descriptions in the medical literature about clinically manifested cavernoma of the central nervous system leading to

movement disorders or RBD [2–6]. Only two of them are about secondary parkinsonism induced by cavernoma in basal ganglia [2,3], presumably due to the compression of the cavernoma on the near structures, as we hypothesize in our patient. Unlike our patient, none of these cases has been clinically and paraclinically followed up over nine years.

By the first neurological assessment, the clinical presentation and the positive DaTscan made the differential diagnosis between the idiopathic PD and secondary parkinsonism with mood and gait disturbance due to cavernoma and microangiopathy, difficult. However, the lack of bilateralization and the non-progressive course of the parkinsonism over the years, as well as no response to levodopa, pointed out to the secondary genesis due to cavernoma. There were no acute episodes of worsening as expected by bleeding from cavernoma. There was no progression of her parkinsonism, as expected in PD. After levodopa-withdrawal there was no worsening of her motor symptoms.

Her apathy, present throughout the course of the disease, did not improve with a serotonin-norepinephrine reuptake inhibitor or levodopa, even when the dose was increased to 750 mg, and did not worsen after levodopa-withdrawal, either. We hypothesize that her increasing apathy over the years could be a consequence of the compression on the right caudate nucleus due to the enlargement of the cavernoma, leading to a loss of prefrontal-cortex activation. It has been already demonstrated that a hypoperfusion of the right caudate nucleus is related to the presence of apathy in patients with normal pressure hydrocephalus [7]. Furthermore, Levy et al. hypothesized that a lesion of the caudate nucleus would lead to a loss of activation of the prefrontal-cortex, consequently causing apathy [8].

We consider the progressive gait disturbance, without any change in her parkinsonism, to be at least partially a consequence of the increasing microangiopathy causing leukoaraiosis.

We hypothesize that the pathological DaTscan findings are explained by a tissue lesion caused by cavernoma and bilateral microangiopathy. There is one report about pathological DaTscan by vascular

parkinsonism, which pointed out the association between the reduced dopamine transporter uptake in basal ganglia bilateral and the extensive microangiopathy assessed by Brain MRI [9]. These findings are similar to ours and could explain the distorted shape of the left basal ganglia contralateral to the cavernoma by DaTscan.

However, there is no description in the literature about pathological DaTscan by secondary parkinsonism caused by cavernoma in the basal ganglia. The narrow correlation between Brain MRI and DaTscan (Fig. 1) and the exclusion of other causes for her parkinsonism, led us to the conclusion that DaTscan can also be pathological by cavernoma-induced secondary parkinsonism. Interestingly, Chun et al. reported a focal dopamine transporter uptake in a cavernous hemangioma located in the right frontal bone as an incidental finding by a patient who underwent F-FP CIT PET/CT [10] for her left hand and leg tremor. However, this brief report does not provide further information about the rest of the work-up, neither about the underlying cause of the tremor.

4. Conclusion

We conclude that a cavernoma in the striatum can cause secondary parkinsonism and apathy mimicking PD at the first neurological assessment. However, unlike PD, its natural history can remain unchanged over many years. Furthermore, DaTscan can be pathological in secondary parkinsonism caused by both cavernoma and microangiopathy in the striatum.

Acknowledgements

We thank Dr. R. Buchert and Dr. C Gaebel for supporting the clinical

diagnostic work-up as well as S. Geeson for the English editing.

References

- [1] K.D. Flemming, J. Graff-Radford, J. Aakre, K. Kantarci, G. Lanzino, R.D. Brown, et al., Population-based prevalence of cerebral cavernous malformations in older adults, *JAMA Neurol.* 74 (2017) 801, <https://doi.org/10.1001/jamaneurol.2017.0439>.
- [2] R. Alp, S.I. Alp, H. Üre, Cavernous hemangioma: a rare cause for secondary parkinsonism: a case report, *Int. J. Neurosci.* 119 (2009) 2112–2117, <https://doi.org/10.1080/00207450903139648>.
- [3] S. Ertan, G. Benbir, T. Tanriverdi, I. Alver, M. Uzan, Parkinsonism caused by cavernoma located in basal ganglion, *Parkinsonism Relat. Disord.* 11 (2005) 517–519, <https://doi.org/10.1016/j.parkreldis.2005.07.003>.
- [4] S.-T. Li, J. Zhong, Surgery for mesencephalic cavernoma: case report, *Surg. Neurol.* 67 (2007) 413–417, <https://doi.org/10.1016/j.surneu.2006.07.015>.
- [5] R.C.S. Seet, E.C.H. Lim, Symptomatic segmental dystonia from a cavernous angioma in the centrum semiovale, *Parkinsonism Relat. Disord.* 11 (2005) 65–67, <https://doi.org/10.1016/j.parkreldis.2004.08.003>.
- [6] S. Felix, S. Thobois, L. Peter-Derex, Rapid eye movement sleep behaviour disorder symptomatic of a brain stem cavernoma, *J. Sleep Res.* 25 (2016) 211–215, <https://doi.org/10.1111/jsr.12364>.
- [7] H. Kanemoto, H. Kazui, T. Suehiro, H. Kishima, Y. Suzuki, S. Sato, et al., Apathy and right caudate perfusion in idiopathic normal pressure hydrocephalus: a case-control study, *Int. J. Geriatr. Psychiatry* 34 (2019) 453–462, <https://doi.org/10.1002/gps.5038>.
- [8] R. Levy, V. Czernecki, Apathy and the basal ganglia, *J. Neurol.* 253 (Suppl 7) (2006) VII54–61, <https://doi.org/10.1007/s00415-006-7012-5>.
- [9] A. Tran, M. Amin, R. Burns, The role of MRI and DaTscan in vascular parkinsonism: a case report [abstract], *Mov. Disord.* 32 (suppl 2) (2017).
- [10] K.-A. Chun, E. Kong, I. Cho, An incidental finding of skull hemangioma during 18F-FP CIT brain PET/CT, *Clin. Nucl. Med.* 40 (2015) e488–e489, <https://doi.org/10.1097/RLU.0000000000000907>.