

## INSTRUCTIVE CASE

**Ongoing sleep disruption in a 5-year-old child with cerebral palsy, cortical blindness and a history of pre-natal cerebral haemorrhage**Dennis Rosen <sup>1,2</sup><sup>1</sup>Division of Pulmonary Medicine, Boston Children's Hospital and <sup>2</sup>Harvard Medical School, Boston, Massachusetts, United States

A 5-year-old girl presented with her mother and nurse to the sleep medicine clinic because of difficulties initiating and maintaining sleep. She had a very complex medical history, including: spastic cerebral palsy, pre-natal cerebral haemorrhage involving the thalamus and hypothalamus; global developmental delay; cortical blindness; refractory epilepsy; temperature instability; pan-hypopituitarism; and diabetes insipidus.

The patient's mother and nurse reported that getting her to fall and stay asleep at night had been a struggle 'ever since she was a baby'. She was able to sleep in 6-h blocks at a time, but the timing of the sleep periods was variable. The mother had brought in sleep logs completed by herself, the patient's father and home nurses. These showed short periods of sleep lasting a few hours, as well as blocks of sleep lasting about 6 h, scattered seemingly randomly around the 24-h day. She was on several anti-epileptic medications, of which lacosamide seemed to induce sleep for varying lengths of time. There were some 24-h days when she had been noted as having been completely awake, and others when she had been noted as not having been awake at all.

The mother reported that putting her to bed when she was 'not ready to sleep' was destined to fail, irrespective of the hour. When the patient appeared sleepy, however, she would generally fall asleep quickly but then often awaken at seemingly random times, talking and screeching. There were nights where she would not sleep at all, and days in which she would appear to be completely asleep. The mother had given her melatonin a few

times to try and help her to sleep, but had not found this to be helpful. A sleep study performed a few months prior to this visit, apart from grossly abnormal electroencephalogram tracings, had appeared normal without evidence of sleep-disordered breathing or of excessive periodic limb movements of sleep.

Review of systems was notable for the above, and for the following: She is legally blind, with known optic atrophy and cortical blindness due to cerebral and thalamic damage caused by the pre-natal haemorrhage. The mother did, however, feel that she is able to see a little bit when gazing sideways. She does have a light box at home to stimulate visual capacity.

Upon examination, the patient was in no apparent distress, respiratory or otherwise. She was alert and responsive. Her colour was good, and there was no cyanosis, jaundice, oedema or clubbing of the extremities. She had a non-focused gaze. Remainder of the examination was normal.

The history suggested a non-24-h sleep-wake rhythm disorder. A trial of morning phototherapy, sleep- and medication-schedule modification and night-time melatonin was recommended.

The specific recommendations were as follows:

- 1 Keep to a fixed schedule, budgeting 8 h for night-time sleep and a 1–2 h nap in the early afternoon, both following lacosamide administration and at the same time (e.g. 10 pm–6 am and 12 pm–2 pm), 7 days a week.
- 2 Avoid sleeping outside of these sleep windows.
- 3 Reduce exposure to bright light 3 h before bedtime at night.
- 4 A dose of 3 mg melatonin to be given half an hour before bedtime.
- 5 Upon awakening her, the mother was instructed to place her in front of the light box for 30 min each morning, keeping it about 18–20 inches from her face.
- 6 The mother was asked to keep sleep charts and to return 1 month later to review the patient's progress and to discuss further steps.

One month later, the sleep patterns were notably better (Fig. 1). The child had been falling asleep between 10 and 11 pm almost every night, awakening for the most part between 6 and 8 am. Although the mother had not given her melatonin, because of her own poor experience with it, she had implemented the other recommendations.

**Diagnosis**

Non-24-h sleep-wake rhythm disorder.

**Key Points**

- 1 Although children with structural and functional abnormalities of the brain often have irregular sleep patterns and different sleep needs as compared to their neurotypical peers, it is important to seek out and identify potentially treatable causes.
- 2 Non-24-h sleep-wake rhythm disorder should be considered in these children, especially in the presence of significant visual impairment.
- 3 Phototherapy to entrain circadian rhythms may be successful even in significantly visually impaired children, and used in conjunction with sleep- and medication-schedule adjustments.

**Correspondence:** Dr Dennis Rosen, Division of Pulmonary Medicine, Boston Children's Hospital, 300 Longwood Avenue, Boston, MA 02115, USA. Fax: +1 617 730 0084; email: dennis.rosen@childrens.harvard.edu

Conflict of interest: None declared.

Accepted for publication 22 December 2019.

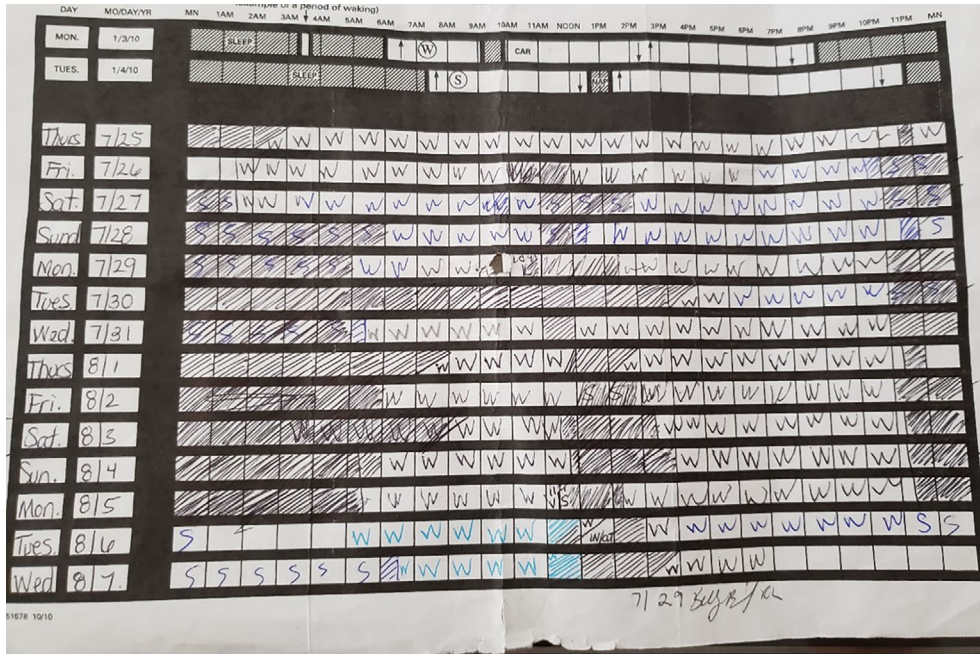


Fig. 1 Sleep charts following treatment.

**Discussion**

Sleep disturbances in children with developmental delay are very common,<sup>1</sup> and can be especially difficult for parents and other caregivers when these impact their own ability to sleep. In this patient, several factors contributed to the irregular sleep patterns, including a free-running circadian rhythm, variable sleep schedule and medication effect on her sleep (acosamide).

The two main drivers of sleep are the homeostatic, stemming from the amount of time sustained without sleep, and the circadian. Aligning the two is critical to establishing regular sleep patterns. The

homeostatic sleep drive can be manipulated by limiting the time available for sleep into discrete, age- and developmentally appropriate windows. The circadian sleep drive can be adjusted by adhering to a regular schedule; exposure to or avoidance of bright light at certain times of the 24-h day; and use of melatonin.

Non-24-h sleep-wake rhythm disorder is well-described in the visually impaired and blind, with one study finding a prevalence of 30% in children with optic nerve hypoplasia.<sup>2</sup> Because circadian rhythms typically run in cycles of slightly more than 24 h,<sup>3</sup> the lack of entrainment to the external clock can result in periods of sleep at progressively later and later time points (Fig. 2). In the




Fig. 2 Illustrative example of non-24-h sleep-wake rhythm disorder in a patient with a 25-h circadian sleep-wake cycle. Each line contains data for two 24-h days (48 h in total) to help visualise the effect of a progressive on-hour delay of the circadian sleep drive. Shaded boxes indicate a block of 8 h of sleep.

visually impaired, this often results from insufficient stimulation of the retino-thalamic tract (RTT). Although the RTT and the visual retino-cortical tract both emanate from the retina, their function and pathways are different. The RTT is comprised of intrinsically photosensitive retinal ganglion cells that terminate in the superchiasmatic nucleus, the location of the circadian pacemaker. Intrinsically photosensitive retinal ganglion cells may be stimulated even in the absence of cortical vision, and the absence of vision does not rule out the presence of an active, functioning, RTT.<sup>4</sup>

In this child, the use of melatonin was intended to ‘anchor’ her sleep onset in the evenings, and the exposure to bright light in the mornings was intended to do the same for her awakening. Keeping her on a regular schedule was intended to fortify a regular circadian sleep–wake cycle, and to regulate her homeostatic sleep drive. Not letting her sleep outside of the defined windows for sleep, and accommodating the dosing of her lacosamide to facilitate sleep onset within those windows was also intended to regulate her homeostatic sleep drive. By regulating both sleep drives, it was hoped that her sleep pressure would be stronger at specific and regular times across the

24-h day (bedtime and naptime), thus enabling her to develop more regular sleep patterns. In the end, even without the use of melatonin, the exposure to bright light at the same time each morning, maintenance of a regular schedule and adjustment of the scheduled dosing of her lacosamide, proved successful in regulating her sleep patterns.

## References

- 1 Lelis AL, Cardoso MV, Hall W. Sleep disorders in children with cerebral palsy: An integrative review. *Sleep Med. Rev.* 2016; **30**: 63–71.
- 2 Rivkees SA, Fink C, Nelson M, Borchert M. Prevalence and risk factors for disrupted circadian rhythmicity in children with optic nerve dysplasia. *Br. J. Ophthalmol.* 2010; **94**: 1358–62.
- 3 American Academy of Sleep Medicine. Circadian rhythm sleep-wake disorders. In: *International Classification of Sleep Disorders*, 3rd edn. Darien, IL: The Academy; 2014; 189–224.
- 4 Nishimon S, Nishimon M, Nishino S. Tasimelteon for treating non-24-h sleep-wake rhythm disorder. *Expert Opin. Pharmacother.* 2019; **20**: 1065–73.