

Case Report

Early and delayed neurological manifestations of cardiac myxomas

Leonidas D. Panos^{a,*}, Christophe Brunel^b, Sabina Berezowska^c, Renate Englisch^{d,1}, Attila Kollar^e, Claudio Bassetti^a, Mathias Sturzenegger^a, Heinz Krestel^{a,*}

^a Departments of Neurology, Institute of Diagnostic and Interventional Neuroradiology, Bern University Hospital and University of Bern, Bern, Switzerland

^b Institute of Pathology, University Hospital Center and University of Lausanne, Lausanne, Switzerland

^c Institute of Pathology, University of Bern, Bern, Switzerland

^d Diagnostic and Interventional Neuroradiology, Bern University Hospital and University of Bern, Bern, Switzerland

^e Departments of Oncology, Institute of Diagnostic and Interventional Neuroradiology, Bern University Hospital and University of Bern, Bern, Switzerland

ARTICLE INFO

Keywords:

Myxoma
Stellate cells
Fusiform aneurysm
CRP
Radiotherapy

ABSTRACT

Cardiac myxoma can embolize and cause early and delayed sequelae including stroke, growth into intracranial fusiform aneurysms and cerebral tumors with risk of hemorrhage and mass effect. Here, we report the rare coincidence of all these manifestations in a 63-year-old man who presented with cognitive and behavioral changes, and seizures 9 months after an embolic stroke from the heart tumor. C-reactive protein (CRP) was elevated at the time of stroke and cardiac myxoma diagnosis but was normal at late neurologic manifestation with isolated myxoma-related intracranial tumors and aneurysms. Low-dose whole-brain radiotherapy can be helpful to diminish cerebral myxoma tumors and fusiform aneurysms despite reported increased risk of aneurysm rupture.

1. Introduction

Myxoma is the most common primary cardiac neoplasm with ~ 0.05 % prevalence and female preponderance [1,2]. Cardiac myxoma may manifest with heart-associated complaints (60 %), fever and weight loss, elevation of C-reactive protein (CRP) or erythrocyte sedimentation rate (ESR) (30 %) [2]. Extracardiac tumor embolization occurs in 12–30 % [3], and can cause cerebral neurological complications in up to a third of the cases [4,5] including ischemic (embolic) stroke, fusiform aneurysm formation and cerebral tumor growth. The frequently used terms “metastatic myxoma” or “invasive metastatic myxomatous masses” are inappropriate, as cardiac myxoma with its prevalent origin in the left atrium already has access to the blood circulation, which a solid malignant neoplasm typically has to enforce. Second, the bloodstream can carry away tumor particles due to myxoma’s brittle nature. Third, after translocation into distant sites, mitotically active myxoma emboli can continue to grow, which does not correspond to true malignant infiltration. In case of myxoma-related embolic stroke, successful treatment with thrombolysis and/or mechanical recanalization was reported [6]. Neurological long-term prognosis frequently depends on the time between cardiac myxoma identification and intracranial embolus manifestation. In the present

case, we discuss diagnosis, treatment and follow-up of the rare coincidence of all neurological myxoma manifestations.

2. Case report

A 63-year-old man was admitted to our emergency department because of a generalized tonic-clonic seizure. The patient showed dysarthria (slurred non-harmonic speech) as well as non-fluent slowed partial aphasia with semantic paraphasia, and global cognitive deficits in the bedside Montreal Cognitive Assessment (13/30 points). There were no sensorimotor deficits. CRP was normal.

A year ago, the patient had suffered an ischemic stroke involving the territory of the left sylvian artery with global aphasia. A cerebral CT scan with angiography had revealed a stenosis in the M1-M2 segment of the left middle cerebral artery (MCA) and a perfusion deficit in the posterior two-thirds of the left MCA territory. No thrombolysis had been performed. No focus of infection had been identified in the afebrile patient, although blood analyses had shown evidence for inflammation (CRP: 63 mg/l (norm < 3)). A tumor (7 × 3 cm, 2.8 × 1.2 in. attached to the left interatrial septum had been identified, removed, and diagnosed as cardiac myxoma. Transthoracic echocardiography and a cerebral CT scan a week later had shown no pathologies. Prior to

* Corresponding authors at: Department of Neurology, Bern University Hospital and University of Bern, Freiburgstrasse 8, 3010 Bern, Switzerland.

E-mail addresses: Leonidas.panos@insel.ch (L.D. Panos), heinz.krestel@insel.ch (H. Krestel).

¹ Current address: Dept. of Radiology, Kantonsspital Luzerne, Sursee, Switzerland.

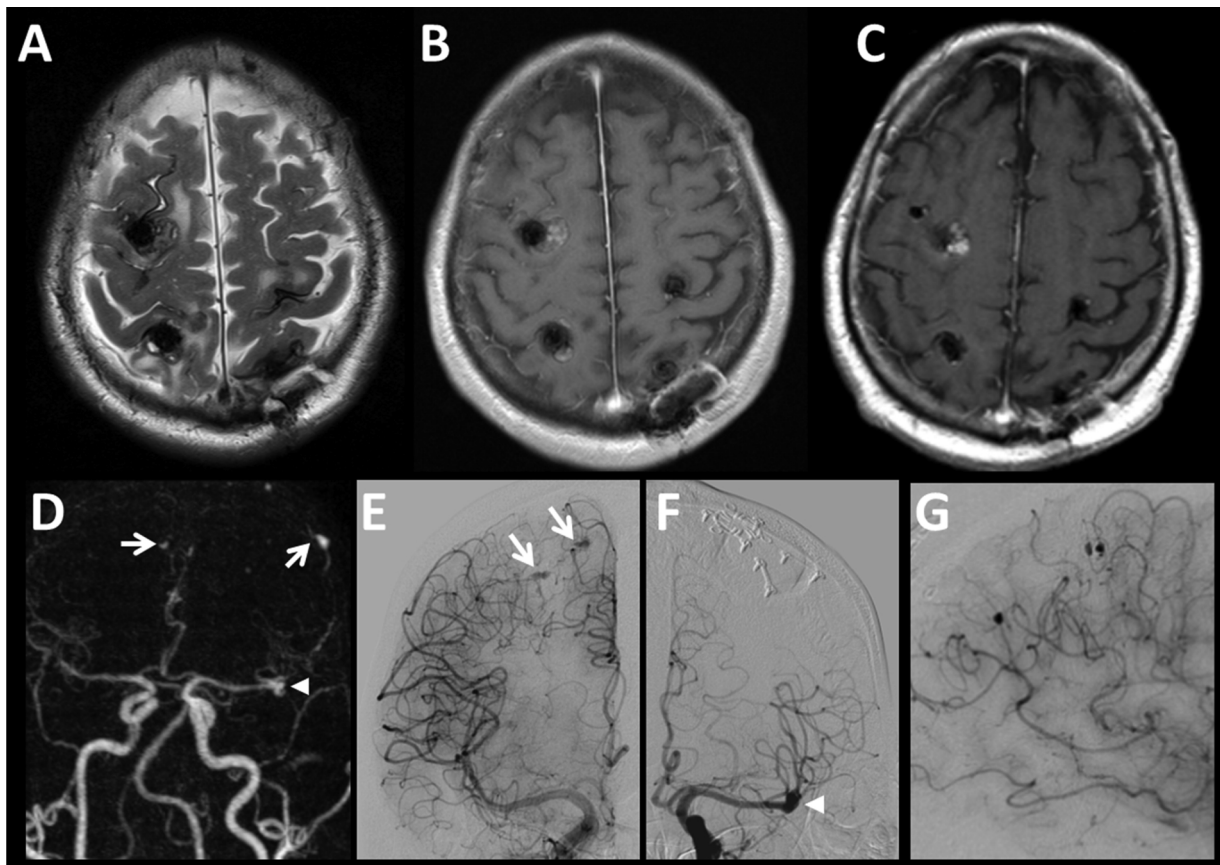


Fig. 1. Initial MRI showing multiple hemorrhagic cerebral focal lesions in both cerebral hemispheres accompanied by perifocal edema on T2- (A), and hemorrhage of various age but no definite contrast enhancement on T1-weighted (B) MRI images. Post-contrast MRI (C) after radiotherapy and 3 months after diagnosis revealed beginning regression of the lesions. Contrast enhanced MR-angiography (D) documented an ectatic M2-segment of the left MCA (arrowhead) and small intra- and extracranial aneurysms (arrows). Digital subtraction angiography revealed distal neoplastic aneurysms (arrows) in the late arterial phase of the right internal carotid injection series (E) and a dysplastic ectatic M2-segment (arrowhead) in the left internal carotid injection series (F). (G) Close-up lateral view of the peripheral neoplastic aneurysms – right internal carotid injection.

discharge, CRP had remained elevated and secondary stroke prophylaxis with aspirin had been initiated.

Several months prior to admission to our hospital, a progressive personality change with irritability and aggressiveness and a first focal motor seizure of the right arm were reported. Antiepileptic drug (AED) therapy with levetiracetam (20 mg/kg/d with reduction over time to 10 mg/kg/d because of impaired motivation and tiredness) was begun. Subsequently, the patient was admitted to a local emergency department because of flashes in his left visual field. Cerebral magnetic resonance imaging (MRI) demonstrated multiple supra- and infratentorial lesions with partial hemorrhagic transformation and gadolinium enhancement (Fig. 1A and B). MR-angiography showed ectasias of extra- and intracranial arteries (Fig. 1D). Dermatological examination, thoraco-abdomino-pelvic CT, positron emission tomography, transthoracic echocardiography, lumbar puncture (cytology and flow cytometry), and biopsy of a scalp nodule could not detect a primary neoplasm. Subsequent stereotactic brain biopsy of a left parieto-occipital lesion was performed. The histology was interpreted as inflammatory changes. The patient was treated with dexamethasone (4 mg/d).

During hospitalization in our neurology department, another MRI scan showed an unchanged intracranial picture. Digital subtraction angiography revealed multiple fusiform aneurysms of peripheral intra- and extracranial arteries and a dysplastic fusiform dilatation of the left MCA bifurcation and M2 segment (Fig. 1E–G). Transesophageal echocardiography and cardiac MRI showed no myxoma recurrence. Histological reevaluation of the same brain biopsy revealed intracerebral myxoma emboli, obscured by extensive hemorrhagic and inflammatory

changes (Fig. 2B). Confounding inflammatory changes were not present to this extent in the primary cardiac location (Fig. 2A). The patient was treated with fractionated whole-brain radiotherapy (10 cycles of 3 Gy) that was well tolerated. Levetiracetam was switched to lamotrigine (target dose 3.5 mg/kg/d), quetiapine (0.3 mg/kg/d) was added, and dexamethasone was phased out. Three months later the patient was readmitted because of 5 generalized seizures. Follow-up MRI showed regression of the masses and aneurysms and no new hemorrhaging (Fig. 1C). We increased lamotrigine (to 4 mg/kg/d) and added gabapentin (12.5 mg/kg/d). No further seizures were reported on follow-ups for the next three years and the patient's clinical status ameliorated gradually. Then, a progression of the dilatation of the left MCA without bleeding was documented in a brain CT scan. Digital subtraction angiography confirmed progression of that aneurysm and showed evidence for new aneurysms in peripheral intracranial arteries, as well as complete remission of several older ones. Transthoracic echocardiography was negative for myxoma recurrence. It was decided for clinical observation and tight follow-ups, because the patient was asymptomatic and in good health and physical condition.

3. Discussion

We retrospectively assume that cerebral embolization occurred around the time of the ischemic stroke, subsequently to which cardiac myxoma was detected; and that stroke was caused by a stenosis in the left MCA bifurcation due to myxoma embolism, because evidence for cardiac myxoma recurrence later on was missing. Neuroradiologic

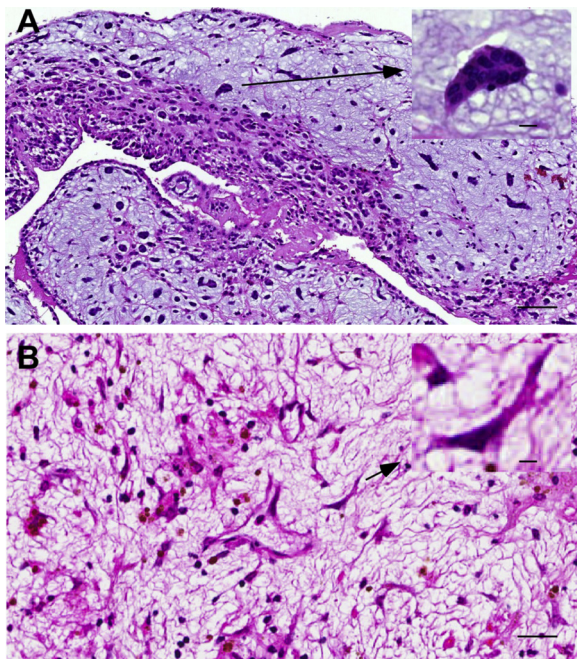


Fig. 2. Hematoxyline and eosine stained histological sections of the biopsies from heart and brain. A) The atrial tumor was of myxoid appearance, with hemorrhagic and cystic degeneration areas. The stellate cells with round, hyperchromatic nuclei and scant, eosinophilic cytoplasm in a myxoid matrix are typical for myxoma (insert). B) Overview of cerebral biopsy showing stellate myxoma cells (insert) and extensive regressive changes with inflammation and signs of hemorrhage. Insert: myxomatous stellate cell. Scale bar, 100 μ m.

findings of a fusiform dilatation of the left MCA bifurcation at the location where 9 months earlier a stenosis was found, together with the appearance of multiple cerebral tumors, suggest a fair amount of proliferative activity of the patient's myxoma emboli. For comparison, delayed neurological symptoms manifested themselves up to 14–18 years after cardiac myxoma diagnosis in other cases [7,8].

We assume a progressive invasion of the embolized myxoma cells into the arterial wall, leading at the beginning to a vessel occlusion with gradual weakening of the wall and subsequent aneurysm formation. As next step, the myxoma cells can grow through the arterial wall into the cerebral parenchyma causing intracerebral masses. As myxoma has been associated with inflammation, inflammatory markers could be used as biomarkers. Indeed, elevated CRP has been reported in conjunction with cardiac myxoma in the absence or presence of embolic stroke (e.g. [9,10], this report). Interleukin 6 (IL-6), a pro-inflammatory cytokine and myokine, produced and secreted by cardiac myxoma cells, may quickly decrease after myxoma surgical removal and was suggested as marker for cardiac myxoma recurrence [11–13]. We did not assess IL-6 in our patient. It is unknown whether elevated inflammatory markers are associated with delayed neurological manifestations in the absence of cardiac myxoma recurrence. Our patient had normal CRP in spite of myxoma-related intracerebral tumors and aneurysms. Further research is needed whether acute phase proteins or cytokines could be applied as “tumor markers” to support timely diagnosis of delayed neurological manifestations.

Treatment of early neurological manifestations including embolic stroke with thrombolytic agents was reviewed in case reports of altogether 23 patients [6]. In 13 out of 20 patients, intravenous/intra-arterial thrombolysis improved outcome, by lowering NIHSS by ≥ 4 points. Intravenous thrombolysis plus mechanical thrombectomy was not able to improve outcome in 3 patients. The lack of improvement might be explained by the low number of patients studied and the higher NIHSS upon arrival. Hemorrhage was observed in 5 out of 16 patients with intravenous thrombolysis only. None of the 5 patients had

significantly worse outcome, i.e. a NIHSS increase by ≥ 4 points.

Treatment of delayed neurological manifestations, i.e. cerebral myxoma-related tumors and aneurysms, includes chemo- and radiotherapy, tumor surgery, and aneurysm clipping or coiling. Data on the efficacy of systemic treatment (e.g. doxorubicin, ifosfamide) in cardiac myxoma are scant [9,14,15]. We decided for fractionated whole-brain radiotherapy with 30 Gy because of the multitude of lesions and the known sensitivity of myxoma towards radiotherapy [9,10,16]. Most aneurysms remitted shortly after radiotherapy and no cerebral hemorrhage or any other major complication was detected for the next 3 years. Our finding indicates a successful and safe approach, despite a theoretically increased risk of aneurysm rupture due to potential additional vessel wall weakening by radiotherapy [17,18]. The elimination of the myxoma cells might outweigh the damaging effect of radiation therapy on the vessel wall structure. This finding however needs to be corroborated by further studies. The reason, why in the long-term follow-up the left MCA dilatation progressed and new small peripheral aneurysms appeared, remains unclear. Transthoracic echocardiography did not show cardiac myxoma relapse and thus cardiac embolization is unlikely. Remission of several pre-existing intracranial aneurysms and appearance of new ones, together with high mitotic myxoma activity argue relatively against radiotherapy-induced and more for myxoma-related aneurysm growth. This assumption is supported by the shape of the new aneurysms, which is fusiform, in contrast to radiation-related aneurysms that frequently have saccular appearance [17]. It thus appears that radiotherapy was of temporary benefit to our patient. Whole-brain radiotherapy had to be applied in this case because of the multitude of lesions. In case of a lower lesion load, Cyberknife radiation or radiotherapy with hippocampal sparing could be applied, which is associated with a better cognitive outcome. As a final note, the role of immunotherapy is unexplored and could prove promising, as myxoma is associated with inflammation (e.g. [13].), and spontaneous remission of myxoma-related aneurysms was reported [19].

This case represents a possible advance in the therapy of cerebral embolization of cardiac myxoma, taking into consideration that there is only one case in the literature, [16] in which myxoma-related cerebral aneurysms were treated with whole-brain radiotherapy, whereby they were irradiated with higher dose (46 Gy) and the patient was followed-up for a shorter time (1 year, with stable size of aneurysms). Furthermore, there are only two cases [9,10], in which cerebral myxoma-related tumors without concomitant aneurysms were safely treated with radiotherapy (30 Gy/40,8 Gy) with a stable course (4 years follow-up in one case). In a fourth patient, myxoma-related cerebral tumors were treated with radio- (5000 Gy) and chemotherapy (doxorubicin, ifosfamide) with a favorable course during 10 years of follow-up [14]. No case was as yet reported with combined cerebral myxoma-related tumors and aneurysms and whole-brain radiotherapy. Further studies have to verify safety and efficacy of radiotherapy in a long-term follow-up. A systemic inflammatory reaction might be associated with cardiac myxoma and early neurological manifestations, but we find no evidence for elevated CRP with delayed intracranial myxoma growth in the absence of cardiac myxoma recurrence in our case.

Ethical standard

The case report complies with ethical/GCP standards of the Swiss Cantonal Ethics Committee Bern and the Declaration of Helsinki.

Informed consent

Written informed consent was obtained from the patient.

Declaration of Competing Interest

None.

Acknowledgements

The authors would like to thank the patient and his family, as well as Patrick Y. Wen M.D., Professor of Neurology, Harvard Medical School, Director, Center for Neuro-Oncology, Dana-Farber Cancer Institute, Boston, Massachusetts, USA for consultative advice concerning myxoma treatment.

References

- [1] W.D. Travis, E. Brambilla, A.P. Burke, et al., Introduction to the 2015 world health organization classification of tumors of the lung, pleura, thymus, and heart, *J. Thorac. Oncol.* 10 (2015) 1240–1242.
- [2] I. Badrissyah, R. Saiful, H. Rahmat, et al., Brain metastasis of atrial myxoma: case report, *Med. J. Malaysia* 67 (2012) 613–615.
- [3] T. Chacon-Quesada, A. Maud, T.J. O'Neill, et al., "Metastatic" embolic lesions and enlarging pseudoaneurysms associated with cardiac myxoma, *Neurol. Clin. Pract.* 5 (2015) 171–174.
- [4] H.P. Mattle, D. Maurer, M. Sturzenegger, et al., Cardiac myxomas: a long term study, *J. Neurol.* 242 (1995) 689–694.
- [5] V.H. Lee, H.M. Connolly, R.D. Brown Jr., Central nervous system manifestations of cardiac myxoma, *Arch. Neurol.* 64 (2007) 1115–1120.
- [6] M. Acampa, F. Guideri, R. Tassi, et al., Thrombolytic treatment of cardiac myxoma-induced ischemic stroke: a review, *Curr. Drug Saf.* 9 (2014) 83–88.
- [7] A. Santillan, D. Sigounas, M.E. Fink, et al., Multiple fusiform intracranial aneurysms 14 years after atrial myxoma resection, *Arch. Neurol.* 69 (2012) 1204–1205.
- [8] A. Santillan, J. Knopman, A. Patsalides, et al., Delayed intracranial aneurysm formation after cardiac myxoma resection: report of two cases and review of the literature, *Interv. Neuroradiol.* 25 (2019) 177–181.
- [9] M.B. Altundag, G. Ertas, A.R. Ucer, et al., Brain metastasis of cardiac myxoma: case report and review of the literature, *J. Neurooncol.* 75 (2005) 181–184.
- [10] B. Kierdaszuk, P. Gogol, A. Kolasa, et al., Multiple metastatic intracranial lesions associated with left atrial myxoma, *Pol. J. Radiol.* 79 (2014) 262–267.
- [11] J. Zhang, C. Wang, Xu H. miR-217 suppresses proliferation and promotes apoptosis in cardiac myxoma by targeting Interleukin-6, *Biochem. Biophys. Res. Commun.* 490 (2017) 713–718.
- [12] J.N. Lin, C.H. Lai, L.F. Lu, et al., Fever of unknown origin from a left atrial myxoma: an immunologic basis and cytokine association, *South. Med. J.* 104 (2011) 360–362.
- [13] Y. Maze, M. Kajimoto, H. Tenpaku, et al., Left atrial myxoma with severe inflammatory response, *Jpn. J. Thorac. Cardiovasc. Surg.* 52 (2004) 221–223.
- [14] F. Bernet, P.M. Stulz, T.P. Carrel, Long-term remission after resection, chemotherapy, and irradiation of a metastatic myxoma, *Ann. Thorac. Surg.* 66 (1998) 1791–1792.
- [15] R. Suzuki, T. Watanabe, R. Hirayama, et al., Case with cardiac myxoma causing cerebral metastasis after cardiac tumor resection, *Kyobu Geka* 61 (2008) 456–459.
- [16] J. Sedat, Y. Chau, A. Dunac, et al., Multiple cerebral aneurysms caused by cardiac myxoma. A case report and present state of knowledge, *Interv. Neuroradiol.* 13 (2007) 179–184.
- [17] A.D. Nanney 3rd, N.E. El Tecle, T.Y. El Ahmadi, et al., Intracranial aneurysms in previously irradiated fields: literature review and case report, *World Neurosurg.* 81 (2014) 511–519.
- [18] E. Ducasse, C. Creusy, J. Mazurier, et al., Morphometric and histological changes in the vascular wall after external radiation for the prevention of intimal hyperplasia, *J. Surg. Res.* 117 (2004) 316–322.
- [19] P.L. Flores, F. Haglund, P. Bhogal, et al., The dynamic natural history of cerebral aneurysms from cardiac myxomas: a review of the natural history of myxomatous aneurysms, *Interv. Neuroradiol.* 24 (2018) 277–283.