

Journal Pre-proof

Refractory epilepsy associated with anti-ribosomal P antibodies successfully treated with topiramate

R. Uribe San-Martín, E. Ciampi, J.P. Cruz, C. Cárcamo



PII: S0165-5728(19)30533-8

DOI: <https://doi.org/10.1016/j.jneuroim.2020.577144>

Reference: JN1 577144

To appear in: *Journal of Neuroimmunology*

Received date: 15 October 2019

Revised date: 3 January 2020

Accepted date: 6 January 2020

Please cite this article as: R. Uribe San-Martín, E. Ciampi, J.P. Cruz, et al., Refractory epilepsy associated with anti-ribosomal P antibodies successfully treated with topiramate, *Journal of Neuroimmunology* (2019), <https://doi.org/10.1016/j.jneuroim.2020.577144>

This is a PDF file of an article that has undergone enhancements after acceptance, such as the addition of a cover page and metadata, and formatting for readability, but it is not yet the definitive version of record. This version will undergo additional copyediting, typesetting and review before it is published in its final form, but we are providing this version to give early visibility of the article. Please note that, during the production process, errors may be discovered which could affect the content, and all legal disclaimers that apply to the journal pertain.

© 2019 Published by Elsevier.

Refractory Epilepsy associated with anti-ribosomal P antibodies successfully treated with Topiramate

Uribe San-Martín R.^{1,2*} reinaldouribe@gmail.com, Ciampi E.^{1,2}, Cruz JP.³, Cárcamo C.²

¹Neurology Service, Hospital Dr. Sótero del Río. Santiago.

²Neurology Department, Pontificia Universidad Católica de Chile. Santiago.

³Neuroradiology Department, Pontificia Universidad Católica de Chile. Santiago.

*Corresponding author at: Reinaldo Uribe San Martín, Neurology Department, Pontificia Universidad Católica de Chile, Marcoleta 352, second floor, Neurology Laboratory, Santiago; Neurology Service, Complejo Asistencial Hospital Sótero del Río, Chile.

Abstract

We report the case of a 25-year-old woman who developed **temporal lobe epilepsy** associated with systemic lupus erythematosus (SLE). Serum and cerebrospinal fluid samples showed high titers of anti-ribosomal P (anti-P) antibodies with negative anti-NMDAR antibodies. She was receiving prednisone and azathioprine, with normalization of SLE serum markers, but without changes in titer of anti-P antibodies. No seizure control was achieved using valproic acid, levetiracetam and lamotrigine. However, she had a selective response to topiramate, an AMPAR blocker, maintained during 6 years of follow-up. We discuss the pathophysiology of this autoimmune epilepsy associated with high titer anti-P antibodies.

Keywords: Anti-ribosomal P antibodies; Autoimmune epilepsy; Refractory epilepsy; Systemic Lupus Erythematosus; Neuroimmunology

1. Introduction

Anti-ribosomal protein P (anti-P) antibodies, described three to four decades ago, have been strongly associated with neuropsychiatric symptoms in patients with systemic lupus erythematosus (SLE) (Bonfa et al., 1987). Initially, anti-P antibodies seem to recognize terminal-carboxy-residues of three ribosomal phosphoproteins, P0 (38 kD), P1 (19 kD), and P2 (17 kD) (Elkon et al., 1986). However, it has been described in mouse models that the neurons of the dentate gyrus and CA1 but not CA3, express surface antigens that are also recognized by anti-P antibodies. These antibodies affect the postsynaptic transmission increasing the activity of AMPA and NMDA receptors, altering the long-term potentiation (Segovia-Miranda et al., 2015). This particular mechanism, could be epileptogenic and lead to the appearance of epileptiform discharges in patients with SLE. On the other hand, one of the several mechanisms of action of topiramate is to inhibit glutamatergic synaptic activity, in particular by blocking AMPA (α -amino - 3 - hydroxy - 5 -

methylisoxazole - 4 - propionic acid) / kainate glutamate receptors (Shank et al., 2000), and might be useful in this scenario. We report and discuss the pathophysiology of seizures associated with high titer of anti-P antibodies in a patient with refractory temporal lobe epilepsy and SLE successfully treated with topiramate.

2. Case report

We received a 25 years old female patient for pre-surgical evaluation of refractory epilepsy. She was diagnosed with SLE two years before because of skin rash and arthritis, with positive anti-DNA antibodies (32 U/mL, range 0-15), and low C'3 (62.3 mg/dL range 70-150) and C'4 (7.3 mg/dL range 15-45). She had negative anti-nuclear antibodies (ANA), anti-RO, anti-RNP, anti-SM, anti-LA, anti-SCL-70, anti-JO-1, hepa-2 glycoprotein 1, lupus anticoagulant, and anticardiolipin antibodies. High titers of anti-P were found in serum (199.7 U/mL, range 0-25) and cerebrospinal fluid (positive in a qualitative test). No pleocytosis, oligoclonal bands or elevated IgG index were observed in the cerebrospinal fluid. The patient had acute cutaneous lupus (5 points), joint involvement (6 points), anti-DNA antibody (6 points), low C3-C4 (4 points), and seizures (6 points) from the ACR/EULAR classification (Aringer et al. 2019). By the time of the first assessment in our centre, she was receiving treatment with oral prednisone (5 mg QD) and azathioprine (150 mg QD), with normalization of anti-DNA antibodies and C'3 and C'4 measurements. Prednisone and azathioprine were progressively changed to hydroxychloroquine (200 mg QD). However, she had persistent positive anti-P titers, similar to those described at diagnosis (serum: 110 U/mL). She had a neuropsychological assessment showing only mild visual episodic memory deficits that recovered by the 6 and 12-month evaluation. We also performed anti-NMDA receptor antibodies which were negative. No other panels for autoimmune encephalitis were accessible at that time in our country, and the patient was unable to cost any other studies available in research labs. Infectious diseases work-up including syphilis and human immunodeficiency virus were negative. Since her SLE diagnosis, she presented 1 to 10 focal seizures per month, characterized by sudden cacoscopia, dysgeusia and frequently followed by epigastralgia, autoscopy and focal seizure with impaired awareness for 1-2 minutes. She was already being treated with several regimens of antiepileptic drugs such as valproic acid (250 mg TID), levetiracetam (1500 mg BID), lamotrigine (50 mg per day, suspended by a rash), remaining refractory. We performed a long-term scalp electroencephalogram (EEG) monitoring (24 hours) that showed right frontotemporal spikes discharges (Figure 1.A.) and her magnetic resonance

images showed abnormal increased T2 signal and mildly increased volume of the right temporal amygdala and head of the hippocampus without abnormal gadolinium enhancement (Figure 1.B.i).

Reviewing the pathophysiological mechanisms described in animal models, which suggest that anti-P antibodies increase synaptic glutamatergic activity, we decided to start treatment with topiramate 100 mg BID, reaching immediate seizure response (Figure 1.C.).

The patient remained without seizures, except for a focal seizure with impaired awareness followed by bilateral spreading that occurred after stopping the topiramate for 1 week at the fifth year of treatment (*, Figure 1.C.).

At the sixth year of follow-up, we monitored her cerebral MRI, which has remained without significant changes (Figure B.ii, iii, iv), without signs of hippocampal body atrophy and no cortical developmental anomalies were seen in the temporal lobe. Her SLE markers remain negative but maintaining the serum high titer of anti-P antibodies (105.3 U/mL). The patient gave her informed consent for the presentation of this case.

3. Discussion

Although anti-P antibodies have been historically associated with psychosis, cognitive and affective disorders in SLE patients, one meta-analysis found that in patients whose manifestation of neuropsychiatric SLE was seizures, the presence of positive serum anti-P antibodies was 8 times more frequent than the 4 to 5 times observed in patients with psychosis or depression. Furthermore, the prevalence of positive titers of anti-P antibodies in cerebrospinal fluid increased up to 45 times over anti-neuronal antibodies and was found 10 times more frequently in the same epilepsy patients (Ho et al., 2016).

Recently, a study using rat models and electro-oscillogram showed that the intraventricular injection of IgG fraction of anti-P positive and affinity-purified anti-P antibodies provoke an increase in polyspikes, diffusely distributed in hippocampal fields and cerebral cortex. These abnormalities were antibody-specific and persistent for about a month, is associated with behavioural disorders with varying degrees of severity in every animal injected (Gaburo et al., 2017).

These descriptions are in line with the pathophysiological findings of Segovia-Miranda et al. who found that affinity-purified anti-P increased the field excitatory postsynaptic potential in the dorsal hippocampus of mice and that anti-P antibodies increased the amplitude of spontaneous AMPAR-mediated currents in primary spinal cord neurons

recorded in the whole-cell patch-clamp, in a dose-dependent way. For these reasons, we decided to start antiepileptic treatment with topiramate, which most important mechanism of action consists in blocking the AMPA receptor, producing a fast and complete resolution of seizures in our patient. The selectivity of topiramate is noteworthy, as when the patient suspended the treatment for 1 week, seizures recurred, with rapid cessation after restart of the antiepileptic drug. Nonetheless, one should be cautious in the interpretation of this observation, as stopping any AED on which a patient's seizures are well controlled could lead to the resurgence of seizures and/or status epilepticus.

From the immunotherapy point of view, the early response of clinical rheumatological signs (skin and joint involvement) and normalization of serological markers, associated with the persistence of high titer anti-P and stable abnormalities observed in follow-up MRI, difficult the assessment of the patient's SLE treatment. As her epilepsy successfully respond to topiramate, no changes in her immunotherapy regimen were proposed. Nonetheless, high dose intravenous methylprednisolone, immunoglobulins or plasma exchange, could also have been suitable options for treating her refractory autoimmune epilepsy, possibly reducing circulating antibodies.

Perhaps, seizure relapse will be the only clinical indicator of reactivation of her SLE. According to the 2019 recommendations, mycophenolate should be avoided, while aggressive treatment with cyclophosphamide or off-label rituximab may be considered in case of breakthrough disease (Fano-Ortakakis et al. 2019).

Finally, it is important to note that seizures are common among SLE patients, not only as a neuro-SLE manifestation but even as a complication of systemic compromise (e.g. acute electrolyte disturbances, renal failure, posterior reversible encephalopathy syndrome, etc.) so, although phenytoin and other antiepileptic drugs such as carbamazepine and lamotrigine have been associated with drug-induced lupus and are unlikely to affect SLE disease course, chronic use may provoke uncertainty in determining SLE stability, and treatment schedules should be carefully chosen in each patient (Chang et al, 2014).

4. Conclusion

The approach to patients with drug-resistant focal epilepsy, defined as the correct use of two antiepileptic drugs (as monotherapy or combination therapy) with no resolution of seizures (Kwan et al., 2010), has been centred in the surgical resection of the probable epileptogenic zone. However, the understanding of the underlying pathophysiological mechanisms involved in the individual patient can allow the establishment of the most

appropriate therapeutic intervention, aiming for more personalized and precise medicine in the near future (Kearney et al., 2019). This case report provides a plausible link between the patient's anti-P antibodies and refractory epilepsy due to response to topiramate but would require further investigation in a bigger cohort of patients.

Declaration of Competing Interest

None.

References

Aringer M, Costenbader K, Daikh D, Brinks R, Mosca M, Ramsey Goldman R, Smolen JS, Wofsy D, Boumpas DT, Kamen DL, Jayne D, Cervera R, Costedoat-Chalumeau N, Diamond B, Gladman DD, Hahn B, Hiepe F, Jacobsen S, Khanna D, Lerstrøm K, Massarotti E, McCune J, Ruiz-Irastorza G, Sanchez-Cuervo J, Schneider M, Urowitz M, Bertsias G, Hoyer BF, Leuchten N, Tani C, Tedeschi SK, Touma Z, Schmajuk G, Anic B, Assan F, Chan TM, Clarke AE, Crow MK, Czirjak L, Doria A, Graninger W, Halda-Kiss B, Hasni S, Izmirly PM, Jung M, Kumánovics G, Mariette X, Padjen I, Pego-Reigosa JM, Romero-Diaz J, Rúa-Figueroa Fernández Í, Seror R, Stummvoll GH, Tanaka Y, Tektonidou MG, Vasconcelos C, Vital EM, Wallace DJ, Yavuz S, Meroni PL, Fritzler MJ, Naden R, Dörner T, Johnson SR. 2019 European League Against Rheumatism/American College of Rheumatology classification criteria for systemic lupus erythematosus. *Ann Rheum Dis*. 2019;78(9):1151-1159.

Bonfa E, Golombek G, Kaufman LD, Skelly S, Weissbach H, Brot N, Elkon KB. Association between lupus psychosis and anti-ribosomal P protein antibodies. *N Engl J Med*. 1987;317(5):265-71.

Chang RS, Cole AJ. Lamotrigine-induced lupus-like syndrome: a case report and literature review. *Am J Ther*. 2014;21(3):e85-7.

Elkon K, Skelly S, Parnassa A, Moller W, Danho W, Weissbach H, Brot N. Identification and chemical synthesis of a ribosomal protein antigenic determinant in systemic lupus erythematosus. *Proc Natl Acad Sci USA*. 1986;83(19):7419-23.

Fanouriakis A, Kostopoulou M, Alunno A, Aringer M, Bajema I, Boletis JN, Cervera R, Doria A, Gordon C, Govoni M, Houssiau F, Jayne D, Kouloumas M, Kuhn A, Larsen JL, Lerstrøm K, Moroni G, Mosca M, Schneider M, Smolen JS, Svenungsson E, Tesar V, Tincani A, Troldborg A, van Vollenhoven R, Wenzel J, Bertsias G, Boumpas DT. 2019 update of the EULAR recommendations for the management of systemic lupus erythematosus. *Ann Rheum Dis.* 2019;78(6):736-745.

Gaburo N Jr, de Carvalho JF, Timo-Iaria C In Memoriam, Bueno C, Reichlin M, Viana VS, Bonfá E. Electrophysiological dysfunction induced by anti-ribosomal P protein antibodies injection into the lateral ventricle of the rat brain. *Lupus.* 2017;26:463-469.

Ho RC, Thiaghu C, Ong H, Lu Y, Ho CS, Tam WW, Zhang MV. A meta-analysis of serum and cerebrospinal fluid autoantibodies in neuropsychiatric systemic lupus erythematosus. *Autoimmun Rev.* 2016;15:124-38.

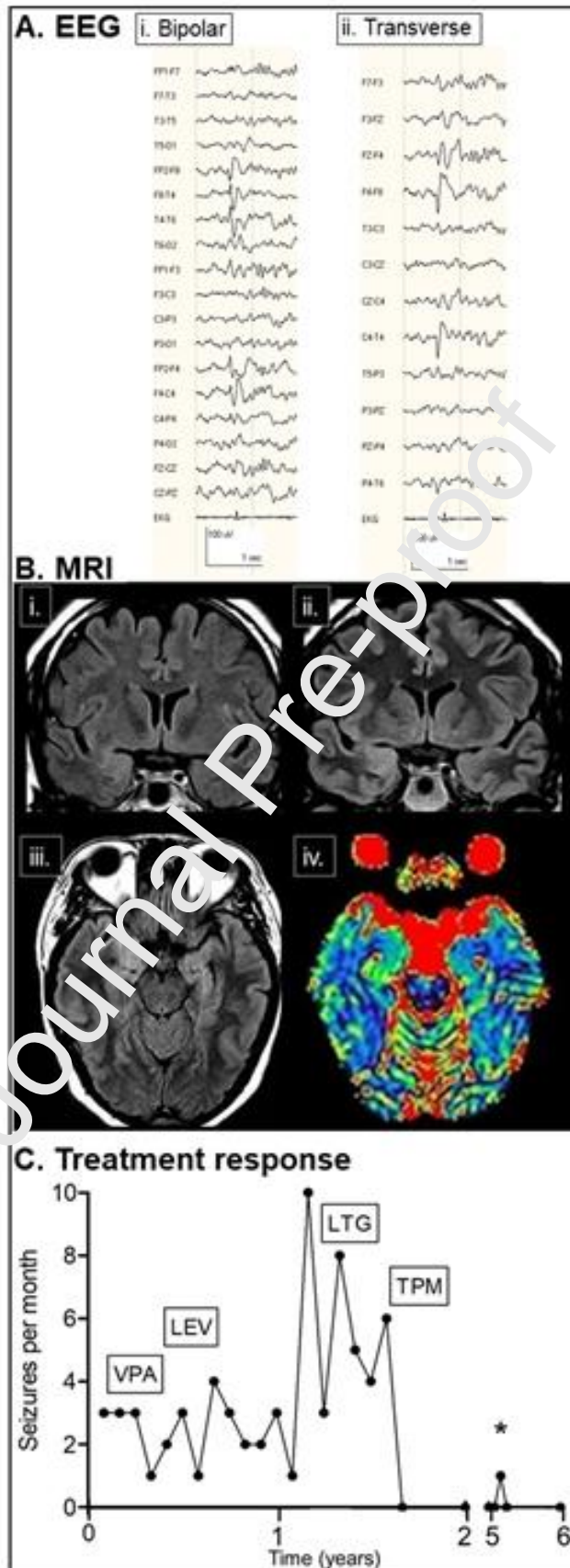
Kearney H, Byrne S, Cavalleri GL, Delany N. Tackling Epilepsy With High-definition Precision Medicine: A Review. *JAMA Neurol.* 2019 Aug 5. doi: 10.1001/jamaneurol.2019.2384.

Kwan P, Arzimanoglou A, Berg AT, Brodie MJ, Allen Hauser W, Mathern G, Moshé SL, Perucca E, Wiebe S, French J. Definition of drug resistant epilepsy: consensus proposal by the ad hoc Task Force of the ILAE Commission on Therapeutic Strategies. *Epilepsia.* 2010;51:1069-77.

Segovia-Miranda F, Cerrano F, Dyrda A, Ampuero E, Retamal C, Bravo-Zehnder M, Parodi J, Zamorano P, Valenzuela D, Massardo L, van Zundert B, Inestrosa NC, González A. Pathogenicity of lupus anti-ribosomal P antibodies: role of cross-reacting neuronal surface P antigen in glutamatergic transmission and plasticity in a mouse model. *Arthritis Rheumatol.* 2015;67(6):1598-610.

Shank RP, Gardocki JF, Streeter AJ, Maryanoff BE. An overview of the preclinical aspects of topiramate: pharmacology, pharmacokinetics, and mechanism of action. *Epilepsia.* 2000;41 Suppl 1:S3-9.

Figure 1. A. Electroencephalogram: bipolar montage (A.i) and transverse montage (A.ii) showing right fronto-temporal epileptiform discharges. **B.** Magnetic resonance images showing T2 hyperintensities and discrete increased volume of right temporal amygdala and head of the hippocampus in first MRI (i. coronal T2-FLAIR) and 6 year follow-up (ii. coronal T2-FLAIR; iii. Axial T2-FLAIR), and increased radial diffusivity color coded DTI maps (B.iv.). **C.** Treatment response to antiepileptic drugs (VPA: valproic acid, LEV: levetiracetam, LTG: lamotrigine and TPM: topiramate). *, seizure that occurred after stopping the topiramate for 1 week at the fifth year of treatment.



Highlights

- Anti-P antibodies have been associated with neuropsychiatric symptoms in SLE.
- There could be a pathogenic link between these antibodies and epilepsy.
- These antibodies increase glutamatergic activity at the synapse in animal models.
- A selective blockade with topiramate may be considered in epilepsy with anti-P.

Journal Pre-proof