



## Surgical Venous Drainage Disconnection from Cavernous Sinus Dural Arteriovenous Fistula and Ruptured Varix

Yusuke Iki<sup>1</sup>, Yoichi Morofuji<sup>1</sup>, Chika Somagawa<sup>2</sup>, Susumu Yamaguchi<sup>2</sup>, Jumpei Hamabe<sup>3</sup>, Nobutaka Horie<sup>1</sup>, Tsuyoshi Izumo<sup>1</sup>, Kazuhiko Suyama<sup>2</sup>, Takayuki Matsuo<sup>1</sup>

### Key words

- Cavernous sinus dural arteriovenous fistula
- Deep middle cerebral vein
- Draining venous disconnection
- Repeat intracranial bleeding

### Abbreviations and Acronyms

**APhA:** Ascending pharyngeal artery

**CS:** Cavernous sinus

**CS dAVF:** Cavernous sinus dural arteriovenous fistula

**CT:** Computed tomography

**DMCV:** Deep middle cerebral vein

**DSA:** Digital subtraction angiography

**IPS:** Inferior petrosal sinus

**MMA:** Middle meningeal artery

From the <sup>1</sup>Departments of Neurosurgery, Nagasaki University Graduate School of Biomedical Sciences, Nagasaki;

<sup>2</sup>Departments of Neurosurgery, Nagasaki Harbor Medical Center, Nagasaki; and <sup>3</sup>Department of Neurology and Stroke, Nagasaki Harbor Medical Center, Nagasaki, Japan

To whom correspondence should be addressed: Yusuke Iki, M.D.

[E-mail: [yusuke.nagasaki1119@gmail.com](mailto:yusuke.nagasaki1119@gmail.com)]

Citation: *World Neurosurg.* (2020) 137:18-23.

<https://doi.org/10.1016/j.wneu.2020.01.058>

Journal homepage: [www.journals.elsevier.com/world-neurosurgery](http://www.journals.elsevier.com/world-neurosurgery)

Available online: [www.sciencedirect.com](http://www.sciencedirect.com)

1878-8750/\$ - see front matter © 2020 Elsevier Inc. All rights reserved.

### INTRODUCTION

In general, cavernous sinus dural arteriovenous fistulas (CS dAVFs) are recognized as benign arteriovenous malformations that sometimes result in ocular neurologic deficits. In rare cases, CS dAVFs exhibit aggressive behaviors such as venous infarction, intracranial bleeding, and seizures. CS dAVFs may have various drainage routes, and their occasional aggressive behavior is dependent on the drainage route. The present report describes a spontaneous CS dAVF with deep drainage toward the basal vein of Rosenthal via the uncal vein, which caused massive intracranial hemorrhage. The standard therapy

■ **BACKGROUND:** Cavernous sinus dural arteriovenous fistulas (CS dAVFs) occasionally behave aggressively (e.g., intracranial hemorrhage, venous infarction, seizures) depending on the drainage flow and presence of a collateral route of cortical or basal cerebral venous drainage. When a CS dAVF with aggressive behavior is encountered, a radical cure is required to avoid catastrophic deficits. However, conventional transvenous cavernous sinus (CS) embolization via the inferior petrosal sinus does not always achieve shunt obliteration. We herein report a case of surgical venous drainage disconnection in an 83-year-old woman with a CS dAVF.

■ **CASE DESCRIPTION:** The patient presented with coma and anisocoria due to intracranial hemorrhage. Because of the patient's critical condition, we had no choice but to perform emergency decompressive craniectomy and hematoma evacuation without detailed preoperative hemodynamic information obtained by digital subtraction angiography. Postoperative digital subtraction angiography showed a CS dAVF with retrograde venous drainage of the deep middle cerebral vein (DMCV) and varix formation in the affected DMCV, causing hemorrhagic episodes. Five days after admission, the patient's neurologic state worsened because of rebleeding from the varix, which had increased in size. The percutaneous transvenous approach failed because of compartmentalization within the CS. Open surgery was performed; the deep vasculature was exposed by the transylvian approach, and the arterialized DMCV was permanently clipped at its proximal segment with disconnection from the venous varix and fistulous point. Shunt obliteration was successfully achieved.

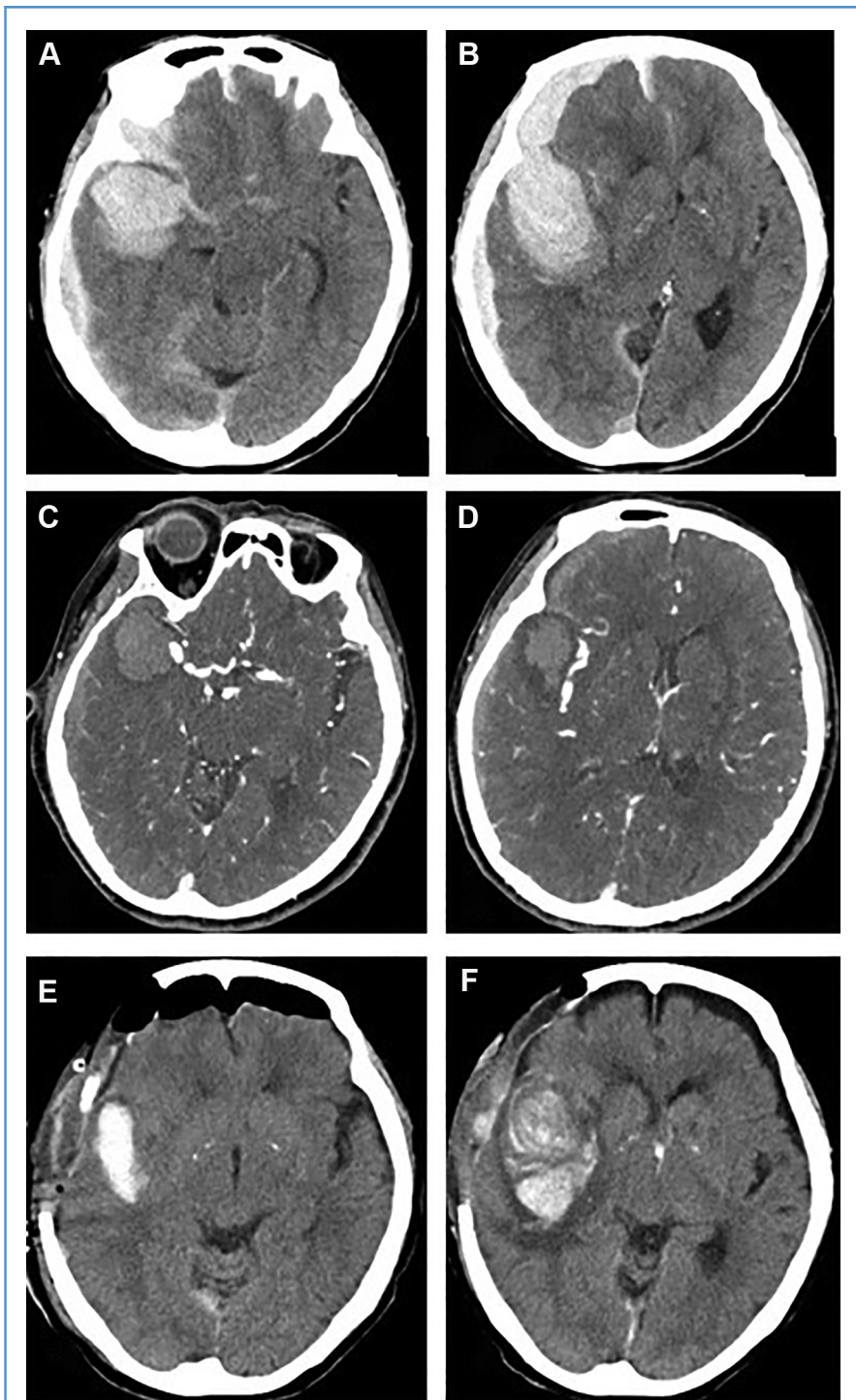
■ **CONCLUSIONS:** Surgical venous drainage disconnection from the fistulous point may be an alternative radical therapy for CS dAVFs with aggressive behaviors.

for CS dAVF is currently femoral access and transvenous cavernous sinus (CS) embolization via the inferior petrosal sinus (IPS),<sup>1</sup> but this treatment does not apply to every case. Several access routes have been reported as alternatives. However, many of these are advanced and time-consuming techniques with a potential risk of unpredictable complications. A CS dAVF with aggressive behavior should be treated by radical obliteration.<sup>2</sup> We herein report a case of a CS dAVF with repeated hemorrhagic episodes due to a deep draining venous varix. The CS dAVF was successfully obliterated by draining

venous disconnection with surgical clipping.

### CASE REPORT

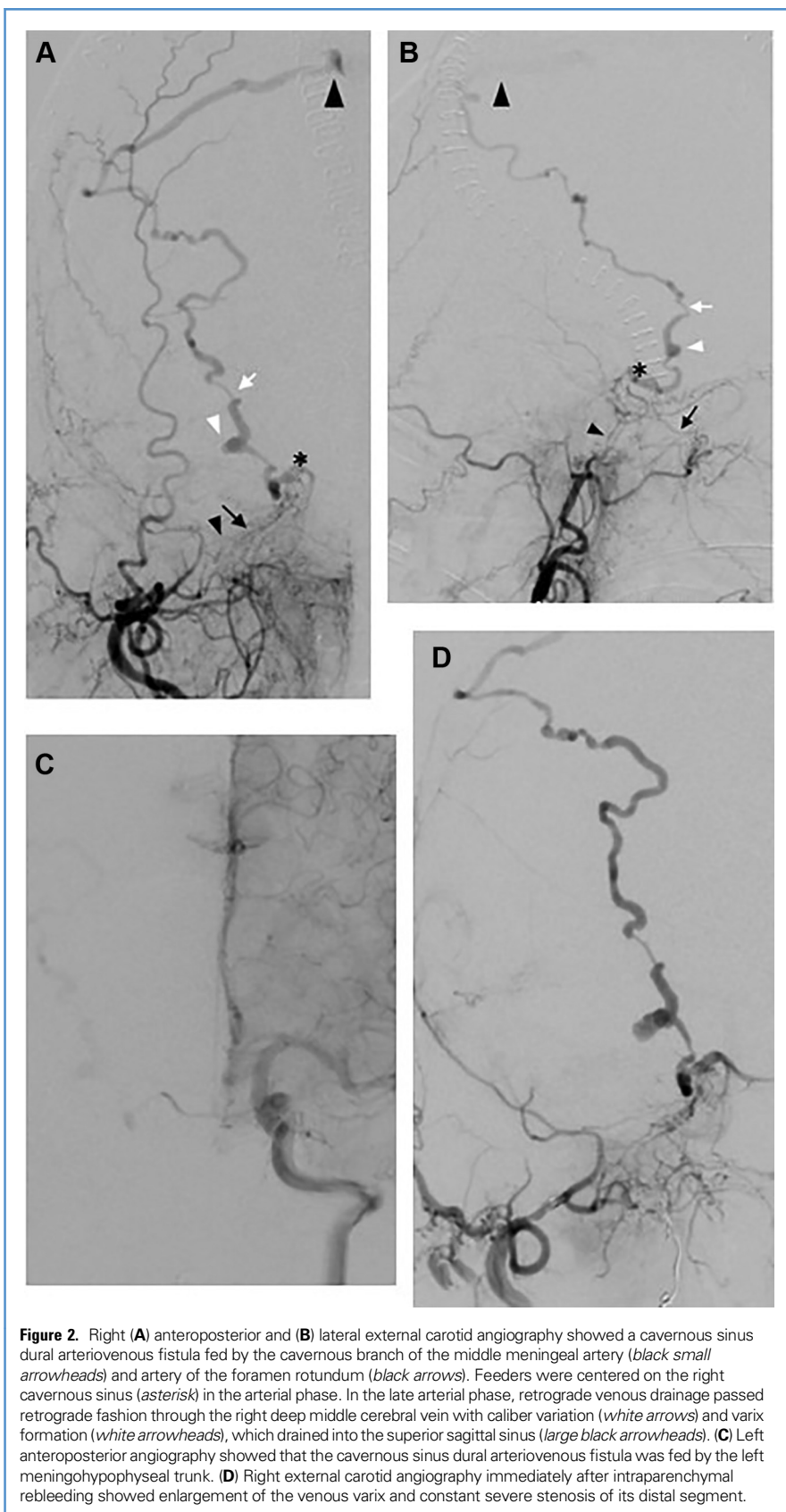
An 83-year-old woman was transferred to our hospital with a coma, anisocoria, and left hemiparesis that had developed immediately after a sudden-onset headache. She had no history of trauma. Head computed tomography (CT) showed transtentorial and cingulate herniation due to subarachnoid hemorrhage, an intraparenchymal hematoma in the right temporal lobe, and an ipsilateral subdural



**Figure 1.** (A and B) Admission computed tomography (CT) showed subarachnoid hemorrhage, an intraparenchymal hematoma in the right temporal lobe, and an ipsilateral subdural hematoma, which had caused transtentorial and cingulate herniation. (C and D) Concurrent CT angiography revealed a vascular malformation in which the dilated and tortuous vasculature passed a nearby temporal hematoma from the right parasellar region to the ipsilateral parietal cortex, which drained into the superior sagittal sinus. (E) On postoperative day 1, plain CT showed improvement of the cerebral herniation after decompressive craniectomy and partial hematoma evacuation. (F) On postoperative day 5, emergency CT showed intraparenchymal rebleeding around the initial temporal hematoma because of the reruptured venous varix.

hematoma (Figure 1). The patient was treated by emergency open surgery involving hematoma evacuation and decompressive craniectomy. Preoperative CT angiography showed dilated and tortuous vasculature passing near the temporal hematoma from the right parasellar region to the ipsilateral parietal cortex and draining into the superior sagittal sinus. Although these findings indicated a vascular anomaly, detailed hemodynamic information by digital subtraction angiography (DSA) was not available preoperatively because of the patient's critical condition.

The day after the operation, a CS dAVF with deep drainage via the uncus vein was detected by DSA (Figure 2). Right carotid angiography demonstrated a CS dAVF fed by the cavernous branch of the middle meningeal artery (MMA), ascending pharyngeal artery (APhA), artery of the foramen rotundum, and meningohypophyseal trunk, as well as the left meningohypophyseal trunk. The early retrograde venous filling drainage flowed into the superior sagittal sinus via the right deep middle cerebral vein (DMCV), forming a venous varix associated with bleeding (Cognard classification; type 4). According to Suh et al,<sup>3</sup> this CS dAVF was classified as "the restricted type." A microcatheter (Excelsior SL1018; Stryker Neurovascular, Fremont, California, USA) was delivered to the distal segment of the affected APhA and MMA, individually, and a detachable coil (Target XL; Stryker Neurovascular) was used for flow reduction of feeders. Only transarterial coil embolization of the APhA and MMA was performed at that time, and elective transvenous CS embolization by femoral access was planned. Five days after admission, the patient suddenly exhibited lowering of consciousness and worsening of the left hemiparesis. Emergency CT revealed intraparenchymal rebleeding around the initial temporal hematoma. Considering the repeated hemorrhagic episodes associated with the draining venous varix, we attempted emergency transvenous CS embolization. Right cerebral arteriography showed the CS dAVF, which drained the retrograde toward the superior sagittal sinus and already-known draining venous varix, which had increased in size. A



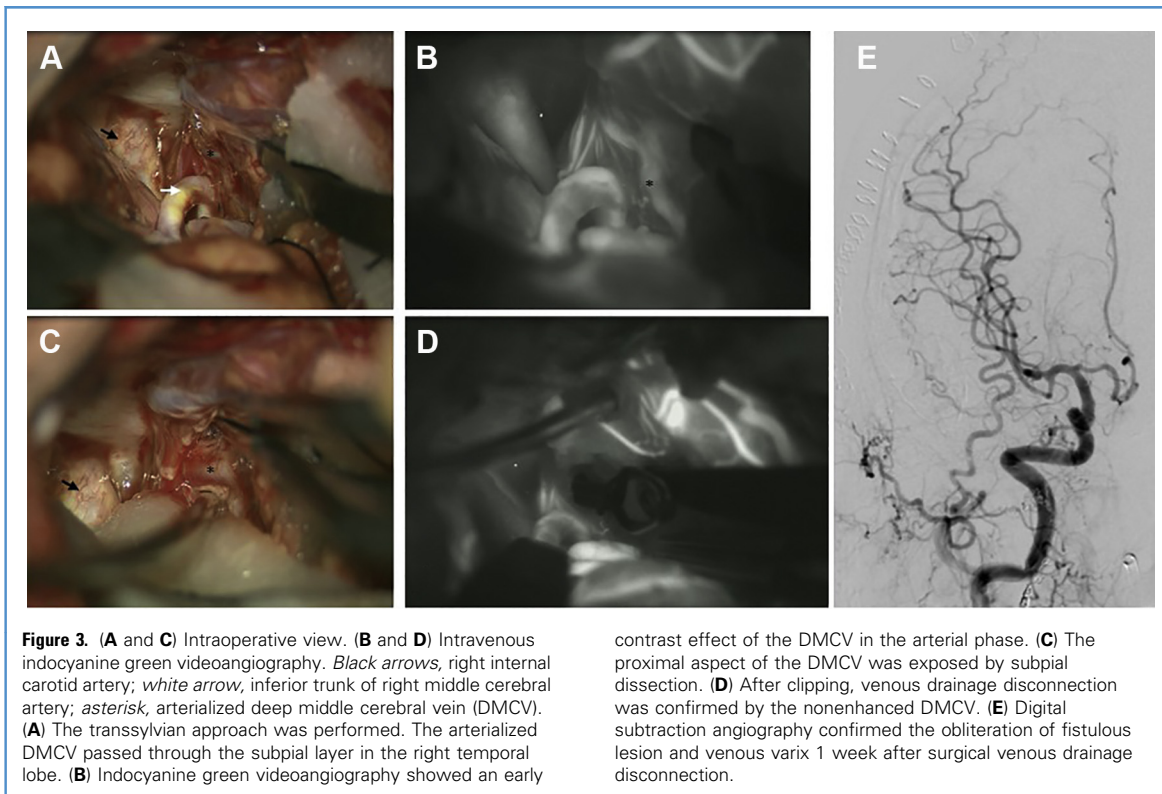
**Figure 2.** Right (A) anteroposterior and (B) lateral external carotid angiography showed a cavernous sinus dural arteriovenous fistula fed by the cavernous branch of the middle meningeal artery (*black small arrowheads*) and artery of the foramen rotundum (*black arrows*). Feeders were centered on the right cavernous sinus (*asterisk*) in the arterial phase. In the late arterial phase, retrograde venous drainage passed retrograde fashion through the right deep middle cerebral vein with caliber variation (*white arrows*) and varix formation (*white arrowheads*), which drained into the superior sagittal sinus (*large black arrowheads*). (C) Left anteroposterior angiography showed that the cavernous sinus dural arteriovenous fistula was fed by the left meningo-hypophyseal trunk. (D) Right external carotid angiography immediately after intraparenchymal rebleeding showed enlargement of the venous varix and constant severe stenosis of its distal segment.

microcatheter (Marathon; Medtronic, Minneapolis, Minnesota, USA) was advanced to the CS via the ipsilateral IPS, but it did not reach the fistulous point because of restricted flexibility of the microcatheter tip, indicating compartmentalization due to development of the affected CS septum. To avoid further catastrophic deficits, we altered the strategy by performing surgical disconnection of the venous drainage from the fistulous point. The patient was transferred to the operating room and underwent a second surgery, during which the hematoma was evacuated and deep vasculature was exposed using a transsylvian approach. A wide opening of the sylvian fissure allowed us to observe the dilated and arterialized DMCV, which was visually recognized as a subcortical lesion in the temporal lobe (Figure 3). It flowed out deeply into the temporal lobe. After subpial dissection for exposure, surgical clipping was applied at the exit of the draining vein from the right CS. Intraoperative indocyanine green videoangiography confirmed complete occlusion of the draining vein. One week after the surgical procedure, DSA showed obliteration of the fistulous lesion and venous varix. The patient gradually recovered from her mild somnolence and left hemiparesis (upper and lower limbs, grade 4/5). Three weeks after the operation, the patient was transferred to a rehabilitation institute. No postoperative recurrence was confirmed during a 2-year follow-up.

## DISCUSSION

### CS dAVFs with Aggressive Behavior and Alternatives for Limited Transvenous Access Route

CS dAVFs rarely present with aggressive behaviors, most of which are accompanied by conjunctival hyperemia and concomitant ocular dysfunction.<sup>4</sup> Clinical symptoms can vary depending on the degree and direction of shunt flow<sup>5</sup> and whether the neighboring sinus is affected by thrombosis. Transvenous CS embolization via the IPS by the femoral approach has been described as a standard therapy. AVFs with retrograde cortical venous drainage reportedly have a high risk of early rebleeding within



**Figure 3.** (A and C) Intraoperative view. (B and D) Intravenous indocyanine green videoangiography. *Black arrows*, right internal carotid artery; *white arrow*, inferior trunk of right middle cerebral artery; *asterisk*, arterialized deep middle cerebral vein (DMCV). (A) The transsylvian approach was performed. The arterialized DMCV passed through the subpial layer in the right temporal lobe. (B) Indocyanine green videoangiography showed an early

contrast effect of the DMCV in the arterial phase. (C) The proximal aspect of the DMCV was exposed by subpial dissection. (D) After clipping, venous drainage disconnection was confirmed by the nonenhanced DMCV. (E) Digital subtraction angiography confirmed the obliteration of fistulous lesion and venous varix 1 week after surgical venous drainage disconnection.

2 weeks, with the rebleeding episode being worse and potentially fatal compared with the first.<sup>2</sup> In our patient, a repeated hemorrhage episode within a short duration occurred because of rupture of the varix of the affected DMCV of the CS dAVF, which was obliterated by surgical venous drainage disconnection. The increased varix size seemed to be a suggestive finding.<sup>6</sup> Severe cases showing aggressive behavior require immediate radical cure as soon as possible to avoid catastrophic progression. However, we sometimes encounter troublesome cases with an obstructed route due to secondary sinus thrombosis or compartmentation within the CS. Various alternatives have been reported in accordance with individual hemodynamics and available venous access (e.g., superior ophthalmic vein,<sup>7,8</sup> foramen ovale,<sup>9</sup> and intercavernous sinus). However, these techniques are advanced and time consuming and have a potential risk of unpredictable complications. Indeed, the percutaneous approach of the superior ophthalmic veins has been described, but this technique has nonnegligible risks of

intraorbital hematoma and cutaneous nerve injuries. Transarterial Onyx embolization of fistulas was recently highlighted as an alternative treatment of CS dAVFs.<sup>10,11</sup> While Onyx has become the preferred embolysate, its broad usage is limited by possible embolic complications related to numerous dangerous anastomoses and occlusion of the vasa nervorum. Transarterial feeder occlusion for flow reduction and radiosurgery have also been established, but these remain only second-line therapies.<sup>12</sup>

#### CS dAVF with Deep Drainage Toward DMCV via Uncal Vein

Although the CS has many extracranial drainage routes, CS dAVFs with aggressive behavior result from a restricted drainage route due to secondary thrombosis neighboring the affected CS.<sup>6</sup> Arterial blood flow running through the venous system induces gradual thickening of the intima,<sup>13</sup> leading to secondary thrombosis and stenosis. The fluid pressure of venous drainage increases to a dangerous level as thrombosis occurs at other sites (particularly the IPS, superior petrosal

sinus, and ophthalmic veins). Intracranial hemorrhagic onset of CS dAVFs with drainage into the DMCV has rarely been reported. We reviewed the literature in PubMed and identified 3 reports<sup>6,14,15</sup> (i.e., total of 4 cases including our patient). All patients were women and experienced onset at >68 years of age. In all patients except ours, the prehospital prodromal sign was chemosis. All patients also had neighboring sinus thrombosis (Table 1). Our patient exhibited varix formation associated with the affected draining vein. Sequential enlargement of a venous varix with repeat rupture is extremely rare. Conventional transvenous CS coil embolization was performed in the other 3 cases; only our patient was treated with surgical venous drainage disconnection using a permanent titanium clip. Shunt obliteration was successfully achieved in all cases.

#### Surgical Direct Cannulation for Retrograde Draining of CS dAVFs

With respect to the surgical treatment of CS dAVFs, other reports have stated that microsurgical direct cannulation for retrograde draining of the superficial

**Table 1.** Hemorrhagic Onset of Cavernous Sinus Dural Arteriovenous Fistula (CS dAVF) With Retrograde Deep Middle Cerebral Vein (DMCV) Drainage

First Author	Year	Age (year)/ Sex	Prodromic Sign	Types of Intracranial Hemorrhage	Symptoms of Hemorrhagic Onset	Hematoma Interval	Hematoma Evacuation	Venous Drainage	Angiographic Features	Treatment	Immediate Outcome	Recurrence
Takazawa	2005	81/F	Chemosis, exophthalmos	IPH (putamen)	Seizure	N/A	No	SOV (stagnation), SMCV, DMCV, BVR	SOV (stagnation), agenesis of BVR	CS coil embolization	Incomplete obliteration	No
Kiura	2007	82/F	Chemosis, exophthalmos	IPH (insular cortex), SAH	Somnolence, hemiparesis	1 week	No	SOV and DMCV (stagnation), SMCV	SOV and DMCV (stagnation)	CS coil embolization	Complete obliteration	No
Miyamoto	2009	68/F	Diplopia, abducent palsy	IPH (temporal lobe)	Hemiparesis	1 month	No	DMCV (stagnation), BVR	DMCV (stagnation)	CS coil embolization	Complete obliteration	No
Present case	2019	83/F	None	IPH (temporal lobe), SAH, SDH	Coma, hemiparesis	N/A	Yes	DMCV, IPS (stagnation)	Varix formation	Surgical extirpation	N/A	No

Interval, interval between prodromic sign and hemorrhage; F, female.

Sylvian vein was a useful procedure of transvenous CS coil embolization via the sphenoparietal sinus.<sup>16</sup> With a microcatheter advanced into the affected CS, sinus packing was performed until shunt obliteration and draining venous occlusion were obtained. Although the risk of abducens palsy after sinus packing should be considered, transcortical affected sinus packing may be one of the most reliable alternatives for a radical cure instead of a failed conventional transfemoral approach.

#### Surgical Venous Drainage Disconnection from CS dAVFs and Varix

In our patient, we performed surgical clipping for venous drainage disconnection between the fistulous point and ruptured varix. Even if draining DMCV was surgically cannulated proximally for CS packing, catheterization into the CS would be a challenging procedure because of the insecure catheter operating in a narrow and deep space. A pendent access route unlined with dura mater and complicated anatomic variations of the uncus vein result in an extraordinarily difficult catheter operation.<sup>17</sup> Furthermore, retrograde forcible catheterization of arterialized veins is challenging and associated with a risk of perforation, leading to iatrogenic rebleeding. Fortunately, by

surgical occlusion of the draining vein, shunt obliteration was achieved in the short-term DSA follow-up. As to long-term outcome after endovascular treatment of CS dAVFs, eliminating cortical venous reflux and major retrograde shunt flow has been reported to be equivalent to immediate shunt disappearance elicited by tight coil packing of the CS.<sup>18</sup> Some reports have stated that drainer occlusion would trigger opening of the sleeping channels, resulting in dangerous drainage. Semiquantitative flow analysis during indocyanine green videoangiography may facilitate the identification of arterialized veins and shunt obliteration.<sup>19,20</sup> In addition, intraoperative cerebral angiography may be useful for simple and repeatable evaluation of hemodynamic alternations.

#### CONCLUSION

CS dAVFs with massive intracranial hemorrhage require immediate hematoma evacuation and radical treatment for shunt obliteration. CS dAVFs often present unique treatment challenges depending on the anatomy and pattern of venous drainage. Our report illustrates that surgical venous drainage disconnection as a last resort can be a valuable radical

alternative for CS dAVFs with limited venous access.

#### ACKNOWLEDGMENT

We thank Angela Morben, DVM, ELS, from Edanz Group (<https://en-author-services.edanzgroup.com/>) for editing a draft of this manuscript.

#### REFERENCES

- Kirsch M, Henkes H, Liebig T, et al. Endovascular management of dural carotid-cavernous sinus fistulas in 141 patients. *Neuroradiology*. 2006;48:486-490.
- Duffau H, Lopes M, Janosevic V, et al. Early rebleeding from intracranial dural arteriovenous fistulas: report of 20 cases and review of the literature. *J Neurosurg*. 1999;90:73-84.
- Chul Suh D, Hyun Lee J, Joon Kim S, et al. New concept in cavernous sinus dural arteriovenous fistula correlation with presenting symptom and venous drainage patterns. 2005. Available at: <https://doi.org/10.1161/01.STR.0000166194.82027.63>. Accessed January 6, 2019.
- Kuwayama N, Endo S, Kitabayashi M, Nishijima M, Takaku A. Surgical transvenous embolization of a cortically draining carotid cavernous fistula via a vein of the Sylvian fissure. *Am J Neuroradiol*. 1998;19:1329-1332.
- Leone G, Renieri L, Enriquez-Marulanda A, et al. Carotid cavernous fistulas and dural arteriovenous fistulas of the cavernous sinus: validation of a new classification according to venous drainage. *World Neurosurg*. 2019;128:e621-e631.

6. Miyamoto N, Naito I, Takatama S, Shimizu T, Iwai T, Shimaguchi H. Clinical and angiographic characteristics of cavernous sinus dural arteriovenous fistulas manifesting as venous infarction and/or intracranial hemorrhage. *Neuroradiology*. 2009;51:53-60.
7. Alexandre AM, Visconti E, Lozupone E, D'Argento F, Pedicelli A. Embolization of dural arteriovenous fistula of the cavernous sinus through percutaneous ultrasound-guided puncture of the facial vein. *World Neurosurg*. 2017;99:812.e13-812.e20.
8. Briganti F, Caranci F, Leone G, et al. Endovascular occlusion of dural cavernous fistulas through a superior ophthalmic vein approach. 2013;26. Available at: [www.centauro.it](http://www.centauro.it). Accessed January 6, 2020.
9. Cabral De Andrade G, Alves HP, Parente R, Salvarani CP, Clímaco VM, Pereira ER. Spontaneous isolated dural arteriovenous fistula of the cavernous sinus: endovascular approach via the foramen ovale. A technical note. *Interv Neuroradiol*. 2012;18:458-462.
10. Wen J, Duan CZ, Huang LJ, Zhang X, He XY, Li XF. Transarterial Onyx embolization for patients with cavernous sinus dural arteriovenous fistulas who have failed transvenous embolization. *Cell Biochem Biophys*. 2015;73:163-169.
11. Wenderoth J. Novel approaches to access and treatment of cavernous sinus dural arteriovenous fistula (CS-DAVF): case series and review of the literature. *J Neurointerv Surg*. 2017;9:290-296.
12. Signorelli F, Gory B, Maduri R, et al. Intracranial dural arteriovenous fistulas: a review of their current management based on emerging knowledge. *J Neurosurg Sci*. 2017;61:193-206.
13. Nishijima M, Takaku A, Endo S, et al. Etiological evaluation of dural arteriovenous malformations of the lateral and sigmoid sinuses based on histopathological examinations. *J Neurosurg*. 1992;76:600-606.
14. Takazawa H, Kubo M, Kuwayama N, et al. Dural arteriovenous fistula involving the cavernous sinus as the cause of intracerebral venous hemorrhage: a case report. *Neurol Surg*. 2005;33:143-147.
15. Kiura Y, Ohba S, Sbibukawa M, et al. A case of cavernous sinus dural arteriovenous fistulas causing hemorrhage shortly after eye symptoms appears. *Jpn J Neurosurg*. 2007;16:799-804.
16. Akamatsu Y, Sato K, Endo H, Matsumoto Y, Tominaga T. Single-session hematoma removal and transcranial coil embolization for a cavernous sinus dural arteriovenous fistula: a technical case report. *World Neurosurg*. 2017;104:1046.e7-1046.e12.
17. Ide S, Kiyosue H, Tanoue S, et al. Anatomical variations in termination of the uncal vein and its clinical implications in cavernous sinus dural arteriovenous fistulas. Available at: <https://doi.org/10.1007/s00234-014-1383-6>. Accessed November 10, 2019.
18. Nishimuta Y, Awa R, Sugata S, et al. Long-term outcome after endovascular treatment of cavernous sinus dural arteriovenous fistula and a literature review. Available at: <https://doi.org/10.1007/s00701-017-3336-4>. Accessed January 6, 2020.
19. Maduri R, Guyotat J, Signorelli F. Semi-quantitative assessment of flow dynamics during indocyanine green video-angiography in the treatment of intracranial dural arteriovenous fistulas: how I do it. *Acta Neurochir (Wien)*. 2016;158:1387-1391.
20. Messina R, Bozzi MT, Chiumarulo L, Tacconi L, Signorelli F. Ruptured tentorial arteriovenous fistula: endoscopic-assisted microsurgical disconnection using indocyanine green video-angiography guidance. *World Neurosurg*. 2020;134:377.

*Conflict of interest statement: The authors declare that the article content was composed in the absence of any commercial or financial relationships that could be construed as a potential conflict of interest.*

Received 16 December 2019; accepted 8 January 2020

Citation: *World Neurosurg*. (2020) 137:18-23.

<https://doi.org/10.1016/j.wneu.2020.01.058>

Journal homepage: [www.journals.elsevier.com/world-neurosurgery](http://www.journals.elsevier.com/world-neurosurgery)

Available online: [www.sciencedirect.com](http://www.sciencedirect.com)

1878-8750/\$ - see front matter © 2020 Elsevier Inc. All rights reserved.