



CASE REPORT

WILEY

Pediatric liver transplant following near catastrophic head bleed: Lessons learned

Alex G. Cuenca^{1,2} | Stephen Hardy³ | Uzma Shah³ | David Lawlor⁴ | Zehra Ordulu⁵ | Desiree Sierra Velez³ | Katherine Olshan³ | William Butler⁶ | Heidi Yeh¹

¹Surgery/Abdominal Transplant, Massachusetts General Hospital, Boston, MA, USA

²Pediatric Transplant Center, Boston Children's Hospital, Boston, MA, USA

³Pediatrics/Gastroenterology, Massachusetts General Hospital, Boston, MA, USA

⁴Surgery/Pediatric Surgery, Massachusetts General Hospital, Boston, MA, USA

⁵Pathology, Massachusetts General Hospital, Boston, MA, USA

⁶Neurosurgery, Massachusetts General Hospital, Boston, MA, USA

Correspondence

Heidi Yeh, Surgery/Abdominal Transplant, Massachusetts General Hospital, Boston, MA, USA.

Email: hyeh@mgh.harvard.edu

Abstract

Evaluation for liver transplant candidacy is a multidisciplinary effort that involves all aspects of clinical care including social work, nutrition, and a multitude of medical specialties. The prognosis of a pretransplant clinical condition is integrated into the decision to list a patient. Herein, we report a successful liver transplant and recovery of a 3-month-old male following a large right hemispheric subdural hematoma related to acute coagulopathy secondary to undiagnosed end-stage liver disease. On presentation with jaundice, lethargy, and unequal pupils, a CT scan was obtained which demonstrated a large right subdural hematoma with herniation. Once his coagulopathy was corrected, he went for decompressive craniectomy. He survived with medically controlled seizures and improving L-sided neglect and extremity weakness. Six weeks later, given his continued neurologic recovery and worsening liver function, the decision was made to list him for liver transplantation. One month later, he underwent orthotopic liver transplant. His post-operative hospital course was complicated by DVTs and heparin-induced thrombocytopenia, but no neurologic decline, and he was eventually discharged from the hospital on post-op day 26. Three years later, he has a well-functioning allograft and no clinically evident neurologic deficits. The prognosis following pediatric neurologic trauma remains somewhat unclear as recovery and neurologic examinations can be influenced by numerous extrinsic factors. This is one of the first reports of near full neurologic recovery of a pediatric liver transplant recipient following a large subdural hematoma with herniation.

KEYWORDS

intracranial haemorrhage, liver transplant, neurologic deficit

1 | INTRODUCTION

Despite advances in our understanding of congenital diseases that lead to liver failure in the pediatric population, there are still a significant number of infants that present with late complications related

to ESLD. The etiology of liver failure during the neonatal period and early infancy in this patient population includes metabolic disorders (tyrosinemia etc), biliary atresia, GALD, infection, and hypoxia-ischemia-related hepatopathy.^{1,2} The most common presentation is jaundice and hypoglycemia followed by renal failure, bleeding, and

Abbreviations: AASLD, American association for the study of liver diseases; AFP, alpha fetoprotein; BA, biliary atresia; DVT, deep venous thrombosis; ER, emergency room; ESLD, end-stage liver disease; GALD, gestational alloimmune liver disease; HD, hospital day; ICA, internal carotid artery; ICH, intracerebral hemorrhage; INR, international normalized ratio; MCA, middle cerebral artery; PCA, posterior cerebral artery; POD, post-op day; PRES, posterior reversible encephalopathy syndrome.

encephalopathy.^{2,3} As might be expected, when these patients present, they are extremely ill and may be beyond the window to tolerate a liver transplant.

Regardless, most if not all patients will have a liver transplant evaluation initiated to determine candidacy for liver transplant. Per the most recent AASLD guidelines, absolute contraindications to pediatric liver transplant are currently extrahepatic malignancy, metastatic hepatocellular carcinoma or hepatoblastoma (beyond pulmonary metastasis), uncontrolled systemic infection, Niemann-Pick C disorder, severe multisystem mitochondrial disease, and severe portopulmonary hypertension not responsive to medical therapy.⁴ Though severe neurologic damage has also been suggested as an absolute or relative contraindication to liver transplantation, a thorough discussion with the institution's multidisciplinary committee will take each of these cases and other possible contraindication to liver transplant into consideration on a case by case basis.⁵ Focus and attention is paid to those patients that are clinically improving or those that have the capacity for reversal of their symptomology associated with liver failure.

Herein, we present a 3-month-old patient that presented with severe jaundice, coagulopathy, and intracranial hemorrhage. At the time of liver transplant evaluation and listing, the patient had not fully recovered from a neurologic perspective. Although the risk was high for additional complications related to coagulopathy or neurologic insult, the decision was made to proceed with transplant.

2 | CASE

The patient was a 3-month-old male with a history of neonatal jaundice, 2-month history of "bruising," and increased vomiting over the last 24 hours who presented to an outside hospital ER with increased jaundice. Pt was discharged from the outside hospital ER but returned to our ER with right-sided ptosis, increased non-bloody, non-bilious vomiting, and lethargy. On examination, the patient had asymmetric pupils (R 7-9 mm and L 3-4 mm), decorticate posturing, and a tense fontanel. The patient was intubated and taken for emergent CT scan. In addition, mannitol and hypertonic saline were administered. CT scan revealed large right-sided subdural hematoma with midline shift and uncus herniation (Figure 1). Neurosurgery was emergently consulted but the patient was not taken to OR immediately due to coagulopathy (INR was unrecordable). After correcting coagulopathy with fresh frozen plasma and IV vitamin K, the patient was taken to the OR for a right craniectomy with hematoma evacuation on HD 2. Post-operatively, the patient required continued fresh frozen plasma for correction of severe coagulopathy suggestive that the etiology of the coagulopathy was not a nutritional or absorption deficiency of vitamin K. Neurologic examination was limited due to sedation but spontaneous bilateral eye opening as well as brain stem reflexes (gag and corneal) were observed. Repeat head imaging revealed no additional bleeding but evidence of ischemia to the right ICA, MCA, and PCA territories. Despite seizure prophylaxis instituted at the time of presentation, the patient also had epileptiform

activity on EEG and required the addition of phenytoin for control. The patient was extubated on POD 5 from decompressive craniectomy and by POD 11 was able to take formula by enteric tube and some by mouth but was neurologically asymmetric from a motor standpoint (right side stronger than left). Once the patient was stable from a hemodynamic, neurologic, and hematologic standpoint, decision was made to perform a cranioplasty. The patient ultimately developed hydrocephalus and extra-axial fluid collections that necessitated ventriculopleural shunt placement. The patient tolerated these procedures well.

With regard to his liver failure, on admission, the patient was jaundiced with a total/direct bilirubin of 9.1/6.0 (mg/dL), petechiae, unrecordable INR, and an AFP of 14 000 (ng/mL). In addition, transaminases were mildly elevated in the 200s (U/L). The patient also had notable hepatosplenomegaly. While the patient was being stabilized from a neurologic and hematologic standpoint, hepatology and genetics were consulted. Metabolic, infectious, and toxic etiologies of liver failure were investigated and included cardiac echocardiography and CT imaging, as well as urine and serum testing for metabolic hepatopathies and disorders of glycogen storage. In addition to this, whole exome sequencing was done as well. Unfortunately, all testing was found to be negative or non-diagnostic. A liver biopsy was also performed which demonstrated severe liver failure, including cholestasis, giant cells, ductular reaction with proliferation, and fibrous septae. As the biopsy was not clearly conclusive for biliary atresia or other etiologies of liver failure in an infant, he was treated for tyrosinemia preemptively and was therefore switched to tyrosine free formula and underwent nitisinone treatment as the risk of treating him as having the presumptive diagnosis of tyrosinemia outweighed the risk of not treating him as such.

Unfortunately, his liver function tests continued to deteriorate and a liver transplant evaluation was initiated at 4 months of age. This multidisciplinary team included social work, nutrition, hematology, physical and occupational therapy, hepatology, transplant surgery, and importantly, neurology and neurosurgery. On evaluation by team, the patient had recovered symmetric motor strength but still had some evidence of left-sided neglect, neck muscle discoordination/weakness, and truncal hypotonia. While not fully recovered, the group felt his neurologic prognosis was quite good and was encouraged by his continued neurologic recovery from his initial insult. Importantly, the group also felt strongly that he could and would continue to recover with a liver transplant but would not survive without one.

A suitable deceased donor liver became available approximately one month later and the patient, now 5 months old, underwent an orthotopic liver transplant with Roux-en-Y hepaticojejunostomy in the absence of recipient common or hepatic bile duct. The patient did well post-operatively with excellent hepatic allograft function. During his post-operative course, the patient did develop DVTs of his IVC and right iliac vein and so a hypercoagulable work-up was initiated. The patient was found to be heparin-PF4 antibody positive, and therefore, DVTs were thought to be attributable to heparin-induced thrombocytopenia. Our hematology colleagues agreed.

FIGURE 1 Axial (A) and coronal (B) computed tomography sections of the patient's head on presentation to our ER

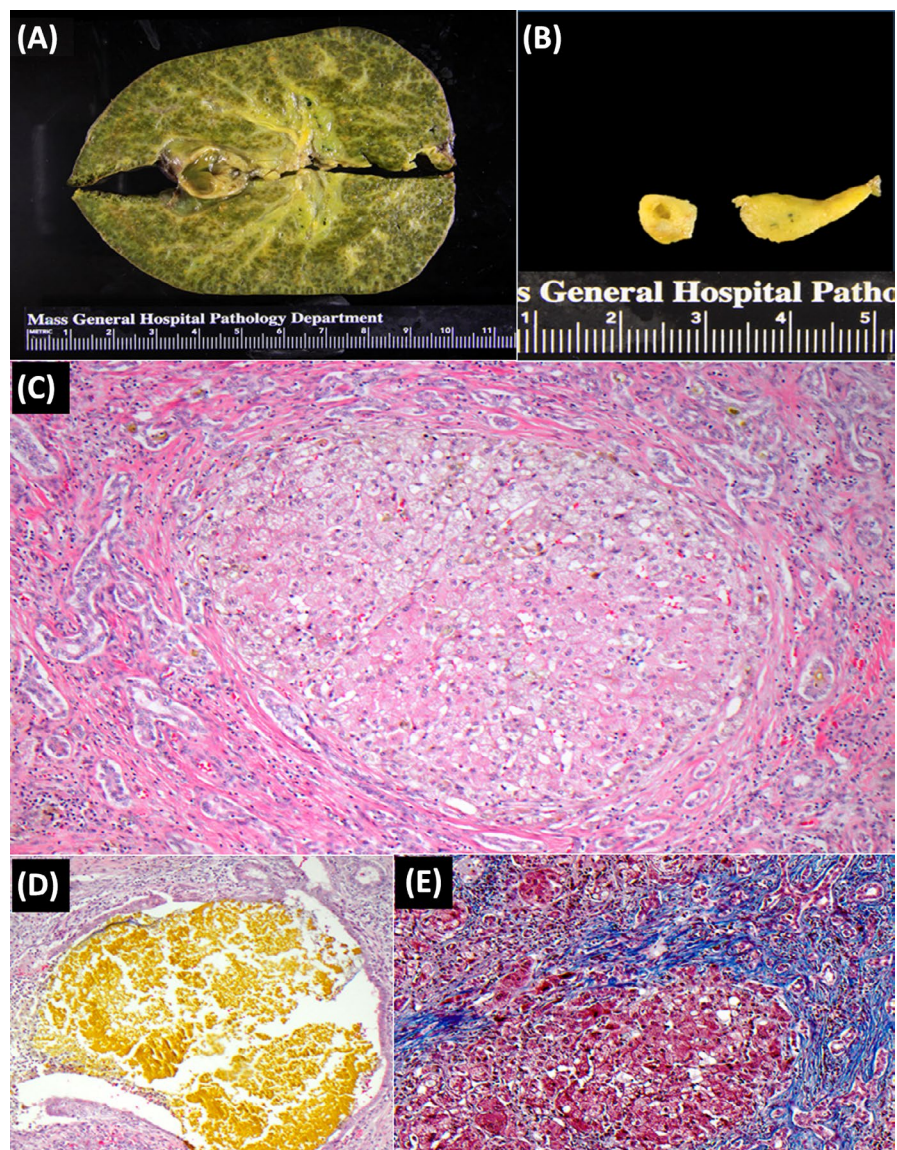
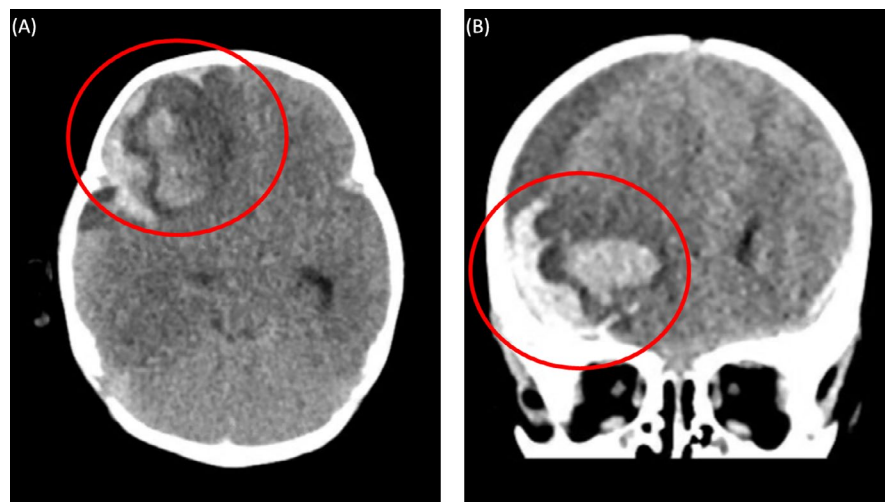


FIGURE 2 Gross and microscopic evidence for common bile duct atresia. A, Cirrhotic liver with green discoloration and bile plugs. B, Atretic common bile duct. C, Xanthomatous transformation of hepatocytes with surrounding cholangiolar proliferation. D, Prominent bile plug. E, Trichrome staining highlighting the fibrosis (blue) in cirrhotic transformation

Pt was maintained on fondaparinux for 6 months without bleeding complication or issue. The patient was discharged from the hospital on POD 26 from liver transplant playful, interactive, without focal deficits, and tolerating PO feeds. Final pathology from the native liver demonstrated marked cholangiolar proliferation with associated bile plugs, xanthomatous transformation of hepatocytes, and a trichrome stain that showed dense fibrous periductular septae and other features of cirrhotic transformation, all consistent with extra hepatic biliary atresia (Figure 2).

The patient presented to clinic recently, 3 years following transplant, meeting all developmental milestones and doing well aside from the occasional upper respiratory infection. For immunosuppression, the patient is maintained on tacrolimus only and has had normal liver function laboratories.

3 | DISCUSSION

The incidence of infant-related (within the first 120 days of life) acute liver failure is difficult to discern as there are only few contemporary cohort studies available and by and large they are from single centers.² As biliary atresia is the most common reason for pediatric transplant, progressive and relatively rapid liver failure from biliary atresia can occur and usually presents in the form of coagulopathy. The coagulopathy can lead to intracranial hemorrhage and subsequent irreversible neurologic sequelae. Fortunately, in our patient, these changes were reversible.

The decision of whether or not to proceed with an organ transplant in a child within the first year of life is not straightforward and requires the discussion of a multidisciplinary team. As the number of potential recipients still far outweighs the numbers of donors, most centers agree that the allocation of livers in this population should be relegated to those that have failed conventional medical therapy and/or are at serious risk of death within the first year of life. In addition, even though liver transplant outcomes have dramatically improved in this age group due to refinements in technique, as well as more experience with split or living donor liver surgery, technical complications are still thought to be greatest in this age group.^{6,7}

Despite these hurdles, outcomes following orthotopic liver transplant in the infant population are quite good and continue to improve. Overall 1-, 5-, and 10-year survival rates for pediatric patients undergoing liver transplant are approximately 90%, 80%, and 70%, respectively, compared to 75%, 65%, and 60% 10 years ago.⁸ In fact, long-term outcomes have been so good that some focus has now been shifted from survival of the pediatric liver transplant patient to improvement in quality of life metrics and minimizing the developmental delays associated with liver transplant.⁴

Given the excellent survival following liver transplant, his continued neurologic improvement, and the persistent coagulopathy despite product administration, we decided to proceed with a liver transplant in our patient. There are only a handful of studies in the literature on this subject. The largest and most recent of which is a series of 15 patients from 2006 that developed intracranial

hemorrhage due to BA.⁹ Akiyama and colleagues found that the incidence of ICH in BA in their center was approximately 8% (15 of 194).⁹ Of these, three patients developed hemiparesis that resolved completely. Most patients survived following either a portoenterostomy alone or a portoenterostomy following by transplant (11 of 15), and less than a third (2 of 15) had long-term neurologic sequelae, which included mental retardation (2 cases) and epilepsy (1 case).⁹

Neurologic complications are also not uncommon post-operatively following a liver transplant. One single-center study by Gungor et al found that 24% of their pediatric patients developed neurologic symptoms following liver transplant.⁶ This included encephalopathy and seizures most commonly to PRES and hemiparesis/paralysis in others.⁶ The etiology for these neurologic changes was multifactorial but thought to be related to mostly immunosuppression, hypoxic/ischemic brain injury, and metabolic derangements. Clearly, our patient was at extremely high risk for developing post-operative seizures secondary to his history of prior intracranial hemorrhage and seizure activity. In spite of this, our patient did well following the liver transplant and continued to improve neurologically.

To the best of our knowledge, this case represents the first reported near full neurologic recovery of a pediatric liver transplant recipient following a large acute subdural hematoma with herniation. Though this neurologic event would likely make him ineligible for transplant at most centers, we were encouraged by his pretransplant neurologic improvement and knew that he would not survive without a liver transplant. Therefore, while this case is unique and cannot be generalized to all similar clinical scenarios, it has broadened our discussion as to whether or not pediatric patients with acute neurologic events such as the one described above are eligible for organ transplantation. It also highlights the importance of multidisciplinary cooperation in the successful management of complex transplant candidates. Further, it would be useful to review large international biliary atresia registries to assess outcomes in patients with pre-LT neurological morbidity, for a better representation of outcomes.

CONFLICTS OF INTEREST

The authors of this manuscript have no conflicts of interest.

AUTHORS' CONTRIBUTIONS

AG. C and HY: Conceived the manuscript, edited, analyzed and interpreted the data; SH, WB, and US: Conceived the manuscript; US: Conceived and edited the manuscript; ZO: Reviewed and edited the figure and manuscript; DS. V and KO Reviewed and edited the manuscript.

ORCID

Alex G. Cuenca  <https://orcid.org/0000-0002-6219-7035>

REFERENCES

1. Kulkarni S, Perez C, Pichardo C, et al. Use of pediatric health information system database to study the trends in the incidence, management, etiology, and outcomes due to pediatric acute liver

- failure in the United States from 2008 to 2013. *Pediatr Transplant*. 2015;19:888-895.
2. Bitar R, Thwaites R, Davison S, Rajwal S, McClean P. Liver failure in early infancy. *J Pediatr Gastroenterol Nutr*. 2017;64:70-75.
 3. Squires JE, Rudnick DA, Hardison RM, et al. Liver transplant listing in pediatric acute liver failure: practices and participant characteristics. *Hepatology*. 2018;68:2338-2347.
 4. Squires RH, Ng V, Romero R, et al. Evaluation of the pediatric patient for liver transplantation: 2014 practice guideline by the American association for the study of liver diseases, American society of transplantation and the north american society for pediatric gastroenterology, hepatology. *J Pediatr Gastroenterol Nutr*. 2014;59(1):112-131.
 5. Ardizzone G, Arrigo A, Schellino MM, et al. Neurological complications of liver cirrhosis and orthotopic liver transplant. *Transplant Proc*. 2006;38:789-792.
 6. Gungor S, Kilic B, Arslan M, Selimoglu MA, Karabiber H, Yilmaz S. Early and late neurological complications of liver transplantation in pediatric patients. *Pediatr Transplant*. 2017;21:e12872.
 7. Cuenca AG, Kim HB, Vakili K. Pediatric liver transplantation. *Semin Pediatr Surg*. 2017;26(4):217-223.
 8. Kim WR, Lake JR, Smith JM, et al. OPTN/SRTR 2016 annual data report : liver. *Am J Transplant*. 2018;18:172-253.
 9. Akiyama HF, Okamura Y, Nagashima T, Yokoi A, Muraji T, Uetani Y. Intracranial hemorrhage and vitamin K deficiency associated with biliary atresia: summary of 15 cases and review of the literature. *Pediatr Neurosurg*. 2006;42(6):362-367.

How to cite this article: Cuenca AG, Hardy S, Shah U, et al. Pediatric liver transplant following near catastrophic head bleed: Lessons learned. *Pediatr Transplant*. 2020;00:e13646. <https://doi.org/10.1111/petr.13646>