

# Transient Cerebral Ischemia at High Altitude and Hyper-Responsiveness to Hypoxia

Jean-Paul Richalet,<sup>1-3</sup> Philippe Larmignat,<sup>2</sup> and Patricia Poignard<sup>4</sup>

## Abstract

Richalet, Jean-Paul, Philippe Larmignat, and Patricia Poignard. Transient cerebral ischemia at high altitude and hyper-responsiveness to hypoxia. *High Alt Med Biol* 00:000–000, 2019.—A 36-year-old woman with no medical history participated in a trekking in Ladakh up to 5300 m of altitude. She was well acclimatized and presented no previous sign of acute mountain sickness, high altitude pulmonary edema or high altitude cerebral edema. After an intense effort to catch up with her group, she became breathless and complained of visual disturbances, fatigue, dizziness, and confusion. During her descent to a lower altitude (4800 m), with the help of companions, she lost consciousness several times. After a 14-hour sleep, she recovered and all symptoms disappeared so that she was able to walk along with the group for 20 km. On returning home, she went through a battery of examinations that were all normal: cerebral magnetic resonance imaging, Doppler of supra-aortic arteries, 24 hours Holter, and cardiac transthoracic and transesophageal echography. A hypoxia exercise test revealed a hyper-response to hypoxia with severe hypocapnia. The etiology of this neurological episode is discussed (transient embolic ischemic attack, migraine, cerebral edema, and global amnesia). The patchy distribution of neurological symptoms is not in favor of a thrombotic event. The most probable diagnosis proposed is a transient cerebral ischemia due to local cerebral vasoconstriction related to hyperventilation-induced hypocapnia in a context of acute severe exercise. Special attention should be given to subjects who show a hyper-responsiveness to hypoxia before a sojourn at high altitude: they should avoid unnecessary hyperventilation due to any kind of stress, emotion, or exhaustive exercise.

**Keywords:** altitude; hyperventilation; hypocapnia; neurological disorder

## Introduction

**T**RANSIENT NEUROLOGICAL DISORDERS occurring at high altitude but not presenting the characteristics of acute mountain sickness (AMS) or high-altitude cerebral edema have been scarcely described at high altitude, mostly as case reports (Hackett et al., 1987; Basnyat et al., 2004; Firth and Bolay, 2004). Their mechanisms are still debated. The present case report describes an unusual rapidly resolving neurological disorder at high altitude in a young woman who had an extensive diagnostic work-up after returning home.

## Case Report

Mrs M.D., 36 years old (53 kg, 1.55 m), participated in a trekking in Ladakh in August 2018. After 4 days of accli-

matization at Leh (3700 m) and 15 days of walking between 3800 and 5300 m above sea level, without any particular problem or AMS symptom, Mrs. M.D. started with her companions the ascent of a 6000 m peak in Zanskar. After three nights at 4800 m without any problem, she had to make an intense effort for 10 minutes, during a climb to 5300 m, to catch up with the group that had taken the lead. She arrived panting at the group level and remained breathless for a few minutes. Then, she complained of sudden unilateral visual disturbances (left eye), characterized by altered vision, abnormal forms in the visual field (“kaleidoscope”), and a feeling of pressure around the left eye. She felt exhausted, severely dizzy, then slurred speech appeared as well as some confusion (according to her companions). For a few minutes, she could not find her words or the names of the people around her. She felt tingling and numbness in the right arm.

<sup>1</sup>INSERM U1272 Hypoxie et Poumon, Université Paris 13, Bobigny, France.

<sup>2</sup>Association pour la Recherche en Physiologie de l’Environnement, Bobigny, France.

<sup>3</sup>Institut National du Sport, de l’Expertise et de la Performance, Pôle médical, Paris, France.

<sup>4</sup>Assistance Publique-Hôpitaux de Paris, Hôpital Jean-Verdier, Service de Physiologie et Explorations Fonctionnelles, Bondy, France.

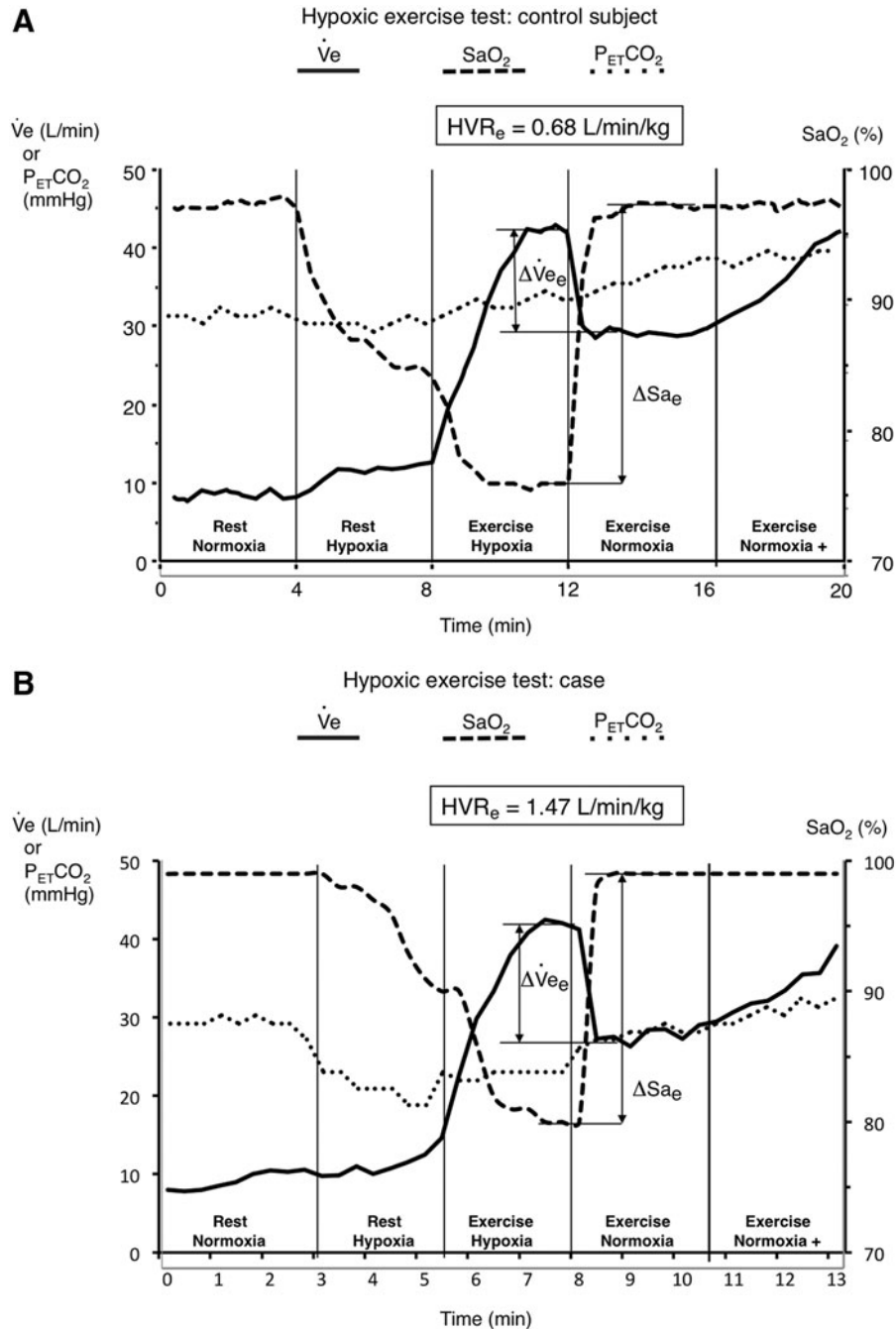
The group decided to get her down quickly. During the descent, as she became nearly unconscious and collapsed several times, she had to be supported by her companions. She did not respond to pats on the hand but finally to pats on the cheek.

Arriving at 4800 m after 3 hours of descent, she felt better. She was given oxygen for 20 minutes and was prevented from falling asleep. Then her condition seemed to improve and she slept continuously for 14 hours. No medication was given to her. She drank and ate slightly. The next day, she woke up without any symptom, no visual or other neurological signs.

She walked for 20 km with the rest of the group at altitudes between 4800 and 4500 m, without any neurological symptom or fatigue. At no time since her malaise, she felt any breathing difficulty.

She had taken aspirin during the trekking only occasionally (e.g., 500 mg in the morning of the malaise), but no other medication. She does not take oral contraception.

A brain magnetic resonance imaging (MRI) was performed 1 month after her episode (T1 sagittal slices, axial FLAIR, T2 \* diffusion, and coronal STIR) that evidenced no abnormalities and gave no argument for a recent ischemic episode.



**FIG. 1.** (A) Typical hypoxic exercise test on a normal subject. (B) Hypoxic exercise test on the patient.  $\dot{V}_e$  = minute ventilation;  $SaO_2$  = arterial  $O_2$  saturation,  $P_{ET}CO_2$ : end-tidal  $PCO_2$ .  $HVR_e$  is calculated as  $\Delta \dot{V}_e / \Delta SaO_2 / \text{body weight} \times 100$  [see Richalet et al. (2012) for more details].

Two months after the episode, she came to the altitude consultation. She is well and has resumed her engineering job. On her return from Ladakh, she complained of being a little “awkward” in some fine gestures and her entourage told her that her voice had changed a bit, but at the time of the consultation, all these troubles have disappeared, and the neurological examination is normal.

In her medical history, nothing special is worth mentioning, no hypertension, no hypercholesterolemia, no familial history of vascular event, and no migraine. She has an unexplored Raynaud’s syndrome, some episodes of vagal malaise. She occasionally complains of sinusitis (incidentally found on the MRI: left maxillary sinusitis with hydroaeric level). She takes no medication.

On examination, her lung auscultation was normal. Her EKG was normal, with a sinus rhythm and a qRS axis at 90°.

During the hypoxia exercise test, a very high ventilatory response to hypoxia at exercise was found (HVRe = 1.47 L/[min · kg]), the standard (mean ± standard deviation [SD]) value being 0.68 ± 0.33 L/(min · kg) (Fig. 1) (Richalet et al., 2012). End tidal PCO<sub>2</sub> at exercise in hypoxia was low (23.7 mmHg), the standard (mean ± SD) value being 35.2 ± 3.0 mmHg.

A transthoracic and transesophageal echocardiography revealed normal cardiac dimensions and contractility. Valves were normal. There was no persistence of foramen ovale (PFO, as explored by microbubbles injection). The Doppler of supra-aortic arteries was normal. A 24-hour EKG Holter revealed no rhythm disturbances. An assessment of hemostasis did not seem necessary.

## Discussion

Altogether, this is a rapidly resolving neurological disorder occurring at high altitude, in a young woman without medical history and perfectly acclimatized to high altitude.

The probable diagnoses were the following:

1. Embolic transient ischemic attack in the left carotid artery territory, given the visual disturbance in the left eye and the right arm sensory disturbances, but this does not explain the dizziness and the disorders of consciousness. Furthermore, no potential cause was found at the cardiovascular work-up (no PFO, normal EKG Holter, Doppler of supra-aortic arteries, and MRI).
2. Transient cerebral ischemia/hypoxia due to local cerebral vasoconstriction related to hyperventilation-induced hypocapnia (recent intense exhaustive exercise, dizziness, and baseline hyper-responsiveness to hypoxia).
3. High-altitude cerebral edema, but the rapid resolution and the absence of previous signs of AMS (headache, nausea, etc.) in a well acclimatized person do not favor this hypothesis. However, this is not exclusive, since cerebral edema may appear at very high altitude in acclimatized climbers (Clarke, 1988).
4. Migraine and high-altitude global amnesia cannot account for all aspects of clinical presentation. Nausea and photophobia were absent.

The hypothesis of a transient cerebral ischemic/hypoxic event seems the most likely to be the cause of this neurological disorder. It calls our attention about the possible

harmful effect of excessive hyperventilation at high altitude on cerebral tissue, combining hypoxemia and hypocapnia-induced vasoconstriction. Dizziness is a symptom that is part of the Lake Louise scoring system (The Lake Louise, 1992). However, it might be confusing since dizziness is likely due to hyperventilation-induced hypocapnia and hyperventilation is rather a sign of good acclimatization to high altitude, as shown in this case report. A hypoxia exercise test that evidenced a hyper-responsiveness to hypoxia is another argument in favor of this hypothesis.

Cases of transient ischemic attacks have been previously reported (Botella De Maglia et al., 1993; Cauchy et al., 2002), but this is the first case wherein the patient has been extensively explored at his return home. Focal manifestations of migraine have been described at high altitude (Cauchy et al., 2002; Broessner et al., 2016). The first symptoms (positive visual signs, dysphasia, and right arm sensory disturbances) indeed suggest a migrainous aura but a migraine attack would not explain that she soon after became unconscious. However the absence of migraine attacks before or after this episode is not in favor of this hypothesis. High-altitude global amnesia has been evoked in rare circumstances (Litch and Bishop, 2000; Bucuk et al., 2008). However, in this case, amnesia is not the pre-eminent symptom. Similar neurological symptoms may be caused by intense neuronal discharge or neuronal synchronization as a feature of cortical spreading depression (Firth and Bolay, 2004).

In conclusion, special attention should be given to subjects who show a hyper-responsiveness to hypoxia before a sojourn at high altitude: they should avoid any kind of stress, emotion, or exhaustive exercise that would induce inappropriate hyperventilation.

## Acknowledgments

We thank Mrs. M.D. who experienced this event for her authorization to publish her experience. We thank Pr. Marie-Germaine Bousser for her advice and careful reviewing of the article. We thank Dr. Michaël Obadia and Dr. Karen Benisty who participated in the evaluation of this patient.

## Author Disclosure Statement

No competing financial interests exist.

## Funding Information

No funding was received for this article.

## References

- Basnyat B, Wu T, and Gertsch JH. (2004). Neurological conditions at altitude that fall outside the usual definition of altitude sickness. *High Alt Med Biol* 5:171–179.
- Botella De Maglia J, Garrido Marin E, and Catala Barcelo J. (1993). Afasia motora transitoria a gran altitud. *Rev Clin Esp* 193:296–298.
- Broessner R, Rohregger J, Wille M, Lackner P, Ndayisaba JP, and Burtscher M. (2016). Hypoxia triggers high-altitude headache with migraine features: A prospective trial. *Cephalalgia* 36:765–771.
- Bucuk M, Tomic Z, Tuskan-Mohar L, Bonifacic D, Bralic M, and Jurjevic A. (2008). Recurrent transient global amnesia at high altitude. *High Alt Med Biol* 9:239–240.

- Cauchy E, Larmignat P, Boussuges A, Le Roux G, Charniot JC, Dumas JL, and Richalet JP. (2002). Case report: Clinical medicine: Transient neurological disorders during a simulated ascent of Mount Everest. *Aviat Space Environ Med* 73:1224–1229.
- Clarke C. (1988). High altitude cerebral oedema. *Int J Sports Med* 9:170–174.
- Firth PG, Bolay H. (2004). Transient high altitude neurological dysfunction: An origin in the temporoparietal cortex. *High Alt Med Biol* 5:71–75.
- Hackett PH, Hollingshead KF, Roach R, et al. (1987). Cortical blindness in high altitude climbers and trekkers—A report on six cases. In: *Hypoxia and Cold*. JR Sutton, CS Houston and G Coates, eds. New York: Praeger. p. 536.
- Litch JA, and Bishop RA. (2000). High-altitude global amnesia. Case report. *Wilderness Environ Med* 11:25–28.
- Richalet JP, Larmignat P, Poitrine E, Letourmel M, and Canoui-Poitrine F. (2012). Physiological risk factors for severe high-altitude illness: A prospective cohort study. *Am J Respir Crit Care Med* 185:192–198.
- The Lake Louise Consensus. (1992). The definition and quantification of altitude illness. In: *Hypoxia and Mountain Medicine*. JR Sutton, G Coates and CS Houston, eds. Queen City Printer, Burlington. pp. 327–330.

Address correspondence to:  
*Jean-Paul Richalet, MD, PhD*  
*INSERM U1272 Hypoxie et Poumon*  
*Université Paris 13*  
*74 rue Marcel Cachin*  
*Bobigny 93017*  
*France*

*E-mail: richalet@univ-paris13.fr*

Received August 30, 2019;  
accepted in final form November 25, 2019.