

Brain abscess – an unusual complication of cavernous sinus thrombosis

A case report

A.K. Mahapatra*

Introduction

Cavernous sinus thrombosis is a well known complication of facial, paranasal sinus and dental infection¹⁻⁵. Brain abscess as a complication of C.S.T. is well known but rare, and appears in the literature as case reports¹⁻⁹. In this paper such a case is reported where C.S.T. was most likely the cause of the brain abscess.

Case report

A 14-year-old girl was admitted to our unit with a history of headache and vomiting for 3 months and left frontal scalp swelling of one month duration. Eight months prior to admission she had a furuncle over the nose on the left side, which ruptured and discharged pus. Ten days later she developed high grade fever ranging from 102°-103°F, left sided proptosis and blurring of vision. There was conjunctival injection and periorbital swelling. The diagnosis of septic thrombophlebitis of the cavernous sinus was made, and the patient was treated at a civil hospital and made a good recovery. She remained well for next 3 months.

On admission she was conscious, oriented but had bilateral papilledema. She also had left sided third and sixth nerve paresis. Left eye was proptosed with periorbital oedema. There was small scalp swelling over the left posterior frontal region. There was no other site of infection. She had no history of acute or chronic ear dis-

Summary

An unusual case of multilocular brain abscess is reported in a 14-year-old girl, following cavernous sinus thrombosis. In absence of any other source of infection the cavernous sinus thrombosis is presumed as the cause of brain abscess. Possible pathogenesis is discussed.

Key words: Facial infection, cavernous sinus thrombosis (C.S.T.), brain abscess.

charge or congenital heart disease. Examination of chest, cardiovascular system or abdomen revealed no abnormality.

Her haemoglobin was 14.6 gm% and total leucocyte count was 6400/cu mm. Plain radiograph of the skull was normal and paranasal sinus view revealed no abnormality. A contrast enhanced C.T. scan showed a multiloculated left frontotemporal brain abscess with massive oedema and midline shift to the rightside, and scalp abscess overlaying the brain abscess (Fig. 1a, b).

The patient was treated with intravenous cloxacillin 500 mgs 8 hourly and Gentamycin 40 mg I/V eight hourly, however, patient deteriorated on seventh day after admission and became comatose. An emergency frontotemporal craniotomy was performed and a left temporal multilocular abscess was excised and left frontal

* Department of Neurosurgery, All India Institute of Medical Science, New Dehli, 110029, India.

Address for correspondence and reprint requests: A.K. Mahapatra, Department of Neurosurgery, A.I.I.M.S. New Dehli, 110029, India

Accepted 29.4.88

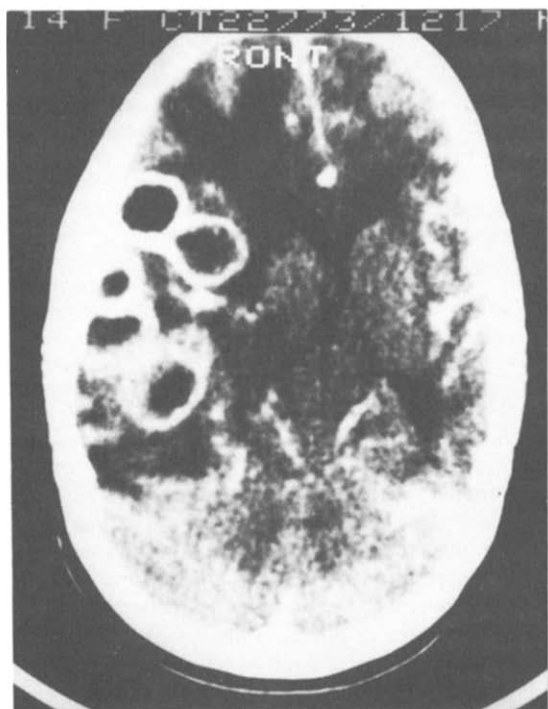


Fig. 1a. Contrast enhanced C.T. Scan shows left frontotemporal multiloculated brain abscess with massive oedema and midline shift to the right side.

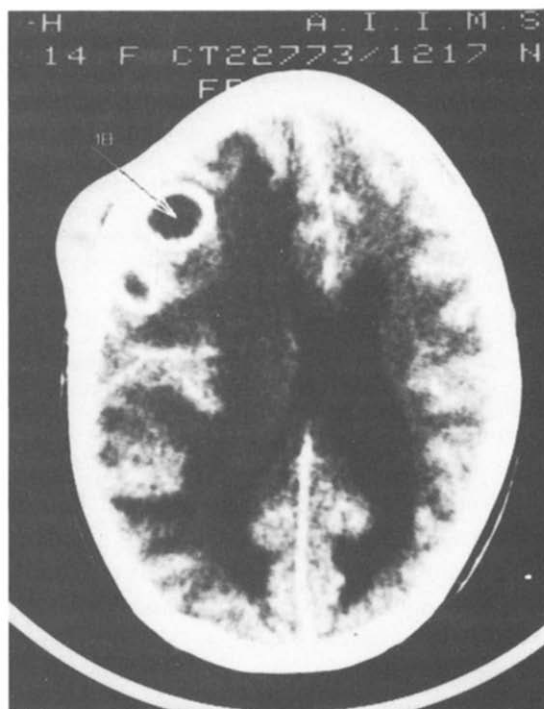
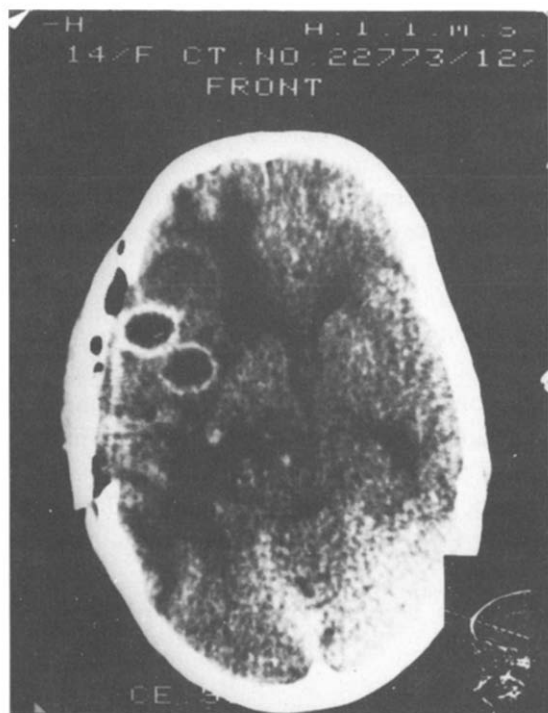


Fig. 1b. Contrast enhanced C.T. scan showing left frontal brain abscess with a scalp abscess overlying.

Fig. 2. Postoperative Contrast enhanced C.T. scan shows residual left frontal abscess.



abscess was aspirated. As the brain was still tense duraplasty was performed by using the temporalis fascia. Postoperatively antibiotics were continued and dilantin 100 mg twice daily was added. Pus culture grew *Staphylococcus aureus* and *Proteus Merabillis*, sensitive to Gentamycin and Cephalosporin, hence Cloxacillin was stopped and Cephalosporin was added.

Following surgery she developed right sided hemiplegia and expressive dysphasia. A repeat C.T. scan, performed one week following surgery (Fig. 2), showed residual left frontal abscess, which was subsequently reaspirated. Patient slowly improved over a period of 4 weeks and on discharge she had mild expressive dysphasia and $\frac{3}{5}$ right sided hemiparesis. On follow-up 3 months later her speech was normal, however, she had $\frac{4}{5}$ hemiparesis on the right side.

Discussion

Cavernous Sinus Thrombosis (CST) is a life threatening condition first described by Ducan in 1821¹⁰ and usually results from midfacial in-

fection, paranasal sinusitis or dental infection^{4,6,11-12}. Prior to the invention of the penicillin the mortality was 100%, however, because of the awareness of the condition and prompt action the mortality has come down significantly^{6,14}.

Intracranial infection is a well known complication following CST^{3,4,7}. There are only a few case reports of brain abscess as a complication of CST^{1-4,7}. Reports from India indicate that the chronic otitis media is still the most common cause of brain abscess and in about 20-25% of the cases no source of the infection^{15,16} is found. In the present case there was neither CSOM nor congenital heart disease. However, she definitely had CST 8 months prior to admission, while she suffered from headache and vomiting 5 months prior. Usual time interval between CST and development of a brain abscess has been reported to vary from 3 months to 6 months⁴. Hence CST as a possible cause of brain abscess in present case has been considered. Various modes of spread of infection from cavernous sinus has been postulated by many authors^{4,5,12,14}, and hematogenous spread is one of them. In that case the left frontal scalp abscess can well be explained by the hematogenous spread from the previous infection of the cavernous sinus, due to inadequate treatment. Thus the cause of the brain abscess in the present case as a consequence and CST is a distinct possibility.

Common sites of the abscess described in the literature are frontal and temporal lobes^{2,4,7}. Rarely cerebellar abscess has also been reported⁴. In our case the patient had a large fronto-temporal multilocular abscess.

Staphylococcus aureus is the commonest organism responsible for CST and the brain abscess following it^{4,7,12,13}. Rarely *Proteus*, *Pseudomonas* and *Bacteroides* have also been reported^{6,11}. In the present case pus culture grew *Staphylococcus aureus* and *Proteus Mirabilis*. It is rare to find two organisms.

The diagnosis of the brain abscess is easy, and when fever continues and focal convulsion or focal deficit appear after CST brain abscess should be suspected^{4,7}. Similar symptomatology could also be due to infarction in the brain¹⁴. The CT scan is invaluable in the diagnosis and follow-up of such lesions^{1,14}. In the present case CT

scan showed a multilocular brain abscess. Repeat CT scan post-operatively revealed residual abscess which was subsequently aspirated.

Before the discovery of penicillin mortality in cases of septic CST was as high as 90%-100%^{5,13}. Yarrington⁵ in a review of 878 cases of CST reported a mortality of 80%, however, his subsequent analysis in 1977 showed a significant fall in the mortality rate to 13.6%. This is largely because of the high index of suspicion, early diagnosis and the aggressive treatment. In our case, the patient made a good recovery. After the surgery for multilocular brain abscess, however, she developed a right sided hemiplegia and an expressive dysphasia. At the time of discharge from the hospital, 4 weeks after surgery she started to speak a few words and her power improved to 2-3/5. Follow-up 6 months later showed a good recovery.

References

- GOTINER D. *et al.* Cavernous sinus thrombophlebitis and brain abscess initiated and maintained by periodontally involved tooth. *J Oral Med* 1982; 37 (3):80-83.
- HOLLIN SA, NAYASHI H, CROSS SW. Intracranial abscess of odontogenic origin. *J Oral Surg* 1967; 23:277-93.
- TATOIAN JA, JR, LA DOW CS JR, DISQUE F *et al.* Meningitis and temporal lobe abscess of dental origin. Report of a case. *J Oral Surg* 1972; 30:423-9.
- TAYLOR PJ. Cavernous sinus thrombophlebitis. *Brit J Ophthalmol* 1957; 41:228-37.
- YARRINGTON CT JR. The prognosis and treatment of the cavernous sinus thrombosis; reviewed 878 cases in the literature. *Ann Otol Rhinol Laryngol* 1961; 70:263-7.
- YARRINGTON CT JR. Cavernous sinus thrombosis, revisited. *Prog R Soc Med* 1977; 70:456-9.
- MCALLEN PM, SHAW RE. Cavernous sinus thrombosis. A case due to penicillin resistant organism. *Brit J Surg* 1952; 40:49-52.
- CHILD CG, COURVILLE CB. Thrombosis of cavernous sinus secondary to dental infection. *Ame J Orthod* 1942; 28:367-9.
- RUSSEL A, FEARING SJ. Cavernous Sinus thrombosis in a diabetic. *Oral Surg Oral Med Oral Path* 1955; 8:372-5.
- DUCAN A. Contribution to morbid anatomy. *Edin Med Surg J* 1821; 17:321-36.
- EVANS HR. Cavernous sinus thrombosis. *Lancet* 1965; 85:109-13.
- SHAW RE. Cavernous Sinus Thrombophlebitis a review. *Brit J Surg* 1952; 40:40-48.
- GROVE WE. Septic and aseptic type of thrombophlebitis of Cavernous Sinus. *Arch Otolaryngol* 1936; 24:29-34.
- CLIFFORD TONES RF, ELLIS CJK, STAN STEUER JM, TURNER A. Cavernous sinus thrombosis. *J Neurol Neurosurg Psychiatr* 1982; 45:1092-7.
- MAHAPATRA AK, BHATIA R, BANERJI AK, TANDON PN. Subdural empyema in children. *Ind Pediatr* 1984; 21:561-7.
- BHATIA R, TANDON PN, BANERJI AK. Brain abscess-an analysis of 55 cases. *Int Surg* 1973; 58:565-8.