

Cerebral infarction in juvenile rheumatoid arthritis

A.K. Gururaj*, R. Pratap Chand* **, and S.P. Chuah*

Case report

Z.M., a 2-year-old female child was first hospitalized in 1984 for fever and polyarthritis and was diagnosed to have seropositive polyarticular juvenile rheumatoid arthritis and was treated with aspirin. The response was good. She was subsequently admitted in February 1986 at the age of 5 years with a history of fever and fits of one day duration. The fits consisted of clonic movements of the left upper and lower limbs, progressing to involve the right upper and lower limbs associated with uprolling of the eye balls. There was no loss of consciousness. The episode lasted for a few seconds and was followed by post-ictal drowsiness. There was no past history of fits. She was a product of full term normal delivery born to non-consanguineous parents and there was no history of birth asphyxia. Her development had been normal. Examination revealed a fully conscious child who was febrile and pale. Her vital signs were normal. There were swellings and deformities in both wrists and knee joints. Ulnar deviation of the hands at wrists was evident. Passive extension at the left knee was limited. No joint tenderness or contractures were found. Marked wasting of the muscles of the upper and lower limbs was observed. Neurologically, no deficits were elicitable. There was no hepatosplenomegaly or lymphadenopathy. The kidneys were not pal-

Summary

Cerebral involvement associated with juvenile rheumatoid arthritis is rare. It is not influenced by treatment and the presentation can be varied. We describe a case of cerebral infarction secondary to vasculitis in a child with juvenile rheumatoid arthritis.

Key words: Juvenile rheumatoid arthritis, cerebral vasculitis.

pable. Cardiovascular and respiratory systems were normal.

Following admission, the child continued to have fever and subsequently, her right ankle became painful. She had an episode of partial seizure involving the left upper and left lower limbs on the 3rd day. This was preceded by an aura of formed visual hallucination in which she repeatedly saw her sister falling down from a bed. Following the second fit, she developed left sided hypotonic hyporeflexic hemiparesis and left upper motor neurone type of facial palsy. Barring the post-ictal drowsiness, there was no altered sensorium. There was no detectable papilledema. On the 4th day, she was noted to have mild jaundice and areas of cutaneous vasculitis were observed on the planter aspect of her great toes (Fig. 1). The results of the investigations are shown in Table 1. The latex

* Department of Paediatrics and ** Department of Neurology, Hospital Universiti Sains Malaysia, Kubang Kerian, 16150 Kota Bharu, Malaysia

Address for correspondence and reprint requests: A.K. Gururaj, Department of Paediatrics, Hospital Universiti Sains Malaysia, Kubang Kerian, 16150 Kota Bharu, Kelantan

Accepted 15.4.88

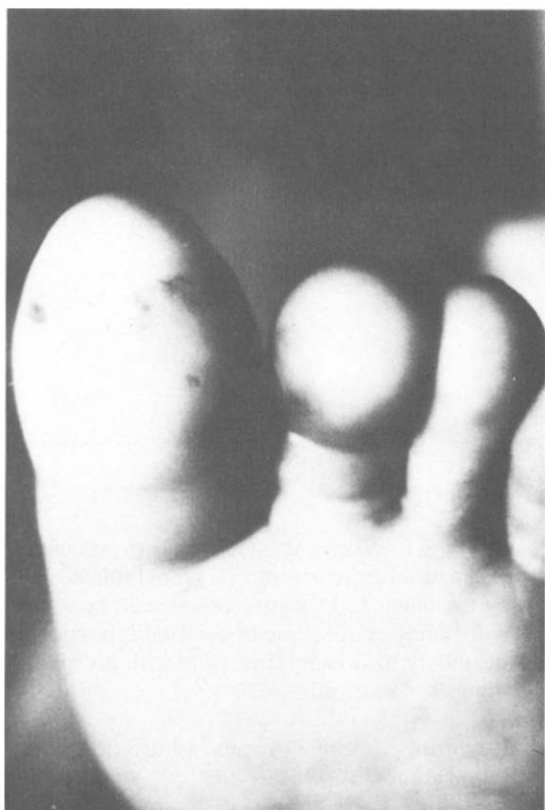


Fig. 1. Photograph showing cutaneous vasculitic lesions.

rheumatoid factor was positive 1:640 and ESR was 90 mm/hour. The electroencephalogram (EEG) revealed focal polymorphic delta activity indicating an acute structural cortical lesion in the right parieto-occipital region and focal epilepsy originating from the right posterotemporal and occipital regions. CT scan showed a low density non-enhancing lesion in the right occipital region with pressure effects on the occipital horn of the right lateral ventricle and posterior falx cerebri (Fig. 2).

The child continued to receive oral soluble aspirin (75 mg/kg/day). The fits were controlled with an intravenous Phenytoin infusion (7 mg/kg) followed by oral Phenytoin (5 mg/kg/day). Her neurological recovery was rapid, the hemiparesis and facial palsy improved within three days. Presently she is asymptomatic. No residual hemiparesis or hemianopia have been observed.

Discussion

Cerebral involvement associated with juvenile

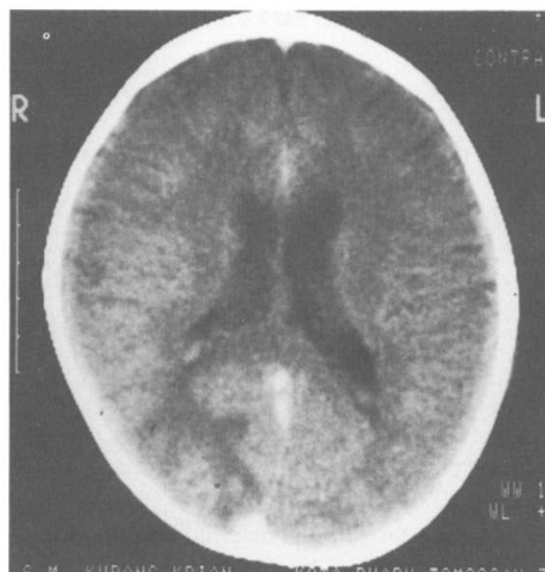


Fig. 2. The CT scan with enhancement showing cerebral infarction in the right occipital region.

rheumatoid arthritis (JRA) is rare but well documented. It may arise from cerebral vasculitis or rheumatoid nodules in the meninges or other intracranial structures¹. In a review of 170 cases, Jan *et al.* observed abnormal central nervous system functions in 13 (7.5 percent)². Dysfunction included drowsiness, seizures, irritability, incoordination, stupor, chorea, meningismus and papilledema. In all these cases, the spinal

Table 1

Investigation	Result	Normal Values
Serum bilirubin	69 μ mol/L	5-17 μ mol/L
Aspartate amino transferase	101 IU/L	5-15 IU/L
Alanine amino transferase	52 IU/L	4-12 IU/L
Hepatitis A Virus IgM	negative	
Hb S Ag	negative	
Cerebro spinal fluid		
Protein	0.4 g/L	0.15-0.6 g/L
Glucose	3.4 mmol/L	2.1-3.75 mmol/L
Chloride	124 mmol/L	120-130 mmol/L
Globulin	negative	
Immunoglobulins		
IgG	19.7 g/L	5-13 g/L
IgM	3.92 g/L	0.5-1.99 mg/L
IgA	4.85 g/L	0.23-1.9 mg/L
Blood		
Urea	4.0 mmol/L	3.0-6.0 mmol/L
Sodium	141 mmol/L	135-145 mmol/L

fluid was essentially clear. Jacksonian epilepsy resulting from focal intracranial lesion was first reported by Ellman *et al.* in 1954³, and is reported to be a less common manifestation. In the present report, the patient had complex partial seizures as evidenced by the aura and motor manifestations. The EEG described in JRA include persistent or intermittent diffuse slowing of the background activity, or asymmetries of different degrees^{14,5}. The abnormal EEG findings are known to occur more often in girls than in boys and are associated with active disease. The EEG changes seen in this patient are similar to that described in the literature. The CT scan in this patient is suggestive of infarction possibly secondary to vasculitis. Vasculitis in JRA is characterized by fibrinoid necrosis of the media and inflammatory cell infiltration of the adventitia. Vasculitis can result in a variety of neurological syndromes mostly related to sequelae of vascular obliteration, thrombosis followed by infarction or rupture and haemorrhage¹. The symptoms depend on the anatomical location of the lesion and the extent of the area involved. Rarely, the cerebral manifestations in JRA can be secondary to hypertensive encephalopathy associated with the use of steroids or hyperviscosity syndrome secondary to excessive serum proteins, such as cryoglobulinemia and cir-

culating IgG Complexes. The neurological progression may or may not be reversed by anti-inflammatory drug therapy. In the present case, the cerebral infarction occurred when the patient was on Aspirin. Apart from Phenytoin, no other drugs were given and the child eventually made a full neurological recovery.

In conclusion, we present a case of seropositive JRA with a focal neurological involvement due to cerebral infarction possibly secondary to vasculitis.

References

- ¹ MAKELA AL., LANG H, SILLANPAA M. Neurological manifestations of rheumatoid arthritis. In: Vinken PJ and Bruyn GW (Eds.) Handbook of clinical neurology Part 1. Amsterdam: North Holland Publishing Company. 1979; 38:470-99.
- ² JAN JE, HILL RH, LOW MD. Cerebral Complications in juvenile rheumatoid arthritis. Can Med Assoc J 1972; 107:623-5.
- ³ ELLMAN P, CUDKOWITS L, ELWOOD JS. Widespread serous membrane involvement by rheumatoid nodules. J Clin Path 1954; 7:239-44.
- ⁴ SILLANPAA M, LANG AH, KALIMO H. Natural history of juvenile rheumatoid arthritis. Acta paediatr Scand 1978; 67:537-41.
- ⁵ LANG H, ANTTILA R, SVEKUS A, LAAKSONEN AL. EEG findings in juvenile rheumatoid arthritis and other connective tissue diseases in children. Acta Paediatr Scand 1974; 63:373-80.