

Aphonia as the only speech disturbance from bilateral paramedian thalamic infarction

L.G. Lazzarino*, and A. Nicolai*

Introduction

Amnesia and oculomotor disturbances are frequently reported as a consequence of bilateral paramedian thalamic lesions¹⁻¹³. Although less frequent, language disorders after left or bilateral thalamic injury are also described^{8,14-18}. A lowered or fading voice may be present^{15,17,18}, but has never been described as the only speech disorder. We report a patient with CT documented bilateral paramedian thalamic infarction who presented with transient coma followed by vertical gaze paralysis, mild right hemiparesis, severe amnesia and aphonia without other speech anomalies.

Case history

A 55-year-old right-handed woman was hospitalized because of abrupt onset of unresponsiveness and urinary incontinence. Her past health was good apart from long-standing mild untreated hypertension. On admission pulse was 80 and regular, blood pressure was 180/100; Cheyne-Stokes respiration was also present. She appeared somnolent and passive, but she was able to follow simple verbal commands and, when prodded, she produced fluent speech without verbal or literal paraphasias. However her speech was scarcely intelligible because of considerable lowering of voice volume. The pupils were small (2 mm) and sluggish. Vertical gaze, in both directions was impossible either on

Summary

We examined a 55-year-old right-handed woman showing transient coma, amnesia, mild right hemiparesis, vertical gaze impairment and aphonia without aphasia. CT-scanning revealed bilateral paramedian thalamic infarction in the territory of the thalamo-subthalamic paramedian arteries. Aphonia may occur as a consequence of thalamic lesions, but until now it has not been described as an isolated speech disturbance.

Key words: Cerebro-vascular disease, infarction, speech disorder

pursuit or on saccadic movements. Horizontal gaze was normal. The doll's-head maneuver resulted in vertical deviations which were impossible on voluntary efforts. A mild right hemiparesis was noted. Over the next three days the level of consciousness improved and the right hemiparesis cleared; the limitation of the upward gaze decreased. An enhanced high resolution CT scan was performed nine days after admission and showed a low density area involving both paramedian thalami, more extensive on the left side (Fig. 1).

Neuropsychological assessments were carried out at 2 weeks and 5 months from the admission. Each examination started with careful assessment of attention which was tested by Toulouse-Pierron barrage test, counting backward, digit

* *Divisione Neurologica Ospedale Civile Gorizia (Italia)*

Address for correspondence and reprint requests: Aldo Nicolai, Via Eleonora Duse n 22, 34170 Gorizia (Italia)

Accepted 11.4.88

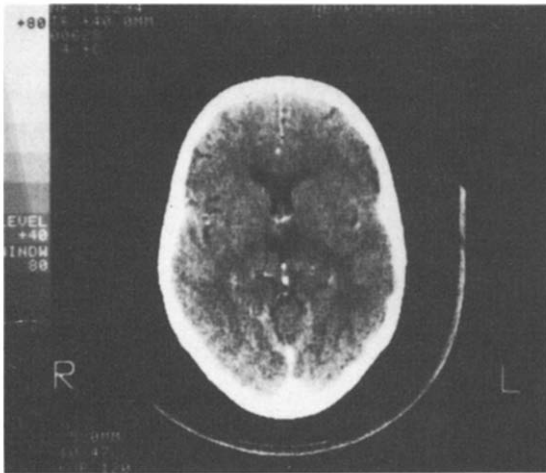


Fig. 1. Enhanced CT-scan (9 days after onset) showing ischaemic involvement of both paramedian thalamic sides, more extended on the left side.

span (Table 1) and by some subtests of spatial exploration and perception (identification of superposed configurations, identifications of colours): the results were almost normal, after allowance for the memory disturbances. Memory impairment evaluated according to the Bisiach's and coll. Method for Neuropsychological Evaluation²⁰ showed both anterograde and retrograde memory impairment for serial, associative, and logical modalities, while visual memory was well retained (Table 2). No hemispatial inattention, extinction to double simultaneous stimulations, astereognosis, right-left disorientation or apraxia were present. Reasoning was normal. On the Wechsler Adult Intelligence Scale only amnesic deficits were detected, the patient reacting within the normal mental range on all but memory subtests. She was aphonic, but the language she was able to whisper was normal on the Boston Diagnostic Aphasia Examination. Five months after the onset, the memory impairment was basically unmodified (Table 2). A marked improvement of vertical gaze paralysis and of voice volume was also noted.

Discussion

The paramedian thalamic areas are supplied by perforating branches (anterior thalamo-subthalamic paramedian arteries) arising from the posterior cerebral arteries between the basilar

Table 1. Examination of attention

	P.S.		N.S.
	2 weeks	5 months	
Toulouse-Pierron's barrage test			
Time min	16	16	11 ± 6 min
Errors n	27	21	≤25 errors
Digit span			
Forward	5	5	≥5 forward
Backward	4	4	≤3,5 backward
Counting backward			
Times s.	20	15	≤11 sec.
Errors n	3	0	

P.S. = Patient's scores; N.S. = Normal scores.

bifurcation and the origin of the posterior communicating artery. Occasionally a common artery from one side may supply both paramedian sides of the thalamus. This variation accounts for the simultaneous occurrence of bilateral infarcts^{2,21} that usually cause transient coma followed by neuro-ophthalmologic symptoms, drowsiness, abrupt amnesia¹⁻¹³, dementia and aphasic disturbances^{1,2,5,7,12}. Aphasia from left or bilateral thalamic lesions has been frequently described, although there is uncertainty about its semeiologic characteristics and the role of the dominant thalamus in generating language^{2,8,13-19}. A lowered or faded voice is quite common as a consequence of thalamic lesions^{15,17,18} and appears to reflect an elementary speech disturbance rather than an aphasic disorder¹⁸. However, the pathogenesis of this aphonia is not yet known. Gorelick *et al*¹⁸ suggest that the anatomic basis for the defect may be the interruption of fibres from the medial globus pallidus and pars reticularis of the substantia nigra, running along the ansa lenticularis

Table 2. Neuropsychological test for memory

	P.S.		N.S.
	2 weeks	5 months	
Verbal memory			
- Digit span (see Table 1)			
- Learning of paired words			
Easy pairs (7,50)	5	6	6,88 ± 0,5
Difficult pairs (15)	8	9	11,36 ± 1,12
Total (22,5)	13	15	18,24 ± 1,17
- Recall of logical stories	8	8	14,2 ± 4,6
- Learning of 3 series of words (30)	7	7	≥13,8 ± 3,8
Visual memory			
- Recall of configurations after 2 min.	good	good	
- Memory for faces	good	good	

P.S.: Patient's Scores. N.S.: Normal Scores

and carrying extrapyramidal inputs to VA and rostral portion of VL nucleus of the thalamus. Conventional CT, in which 10 mm slices are used, has only a limited capacity to localize the specific nuclei affected¹³. In the case under discussion we could only establish the ischaemic involvement of both paramedian thalami, but the CT-scan findings (Fig. 1) did not allow more detailed (i.e. nuclear) anatomical identification accounting for the decrease in voice volume. Precise analysis of thalamic ischaemic lesions by stereotaxic localization or Nuclear Magnetic Resonance^{13,22} should supply further insights into the role of the thalamus in the origin of aphasia.

References

- 1 CASTAIGNE P, BUGÉ A, CAMBIER J, ESCOUROLLE R, BRUNET P, DEGOS JD. Démence thalamique d'origine vasculaire par ramollissement bilatéral limité au territoire du pédicule rétro-mammillaire. A propos de deux observations anatomo-cliniques. *Rev Neurol* 1966; 114:89-107.
- 2 CASTAIGNE P, LHERMITTE F, BUGÉ A, ESCOUROLLE R, HAUW JJ, LYON-CAEN O. Paramedian thalamic and midbrain infarcts: clinical and neuropathological study. *Ann Neurol* 1981; 10:127-48.
- 3 PETIT H, ROUSSEAU M, CLARISSE J, DELAFOSSE A. Troubles oculocéphalomoteurs et infarctus thalamo-subthalamique bilatéral. *Rev Neurol* 1981; 137:709-22.
- 4 BARBIZET J, DEGOS JD, LOUARN F, NGUIEN JP, MAS JL. Amnésie par lésion ischémique bithalamique. *Rev Neurol* 1981; 137:415-24.
- 5 GUBERMAN A, STUSS D. The syndrome of bilateral paramedian thalamic infarction. *Neurology* 1983; 33:540-6.
- 6 MILLS RP, SWANSON PD. Vertical oculomotor apraxia and memory loss. *Ann Neurol* 1978; 4:149-53.
- 7 VAN CRAMON DY, HEBEL N, SCHURI U. A contribution to the anatomic basis of thalamic amnesia. *Brain* 1985; 108:993-1008.
- 8 MICHEL D, LAURENT B, FOYATER N, BLANC A, PORTAFAIX M. Infarctus thalamique paramédian gauche. Étude de la mémoire et du langage. *Rev Neurol* 1982; 138:533-50.
- 9 HALMAYI GM, EVANS WA, HALLIAN JM. Failure of dawnward gaze. *Arch Neurol* 1978; 35:22-6.
- 10 SMITH MS, LAGUNA JF. Upward gaze paralysis following unilateral pretectal infarction: a computerized tomography correlation. *Arch Neurol* 1981; 38:127-9.
- 11 AUERBACH S, DE PIERO TJ, ROMANUL F. Sylvian aqueduct syndrome caused by unilateral midbrain lesions. *Ann Neurol* 1982; 11:91-4.
- 12 GRAFF-RADFORD NR, DAMASIO H, YAMADA T, ELSINGER PJ, DAMASIO AR. Nonhaemorrhagic thalamic infarction. Clinical, Neuropsychological findings in four anatomical groups defined by computerized tomography. *Brain* 1985; 108:485-513.
- 13 MORI E, YAMADORI A, MITANI Y. Left thalamic infarction and disturbance of verbal memory: a clinicoanatomical study with a new method of computed tomographic stereotaxic localization. *Ann Neurol* 1986; 20:671-6.
- 14 ELGHOZI D, STRUBE E, SIGNORET JL, CAMBIER J, LHERMITTE F. Quasi aphasia lors de lésions du thalamus. Relation du trouble du langage et de l'activation élective de l'hémisphère gauche dans l'observation de lésions thalamiques gauches et droites. *Rev Neurol* 1978; 134:557-74.
- 15 DEMEURISSE G, DEROUCK JL, COEKAERTS MJ, DELTERNE P, VAN NECHEL C, DEMOL O, CAPON A. Study of two cases of aphasia by infarction of the left thalamus without cortical lesions. *Acta Neurol Belg* 1979; 79:450-9.
- 16 DAVOUS P, BIANCO C, DUVAL-LOTA AM, DERECONDO J, VEDRENNE C, RONDOT P. Aphasia par infarctus thalamique paramédian gauche. Observation anatomo-clinique. *Rev Neurol* 1984; 140:711-9.
- 17 CIEMENS VA. Localized Thalamic hemorrhage: a cause of aphasia. *Neurology* 1970; 20:30-43.
- 18 GORELICK PB, HIER DB, BENEVENTO L, LEVIT S, TAN W. Aphasia after thalamic infarction. *Arch Neurol* 1984; 41:1296-8.
- 19 CROSSON B. Role of the dominant thalamus in language: a review. *Psych Bull* 1984; 96:491-517.
- 20 BISIACH E, CAPPAS, VALLAR G. Guida all'esame neuropsicologico. Milano: Raffaello Cortina Editore, 1983.
- 21 PERCHERON G. Les artères du thalamus humain: II artères et territoires thalamiques paramédians de l'artère basilaire communicante. *Rev Neurol* 1976; 132:309-24.
- 22 GRAFF-RADFORD NR, SCHELPER RL, ILINSKI IA, DAMASIO H. Computed-tomographic and post mortem study of non-haemorrhagic thalamic infarction. *Arch Neurol* 1985; 42:761-3.