

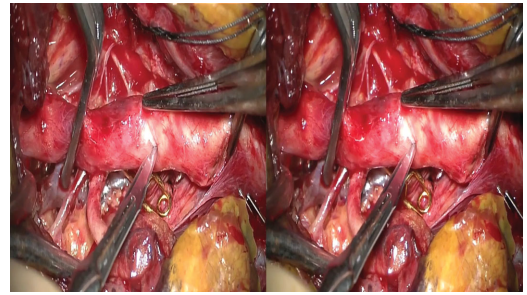
Left Vertebral Artery to Common Carotid Artery Transposition in a Patient With Bilateral Vertebral Insufficiency: 3-Dimensional Operative Video

Sirin Gandhi, MD, Claudio Cavallo, MD, Justin R. Mascitelli, MD, Michael J. Nanaszko, MD, Xiaochun Zhao, MD, Michael T. Lawton, MD 

Department of Neurosurgery, Barrow Neurological Institute, St. Joseph's Hospital and Medical Center, Phoenix, Arizona

Correspondence: Michael T. Lawton, MD, Neuroscience Publications, Barrow Neurological Institute, St. Joseph's Hospital and Medical Center, 350 W Thomas Rd, Phoenix, AZ 85013, USA. Email: Neuropub@barrowneuro.org

Copyright © 2020 by the Congress of Neurological Surgeons



Watch now at <https://academic.oup.com/ons/advance-article-lookup/doi/10.1093/ons/opaa001>

Extracranial vertebral artery (VA) atherosclerosis is responsible for 14% to 32% of posterior circulation infarctions.¹ In the posterior circulation, narrowing of the VA > 30% is significantly associated with strokes. Subclavian artery (SCA) atherosclerosis can produce subclavian steal. Retrograde VA flow around an occluded SCA decreases blood flow to the posterior circulation and causes vertebrobasilar insufficiency (VBI). Flow augmentation to the posterior circulation can be achieved by VA endarterectomy, arterial stenting, VA-common carotid artery (CCA) transposition, or bypass using an interposition graft.^{2,3} This video illustrates microsurgical revascularization of the proximal VA with VA-CCA transposition. A 58-yr-old man with a prior stroke and chronic right VA occlusion presented with dysarthria and gait instability. Angiographic evaluation confirmed complete midcervical right VA occlusion and left SCA occlusion proximal to VA origin, with subclavian steal. After obtaining patient consent and a failed attempt at endovascular recanalization of the left SCA, a left

VA-CCA end-to-side transposition was performed. Neck dissection exposed the left CCA. The thyrocervical trunk served as a landmark to identify the SCA, which was traced proximally to the VA origin. After proximal occlusion, the VA was transected and “fish-mouthed” for end-to-side anastomosis to CCA. An intraluminal, continuous suture technique was used to sew the back walls of this anastomosis. Postoperative computed tomography angiography confirmed bypass patency. Collateral circulation through the thyrocervical and costocervical trunks likely supplied the left arm, and no cerebral, or limb, ischemic symptoms were noted on follow-up. VA-CCA transposition is an uncommon technique for safe and effective revascularization of symptomatic, medically refractory VBI caused by VA occlusion or, as in this case, SCA occlusion with secondary subclavian steal. Used with permission from Barrow Neurological Institute, Phoenix, Arizona.

KEY WORDS: Cerebral revascularization, Subclavian steal syndrome, Vertebral artery occlusion, Vertebrobasilar insufficiency

Operative Neurosurgery 0:1–2, 2020

DOI:10.1093/ons/opaa001

Received, July 13, 2019. Accepted, December 1, 2019.

Disclosures

The authors have no personal, financial, or institutional interest in any of the drugs, materials, or devices described in this article.

REFERENCES

1. Bogousslavsky J, Van Melle G, Regli F. The Lausanne Stroke Registry: analysis of 1,000 consecutive patients with first stroke. *Stroke*. 1988;19(9):1083-1092.

2. Rangel-Castilla L, Kalani MY, Cronk K, Zabramski JM, Russin JJ, Spetzler RF. Vertebral artery transposition for revascularization of the posterior circulation: a critical assessment of temporary and permanent complications and outcomes. *J Neurosurg*. 2015;122(3):671-677.
3. Hanel RA, Brasiliense LB, Spetzler RF. Microsurgical revascularization of proximal vertebral artery: a single-center, single-operator analysis. *Neurosurgery*. 2009;64(6):1043-1050; discussion 1051.

Acknowledgments

The authors thank the staff of Neuroscience Publications at Barrow Neurological Institute for assistance with manuscript and video preparation.

COMMENT

The authors present a unique case of vertebrobasilar insufficiency related to subclavian artery occlusion and consequent subclavian steal, treated with a vertebral artery to common carotid artery trans-

position. This video highlights a successful approach to flow augmentation of the posterior circulation, performed in an era where endovascular approaches generally predominate over transposition and bypass procedures.

The value of this video is in demonstrating that the surgical treatment of stroke should be in the hands of a cerebrovascular neurosurgeon and the subclavian artery lies well within the anatomic boundaries of this specialty. The comprehensive anatomical knowledge and technical skillset demonstrated in this video is what enables us to provide patients with the best individualized treatment approach, and achieve great outcomes.

Theresa A. Elder
Joseph G. Adel
Saginaw, Michigan