

Case Report

Recurrent intracranial hemorrhage and cerebral venous sinus thrombosis: an atypical case of Neuro-Behçet's Syndrome

Fabrizio Giammello^a, Cristina Dell'Aera^a, Francesco Grillo^a, Masina Cotroneo^{a,*}, Carmela Casella^a, Maria Carolina Fazio^a, Paolino La Spina^a, Isabella Francalanza^a, Alessia Fiorenza^b, Antonio Toscano^a, Fabiola Atzeni^b, Rosa Fortunata Musolino^a

^a Department of Clinical and Experimental Medicine, AOU Policlinico G. Martino, University of Messina, Messina, Italy

^b Rheumatology Unit, University of Messina, Italy

ARTICLE INFO

Keywords:
Neurobehçet
PACNS
CVST
anti-TNF- α

ABSTRACT

We report the case of a 22-year-old man with an history of headaches, seizures, cognitive impairment associated with recurrent intracranial hemorrhage (ICH), acute ischemic stroke (AIS), worsened over the last eighteen months for a new onset of uveitis and cerebral venous sinus thrombosis (CVST). After excluding common causes of lobar ICH, and some rare ones according to the diagnostic protocol proposed by Beuker et al, in the suspicion of Primary Angiitis of the Central Nervous System (PACNS), the gradual development of a low-grade fever, a cutaneous rash, and a papulopustular manifestation on lower back after rachicentesis (pathergy phenomenon), allowed us to make a diagnosis of Neuro-Behçet's Syndrome (NBS) without oral/genital aphthous ulcerations, according to the International Study Group for Behçet's Disease classification criteria for BD (ICBD).

1. Introduction

Behçet disease (BD) is an idiopathic, chronic relapsing, multisystem, vascular-inflammatory disease with unknown etiology, more common in men and usually seen in the third decade with recurrent buccal aphthosis, genital ulcer and uveitis with hypopyon [1].

Neurologic involvement or Neuro-Behçet's Syndrome (NBS) occurs in about 4-49% of patients with BD and may be caused by either primary parenchymal lesions or vascular damage. NBS is classified in two major forms: parenchymal-NBS (P-NBS) and nonparenchymal-NBS (NP-NBS). P-NBS, which is caused by parenchymal pathology, accounts for the majority of NBS (75% of NBS cases). Parenchymal-NBS is featured by diffuse brainstem, cerebral, optic, and spinal cord symptoms. On the other hand, NP-NBS, which is usually caused by occlusion or hemorrhage of the main vascular structures is relatively rare, with a frequency reported 10 to 20% of all NBS patients. Cerebral venous sinus thrombosis (CVST), pseudo-tumor like intracranial hypertension and acute meningeal syndrome revealed for MRI imaging, intra-extracranial aneurysms are common forms of NP-NBS [2]. NBS should be considered in the differential diagnosis of stroke in young adults, neoplastic and paraneoplastic syndromes, multiple sclerosis, central nervous system (CNS) vasculitides, sarcoidosis, CNS infections and other neurologic syndromes [3]. Among NBS mimics, primary angiitis of the central

nervous system (PACNS) is a rare and severe disease, responsible for approximately 3–5% of cerebrovascular events in patients aged < 50 years. In PACNS, inflammation affects the blood vessels supplying the brain parenchyma, spinal cord and leptomeninges and less frequently veins and venules, resulting in poor blood circulation, blood vessel ruptures and intracranial haemorrhage [4].

2. Case report

We report the case of S.G, a 22-year-old man with a history of recurrent ICH, associated with headaches, seizures, cognitive impairment. The patient received multiple anti-epileptic drugs (AED) treatment and had several hospitalization from December 2017 to June 2019 without a diagnosis. The patient was admitted to Stroke Unit of University Hospital "G. Martino" in April 2019. Neurological examination showed: ideomotor slowdown, impaired spatial and temporal orientation, ataxic gait, unilateral ptosis with ipsilateral miotic and poor reactive pupil associated with conjunctival injection in the left eye, asymmetry of deep tendon reflexes with right-side prevalence, postural and intention tremors in right hand. Neurocognitive assessment found memory, attention, and frontal executive functions impairment with Mini-Mental State Examination (MMSE) of 19.19 (normal > 23). Laboratory routine tests, acute phase reactants, rheumatoid factor, antinuclear antibodies,

* Corresponding author.

E-mail address: cotroneomasina@gmail.com (M. Cotroneo).

<https://doi.org/10.1016/j.clineuro.2020.105680>

Received 3 December 2019; Received in revised form 10 January 2020; Accepted 13 January 2020

Available online 15 January 2020

0303-8467/ © 2020 Elsevier B.V. All rights reserved.

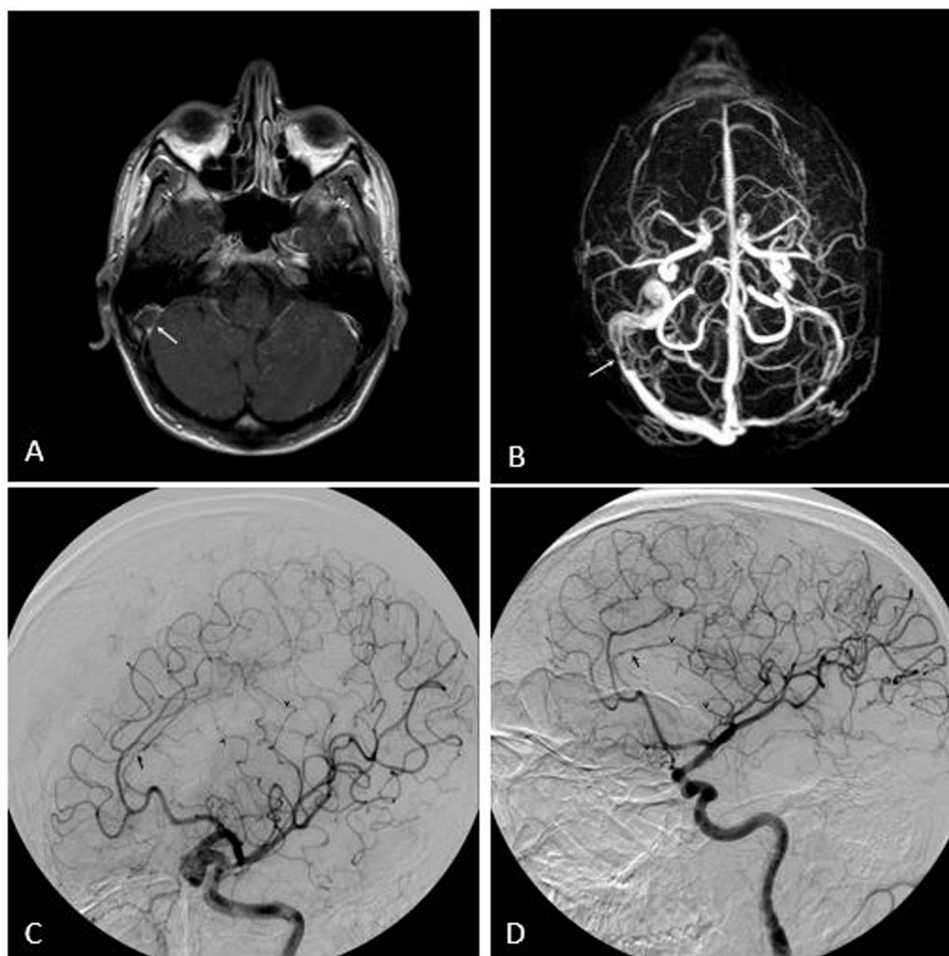


Fig. 1. Cerebral vascular alterations. (A) An axial contrast enhanced T1 MRI with gadolinium demonstrating a filling defect at the right sigmoid sinus (with the arrow) and (B) TOF MRI showing CSVT (white arrow); (C-D) DSA showing diffuse arterial stenosis and dilatation (black arrows).

antineutrophil cytoplasmic antibodies, antiphospholipid antibodies, HIV tests, viral antibodies for CMV, EBV, VZV, Herpes Simplex 1-2, measles, parotitis and hepatotropic virus, tumor markers were normal, with the exception of serum beta 2-microglobulin levels (4327.50 ng/ml; normal range 900.00–2700.00). Cerebrospinal fluid (CSF) showed 18 cells/ml (range 0–5), total protein concentration 150 mg/dL (range 20–50) and the presence of oligoclonal bands in serum and CSF. Serial magnetic resonance tomography (MRI) exams showed multiple lobar intracranial hemorrhage (ICH) and acute ischemic stroke (AIS) with hemorrhagic transformation (HT) in long TR sequences in the cortical and subcortical structure of the frontal and parietal lobes, associated with cerebral venous sinus thrombosis (CVST) and leptomeningeal enhancement after somministration of gadolinium. Digital subtraction angiography (DSA) showed diffuse, bilateral and alternating areas of arterial stenosis and dilatation (beading) and multifocal venous occlusions (Fig. 1). ^{11}C -Pittsburgh compound B positron emission tomography (PiB-PET) showed no rise in amyloid tracer uptake. CSF biomarkers β -amyloid ($\text{A}\beta$)₄₂, $\text{A}\beta$ ₄₀, total tau (t-tau) and phosphorylated tau (p-tau) did not show alterations. Cerebral biopsy has not been performed. The ophthalmologic examination showed plastic and exudative iridocyclitis in the left eye with potato-like keratic precipitates with a positive Tyndall test. The rheumatological assessment found Human leucocyte antigen (HLA)-B51 positive and a papulo pustular rash on the lower back. Nail fold videocapillaroscopy found enlargement and tortuosity of the capillaries, with sub- and peri-ungual oedema. During hospitalization corticosteroid pulse therapy with methylprednisolone (1 g/day for 5 days) was initiated, followed by oral

prednisolone (1 mg/kg for 4 weeks) plus azathioprine (2 mg/kg/day) with tapering oral steroids as maintenance therapy reported in literature [5]. One month after the dosage of corticosteroid was reduced, the patient developed right hemiparesis (National Institutes of Health Stroke Scale – NIHSS: 8) due to a new AIS with HT (Fig. 2). Because the clinical findings were corticosteroid-dependent and refractory, the patient was begun on infliximab, an anti-TNF- α monoclonal antibody. He received intravenous injections of infliximab at a dose of 5 mg/kg in week 0, 2, 6 and then every 8 weeks. Before started infliximab, we found a positive Quantiferon Tuberculosis (TB) gold - test and treatment for latent TB infection (LTBI) has been administered. The cutaneous and ocular symptoms resolved soon after the initiation of infliximab. The patient showed a significant clinical improvement in cognitive functions and in ocular and motor symptoms (NIHSS: 3). No meaningful adverse effects of infliximab were observed during follow ups.

3. Discussion

After excluding common causes of lobar ICH, we considered some rare ones and, in the suspicion of PACNS, we applied the diagnostic protocol proposed by Beuker et al., which includes the analysis of clinical features, laboratory tests, CSF, MRI, DSA and brain biopsy. We have satisfied 5 to 6 criteria of Beuker et al. for PACNS diagnosis (in the absence of tissue confirmation), but the association with uveitis is very rare in this disease [4]. The previous findings drove us to investigate for the presence of NBS without oral aphthous ulcerations, according to the International Study Group for Behçet's Disease classification criteria for

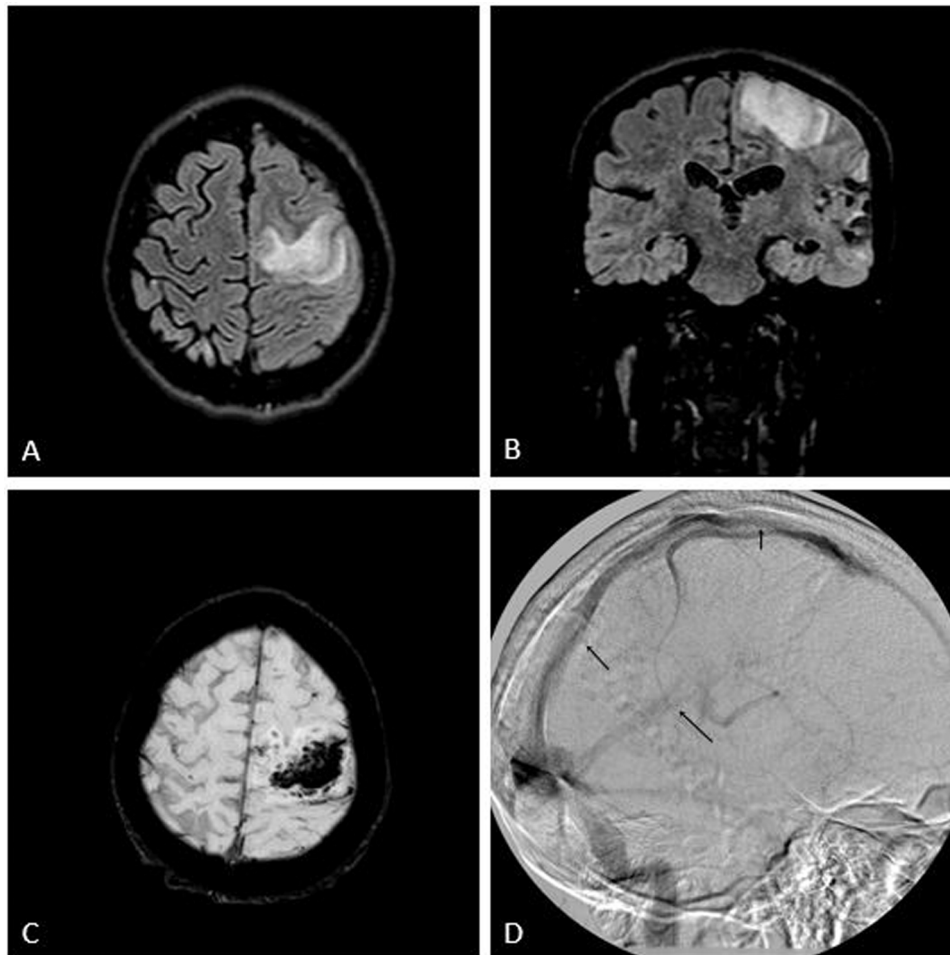


Fig. 2. New AIS. (A-B) FLAIR and (C) SWI MRI imaging; (D) DSA showing CSVT (black arrows).

BD (ICBD) [1]. The second most common form of neurologic involvement in BD is CVST (12–20%), localizing in superior sagittal sinus, transverse sinuses, deep cerebral veins, and cavernous sinuses. The papulo-pustular rash on lower back was observed one day after rachicentesis around the same site of lumbar puncture. After the first intravenous injections of infliximab, the patient presented an analogous rash on trunk. It could be considered as pathergy phenomenon, a non-specific skin hypersensitivity that is almost specific for BD, when induced by inserting an 18-G into the dermis of the forearm. The reaction is considered positive if either a papule, a pustule, or an ulcer forms at the puncture site within 48 hours [2]. According to the ICBD classification criteria, the presence of eye and skin lesions associated with CVST and AIS is highly suggestive of NP-NBS [1]. Interesting that our patient has a LTBI and recent laboratory and clinical findings include the discovery of antibodies to human and mouse neuro-fibrils showing cross-reactivity with *Streptococcus* spp. and *Mycobacterium tuberculosis* heat shock proteins (HSP) in NBS [2]. NBS attacks can be treated with glucocorticoids alone or in combination with azathioprine. For patients with relapsing-remitting or progressive courses, shifting to more potent immunosuppressive drugs such as mycophenolate, methotrexate, cyclophosphamide, or targeted therapy is warranted. Administration of cyclosporine has been reported to be associated with the development of acute neurological attacks and accordingly should not be advocated in NBS patients. For NBS and CVST, immunosuppressive drugs with or without anticoagulation are suggested [3]. At present, after multiple AED, corticosteroid immunosuppressive and infliximab therapy the patient hasn't had other relapses from June 2019 up to six-month follow-up.

4. Conclusion

The identification of NBS mimics is often challenging in clinical practice, but crucial to avoid far-reaching treatment decisions and to demonstrate the effectiveness of immunosuppressive therapies in a refractory case of NBS.

References

- [1] F. Davatchi, S. Assaad-Khalil, K.T. Calamia, J.E. Crook, B. Sadeghi-Abdollahi, M. Schirmer, T. Tzellos, C.C. Zouboulis, M. Akhlagi, A. Al-Dalaan, Z.S. Alekberova, A.A. Ali, A. Altenburg, E. Arromdee, M. Baltaci, M. Bastos, S. Benamour, I. Ghorbel, A. Boyvat, L. Carvalho, W. Chen, E. Ben-Chetrit, C. Chams-Davatchi, J. Correia, J. Crespo, C. Dias, Y. Dong, F. Paixao-Duarte, K. Elmuntaser, A.V. Elonakov, J. Grana Gil, A.A. Haghdoost, R.M. Hayani, H. Houman, A.R. Isayeva, A.R. Jamshidi, P. Kaklamanis, A. Kumar, A. Kyrgidis, W. Madanat, A. Nadji, K. Namba, S. Ohno, I. Olivieri, J. Vaz Patto, N. Pipitone, M.V. de Queiroz, F. Ramos, C. Resende, C.M. Rosa, C. Salvarani, M.J. Serra, F. Shahrman, H. Shams, K.E. Sharquie, M. Sliti-Khanfir, T. Tribolet de Abreu, C. Vasconcelos, J. Vedes, B. Wechsler, Y.K. Cheng, Z. Zhang, N. Ziaei, The International Criteria for Behçet's Disease (ICBD): a collaborative study of 27 countries on the sensitivity and specificity of the new criteria, *J. Eur. Acad. Dermatol. Venereol.* 28 (March (3)) (2014) 338–347.
- [2] M. Ishido, N. Horita, M. Takeuchi, E. Shibuya, T. Yamane, T. Kawagoe, Distinct clinical features between acute and chronic progressive parenchymal neuro-Behçet disease: meta-analysis, *Sci. Rep.* 7 (2017) 10196.
- [3] A. Borhani-Haghighi, B. Kardeha, S. Banerjee, G. Yadollahikhalalec, A. Safarid, M.A. Sahraiane, L. Shapiro, Neuro-Behçet's disease: An update on diagnosis, differential diagnoses, and treatment, *Multiple Sclerosis Relat. Disord.* 39 (2020) 101906.
- [4] C. Beuker, A. Schmidt, D. Strunk, P.B. Sporns, H. Wiendl, S.G. Meuth, J. Minnerup, Primary angiitis of the central nervous system: diagnosis and treatment, *Ther. Adv. Neurol. Disord.* 9 (July (11)) (2018) 1756286418785071.
- [5] G. Hatemi, R. Christensen, D. Bang, B. Bodaghi, A.F. Celik, F. Fortune, et al., 2018 update of the EULAR recommendations for the management of Behçet's syndrome, *Ann. Rheum. Dis.* 77 (June (6)) (2018) 808–818.