



A case of cerebral infarction caused by painless acute aortic dissection in autosomal dominant polycystic kidney disease

Shintaro Yamaguchi¹ · Shu Wakino¹ · Hirobumi Tokuyama¹ · Hiroshi Itoh¹

Received: 10 November 2019 / Accepted: 14 January 2020 / Published online: 27 January 2020
© Japanese Society of Nephrology 2020

Abstract

Autosomal dominant polycystic kidney disease (ADPKD) is a genetic disorder, characterized by the progressive formation of renal cysts. Although ADPKD is strongly associated with cerebral and cardiovascular complications, cerebral ischemia caused by dissection of thoracic and carotid arteries has rarely been reported. We report the case of a 71-year-old Japanese woman who complained of hemiparesis. She required maintenance hemodialysis therapy with a background of ADPKD. Cerebral infarction was initially diagnosed by excluding intracranial hemorrhage and aneurysm rupture that are recognized as common complications of ADPKD and thereby anticoagulation therapy was initiated. However, the patient was suspected as having painless aortic dissection because a chest X-ray examination showed expanded upper mediastinum. Sequential vascular imagings revealed dissection of the aorta, originating from brachiocephalic trunk to the right common carotid artery with mediastinal hematoma. The patient died from progression of dissection. Herein, we described a case of the ADPKD patient that an acute aortic dissection without any pain induced the occlusion of supplying vessels to the brain, resulting in cerebral ischemic symptoms. A high level of clinical vigilance for an acute aortic dissection should be maintained in the ADPKD population with sudden onset of neurological symptoms even in the absence of pain. Furthermore, the initiation of anticoagulation treatment for cerebral ischemia which may aggravate the risk of further dissection requires careful consideration.

Keywords Autosomal dominant polycystic kidney disease · Painless aortic dissection · Cerebral ischemic symptoms

Introduction

Autosomal dominant polycystic kidney disease (ADPKD) is an inherited disorder that culminates in end-stage renal disease with a prevalence of 50% by the age of 50 [1]. Its disease development is contributed by a combination of gene mutations in polycystic kidney disease-1 (PKD1) and PKD2 that are involved in the differentiation of kidney epithelial cells [2, 3] and environmental factors [4–7].

In addition to renal cystic manifestations, extra-renal complications can include cysts of other systemic organs, intracranial aneurysms, aortic dissection and cardiac valvular diseases [8, 9]. As such, ADPKD patients are at increased risk for cerebral and cardiovascular diseases and thereby symptoms related to vascular disorders should be evaluated

carefully in this population. Especially, neurological symptoms are considered to be the result of intracranial aneurysm (ICA) rupture because its occurrence in ADPKD is reported to be five times higher than in general population [10]. On the other hand, although it has been shown that the risk of having aortic dissection is greater in ADPKD population [11], cervicocephalic and thoracic aortic dissections which could be accompanied by cerebral infarction have rarely been reported [2, 12]. Therefore, it could be difficult to even suspect ADPKD patients with cerebral ischemic symptoms of having aortic dissection especially without any pain.

Herein, we describe a case of an ADPKD patient who developed cerebral ischemic symptoms caused by painless acute aortic dissection. Physicians should keep in mind that the underlying disease for central nervous system (CNS) manifestations in ADPKD patients could be an acute aortic dissection even without any pain. Moreover, the initiation of treatment for cerebral ischemia including anticoagulation and antiplatelet therapy in ADPKD population should be considered after carefully excluding not only intracranial hemorrhagic diseases but also aortic dissection.

✉ Shu Wakino
shuwakino@z8.keio.jp

¹ Department of Internal Medicine, Keio University School of Medicine, 35 Shinanomachi, Shinjuku-ku, Tokyo 160-8582, Japan

Case presentation

In April 2009, a 71-year-old Japanese woman was admitted to our hospital, complaining of unilateral progressive paralysis of left arm and leg. The patient had developed end-stage renal disease requiring maintenance hemodialysis therapy for 8 years with a background of ADPKD. She took antihypertensive medicine (nifedipine CR at 40 mg/day) and her casual blood pressure including hemodialysis session was well controlled around 130/80 mmHg. Her past medical history included multiple liver cysts that needed surgical fenestration and aortic regurgitation which required valve replacement. After the aortic valve operation, she received warfarin anticoagulation therapy for only 6 months but thereafter she did not take any anti-coagulation and antiplatelet drugs. Her cardiac function evaluated by echocardiography was maintained (ejection fraction 83%). The patient had a family history of ADPKD and both her mother and daughters who did not have any cardiac diseases were also suffering from the kidney disease.

On admission, her height was 146.5 cm and body weight was 44.9 kg. The patient had a blood pressure of 124/82 mmHg with normal heart rate. Routine chest X-ray revealed mild cardiomegaly with a slight pulmonary congestion (Fig. 1a) presumably because she was supposed to undergo a regular dialysis in the morning of admission day. Neurological examination showed left moderate hemiparesis and consciousness disturbance with a disorientation to time and place. Concerned about the association of ICA rupture or primary hypertensive intracranial hemorrhage, cerebral computed tomography (CT) scan was performed and showed no hemorrhage. These examinations led us to suspect of cerebral infarction and anticoagulation therapy with heparin was then initiated.

The following morning, she developed intermittent back pain localized on her right scapula and bloody sputum. We discontinued anticoagulation therapy and performed her hemodialysis using nafamostat mesylate instead of heparin. During the session, her vital sign was stable. Although her consciousness was almost clear, she did not present with any pain. A chest X-ray examination after the dialysis showed expanded upper mediastinum (Fig. 1b). We then performed a chest CT scan, which revealed an intimal flap in brachiocephalic trunk with mediastinal hematoma (Fig. 2). In addition, a magnetic resonance imaging study with magnetic resonance angiography (MRA) showed dissection of the ascending aorta, originating from brachiocephalic trunk to the right common carotid artery, classified as acute type A aortic dissection (Fig. 3). The operability was carefully assessed by cardio-surgeons and an intense blood pressure control was recommended.

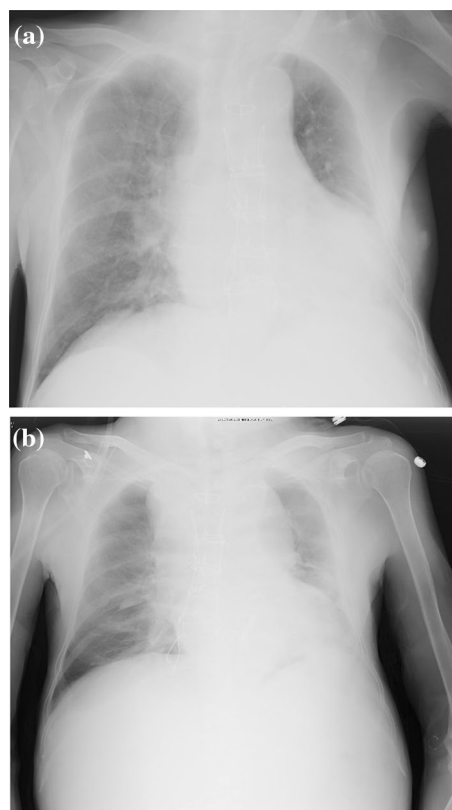


Fig. 1 Chest X-rays of the patient. Chest X-ray of the patient on admission day (a) and after the hemodialysis (b). a Mild cardiomegaly with a slight pulmonary congestion was observed on admission day. b Expanded upper mediastinum was demonstrated after the dialysis

Unfortunately, the patient died within a few hours. An autopsy was performed, revealing that dissection of the aorta, which originated from aortic arch to the right common carotid artery, was accompanied by mediastinal hematoma (7 × 8 × 12 cm) and right hemorrhagic pleural effusion (1000 ml).

Discussion

We described a case of ADPKD on maintenance dialysis, presenting with cerebral ischemic symptoms caused by a rare ADPKD-associated complication, acute painless thoracic aortic dissection.

Mutations in *PKD1* and *PKD2*, which encode polycystin-1 and polycystin-2, respectively, are known to be responsible for not only cysts formation in the kidney and liver but also vascular abnormalities [2]. Thus, ADPKD is associated with cardiovascular disorders and cerebral vascular complications are important causes of morbidity and mortality [13]. Rivera et al. showed that cerebral events are caused by intracranial aneurysm and hemorrhage [13].

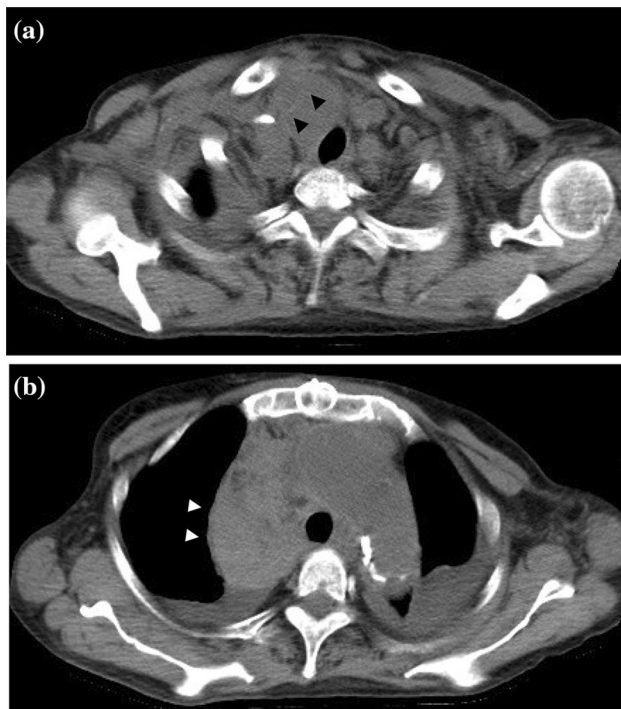


Fig. 2 Chest CT scans of the patient showed aortic dissection accompanied by mediastinal hematoma. Chest CT scans performed after the dialysis on the next day of admission revealed an intimal flap in brachiocephalic trunk (a) and mediastinal hematoma (b)

ICA occurs with a 5–10% incidence [14–16] and its rupture is the cause of death in approximately 4–7% in the ADPKD population [17]. Primary hypertensive intracranial hemorrhage is increased in ADPKD patients when the maintenance dialysis is performed [18]. Therefore, we assume that brain CT scans in the ADPKD population with acute neurological symptoms would reveal hemorrhage.

With cerebral CT scans showing no signs of hemorrhage, we would attribute sudden onset of CNS symptoms to cerebral infarction because previous reports have demonstrated that an ischemic stroke is also one of the major causes of acute neurological events affecting ADPKD patients [13, 19, 20]. Importantly, it has been suggested that aortic dissection is accompanied by cerebral infarction in about 6% of cases [21] and demonstrated that the risk of aortic dissection in ADPKD was higher than in general population [11]. Moreover, it has been reported that ADPKD is associated with thoracic aortic aneurysm [22]. However, patients of ADPKD rarely present with dissections of thoracic aorta and cervicocephalic arteries which could cause symptoms of cerebral infarction [2, 12]. These notions underscore the importance to clearly recognize ADPKD as one of the background diseases of acute aortic aneurysm and dissection, especially when presenting with cerebral ischemic symptoms [23, 24].

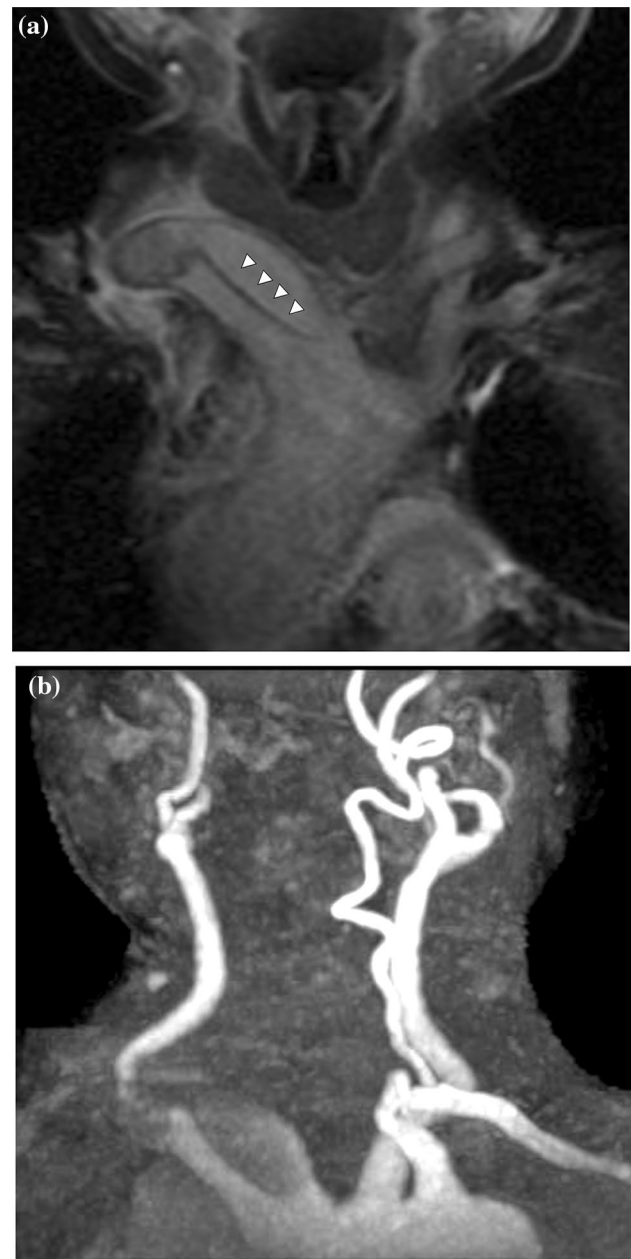


Fig. 3 MRA demonstrated ascending aorta dissection extended to right common carotid artery. MRA performed after the dialysis showed dissection of ascending aorta, originating from brachiocephalic trunk (a) to the right common carotid artery (b)

Aortic dissection typically presents with chest or back pain. However, there has been 5–15% of patients with painless aortic dissection [21, 25–27]. It has been speculated that a gradual dissection accompanied by less wall stretch may not result in pain. In addition to the sparing of the adventitial layer, the site of aortic innervation [28–30], damaged innervation to the aorta by previous aortic surgery may not induce pain [31]. A previous report demonstrated that approximately 70% of acute aortic painless

dissection patients had disturbance of consciousness and neurologic symptoms [32]. One possible explanation is that patients who suffer from acute aortic dissection with a disturbance of consciousness may not perceive pain. In this case, although the patient had consciousness disturbance with a disorientation to time and place on admission, she was able to verbally express her symptoms and also respond to pain. Therefore, it seems that former speculation for painless aortic dissection would explain our case.

There is another obstacle to provide appropriate treatment to the ADPKD patients who have painless aortic dissection with neurologic symptoms. In fact, we initiated anticoagulation therapy for cerebral ischemic symptoms, which might have led to the extension of aortic dissection and mediastinal hematoma. Prior to the initiation of anti-coagulation therapy to ADPKD patients, we should consider the risk for renal cyst and cerebral aneurysmal bleeding [33] as well as the possibility of dissection [31].

Our case emphasized the importance to (1) recognize ADPKD patients would have painless aortic dissection when presenting with cerebral ischemic symptoms and (2) provide appropriate treatment without delay. Therefore, in addition to the importance of routine screening for aortic disease [34], we suggest the necessity of imaging tests for thoracic and carotid arteries and careful consideration before initiating anticoagulation therapy in ADPKD population with cerebral ischemic symptoms even without any pain.

References

- Persu A, Duyme M, Pirson Y, Lens XM, Messiaen T, Breuning MH, et al. Comparison between siblings and twins supports a role for modifier genes in ADPKD. *Kidney Int.* 2004;66(6):2132–6. <https://doi.org/10.1111/j.1523-1755.2004.66003.x>.
- Perrone RD, Malek AM, Watnick T. Vascular complications in autosomal dominant polycystic kidney disease. *Nat Rev Nephrol.* 2015;11(10):589–98. <https://doi.org/10.1038/nrneph.2015.128>.
- Igarashi P, Somlo S. Genetics and pathogenesis of polycystic kidney disease. *J Am Soc Nephrol.* 2002;13(9):2384–98.
- Saadi-Kheddouci S, Berrebi D, Romagnolo B, Cluzeaud F, Peuchmaur M, Kahn A, et al. Early development of polycystic kidney disease in transgenic mice expressing an activated mutant of the beta-catenin gene. *Oncogene.* 2001;20(42):5972–81. <https://doi.org/10.1038/sj.onc.1204825>.
- Qian F, Germino FJ, Cai Y, Zhang X, Somlo S, Germino GG. PKD1 interacts with PKD2 through a probable coiled-coil domain. *Nat Genet.* 1997;16(2):179–83. <https://doi.org/10.1038/ng0697-179>.
- Tsiokas L, Kim E, Arnould T, Sukhatme VP, Walz G. Homo- and heterodimeric interactions between the gene products of PKD1 and PKD2. *Proc Natl Acad Sci USA.* 1997;94(13):6965–70.
- Peters DJ, Breuning MH. Autosomal dominant polycystic kidney disease: modification of disease progression. *Lancet* (London, England). 2001;358(9291):1439–44. [https://doi.org/10.1016/S0140-6736\(01\)06531-x](https://doi.org/10.1016/S0140-6736(01)06531-x).
- Eccer T, Schrier RW. Cardiovascular abnormalities in autosomal-dominant polycystic kidney disease. *Nat Rev Nephrol.* 2009;5(4):221–8. <https://doi.org/10.1038/nrneph.2009.13>.
- Leier CV, Baker PB, Kilman JW, Wooley CF. Cardiovascular abnormalities associated with adult polycystic kidney disease. *Ann Intern Med.* 1984;100(5):683–8.
- Grunfeld JP. Hereditary renal diseases. *Saudi J Kidney Dis Transpl.* 1997;8(3):227–34.
- Sung PH, Yang YH, Chiang HJ, Chiang JY, Chen CJ, Liu CT, et al. Risk of aortic aneurysm and dissection in patients with autosomal-dominant polycystic kidney disease: a nationwide population-based cohort study. *Oncotarget.* 2017;8(34):57594–604. <https://doi.org/10.18632/oncotarget.16338>.
- Stanley I, Sharma VK, Tsivgoulis G, Lao AY, Alexandrov AV. Painless aortic dissection with unusual extension into intracranial internal carotid arteries. *Cerebrovasc Dis* (Basel, Switzerland). 2007;24(2–3):314–5. <https://doi.org/10.1159/000106517>.
- Rivera M, Gonzalo A, Gobernado JM, Orte L, Quereda C, Ortuno J. Stroke in adult polycystic kidney disease. *Postgrad Med J.* 1992;68(803):735–8.
- Graf S, Schischma A, Eberhardt KE, Istel R, Stiasny B, Schulze BD. Intracranial aneurysms and dolichoectasia in autosomal dominant polycystic kidney disease. *Nephrol Dialysis Transpl.* 2002;17(5):819–23.
- Chapman AB, Rubinstein D, Hughes R, Stears JC, Earnest MP, Johnson AM, et al. Intracranial aneurysms in autosomal dominant polycystic kidney disease. *New England J Med.* 1992;327(13):916–20. <https://doi.org/10.1056/nejm199209243271303>.
- Huston J 3rd, Torres VE, Sullivan PP, Offord KP, Wiebers DO. Value of magnetic resonance angiography for the detection of intracranial aneurysms in autosomal dominant polycystic kidney disease. *J Am Soc Nephrol.* 1993;3(12):1871–7.
- Fick GM, Johnson AM, Hammond WS, Gabow PA. Causes of death in autosomal dominant polycystic kidney disease. *J Am Soc Nephrol.* 1995;5(12):2048–56.
- Yoo DJ, Agodoa L, Yuan CM, Abbott KC, Nee R. Risk of intracranial hemorrhage associated with autosomal dominant polycystic kidney disease in patients with end stage renal disease. *BMC Nephrol.* 2014;15:39. <https://doi.org/10.1186/1471-2369-15-39>.
- Pirson Y, Chauveau D. ADPKD-associated intracranial aneurysm: new insights and unanswered questions. *Contrib Nephrol.* 1995;115:53–8.
- Pirson Y, Chauveau D, van Gijn J. Subarachnoid haemorrhage in ADPKD patients: how to recognize and how to manage? *Nephrol Dialysis Transpl.* 1996;11(7):1236–8.
- Hagan PG, Nienaber CA, Isselbacher EM, Bruckman D, Karavite DJ, Russman PL, et al. The International Registry of Acute Aortic Dissection (IRAD): new insights into an old disease. *JAMA.* 2000;283(7):897–903. <https://doi.org/10.1001/jama.283.7.897>.
- Elefteriades JA, Sang A, Kuzmik G, Hornick M. Guilt by association: paradigm for detecting a silent killer (thoracic aortic aneurysm). *Open Heart.* 2015;2(1):e000169. <https://doi.org/10.1136/openhrt-2014-000169>.
- Aoyagi S, Oda T, Kanamoto R, Nakamura E, Yasunaga H. Aortic dissection associated with autosomal dominant polycystic kidney disease. *Heart Surgery Forum.* 2019;22(1):E032–E34. <https://doi.org/10.1532/hcf.2027>.
- Haruta S, Gunji K, Kawamura T, Hiroshima K. Generalized vascular dissection on pathological examination in a patient with polycystic kidney disease and acute aortic dissection. *J Natl Med Assoc.* 2019;111(5):563–8. <https://doi.org/10.1016/j.jnma.2019.04.008>.
- Park SW, Hutchison S, Mehta RH, Isselbacher EM, Cooper JV, Fang J, et al. Association of painless acute aortic dissection with

- increased mortality. *Mayo Clin Proc.* 2004;79(10):1252–7. <https://doi.org/10.4065/79.10.1252>.
26. Spittell PC, Spittell JA Jr, Joyce JW, Tajik AJ, Edwards WD, Schaff HV, et al. Clinical features and differential diagnosis of aortic dissection: experience with 236 cases (1980 through 1990). *Mayo Clin Proc.* 1993;68(7):642–51. [https://doi.org/10.1016/s0025-6196\(12\)60599-0](https://doi.org/10.1016/s0025-6196(12)60599-0).
 27. Gaul C, Dietrich W, Friedrich I, Sirch J, Erbguth FJ. Neurological symptoms in type A aortic dissections. *Stroke.* 2007;38(2):292–7. <https://doi.org/10.1161/01.STR.0000254594.33408.b1>.
 28. Cohen S, Littmann D. Painless dissecting aneurysm of the aorta. *New England J Med.* 1964;271:143–5. <https://doi.org/10.1056/nejm196407162710308>.
 29. Wooley CF, Sparks EH, Boudoulas H. Aortic pain. *Prog Cardiovasc Dis.* 1998;40(6):563–89. [https://doi.org/10.1016/s0033-0620\(98\)80004-2](https://doi.org/10.1016/s0033-0620(98)80004-2).
 30. Rahmatullah SI, Khan IA, Nair VM, Caccavo ND, Vasavada BC, Sacchi TJ. Painless limited dissection of the ascending aorta presenting with aortic valve regurgitation. *Am J Emerg Med.* 1999;17(7):700–1. [https://doi.org/10.1016/s0735-6757\(99\)90165-1](https://doi.org/10.1016/s0735-6757(99)90165-1).
 31. Marroush TS, Boshara AR, Parvataneni KC, Takla R, Mesiha NA. Painless aortic dissection. *Am J Med Sci.* 2017;354(5):513–20. <https://doi.org/10.1016/j.amjms.2016.11.005>.
 32. Imamura H, Sekiguchi Y, Iwashita T, Dohgomori H, Mochizuki K, Aizawa K, et al. Painless acute aortic dissection—diagnostic, prognostic and clinical implications. *Circ J.* 2011;75(1):59–66. <https://doi.org/10.1253/circj.10-0183>.
 33. Moon J, Lee SH, Yang WI, Ko YG, Han WK, Jang Y. Fatal renal bleeding in a patient treated with aggressive antithrombotic therapy after recurrent coronary stent thrombosis. *Korean Circ J.* 2010;40(7):348–51. <https://doi.org/10.4070/kcj.2010.40.7.348>.
 34. Faggion Vinholo T, Zafar MA, Ziganshin BA, Elefteriades JA. Nonsyndromic thoracic aortic aneurysms and dissections—is screening possible? *Semin Thorac Cardiovasc Surg.* 2019;31(4):628–34. <https://doi.org/10.1053/j.semtcvs.2019.05.035>.

Publisher's Note Springer Nature remains neutral with regard to jurisdictional claims in published maps and institutional affiliations.