

TRIGEMINAL TROPHIC SYNDROME*

RICHARD ARASI, MD

MARILYNNE MC KAY, MD

WILLIAM J. GRIST, MD

Atlanta, GA

ABSTRACT

Trigeminal trophic syndrome is an unusual condition also known as trigeminal neurotrophic ulceration or trigeminal neuropathy with nasal ulceration. The diagnosis is suggested when ulceration of the face, especially of the ala nasi, occurs in a dermatome of the trigeminal nerve that has been rendered anesthetic by a surgical or other process involving the trigeminal nerve or its central sensory connections. A history of paresthesias and self-induced trauma to the area further support the diagnosis.

Neurological deficits causing trigeminal trophic syndrome may result from surgical trigeminal ablation, vascular disorders and infarction of the brainstem, acoustic neuroma, postencephalitic parkinsonism, and syringobulbia. The following etiologies of nasal ulceration should be excluded: postsurgical herpetic reactivation and ulceration, syphilis, leishmaniasis, leprous trigeminal neuritis, yaws, blastomycosis, paracoccidioidomycosis, lethal midline granuloma, pyoderma gangrenosum, Wegener's granulomatosis, and basal cell carcinoma.

In the case reported here, the diagnosis of TTS was made primarily as a result of previous experience with the syndrome, underscoring the importance of physician recognition of this unusual disorder.

Trigeminal trophic syndrome (TTS)¹⁻⁴ is a relatively uncommon condition also known in medical literature as trigeminal neurotrophic ulceration,⁵ trigeminal neuropathy with nasal ulceration,^{6,7} trophic ulceration of the ala nasi,⁸ and ulceration en arc.⁹ The diagnosis is suggested when ulceration of the face, especially of the ala nasi, occurs in a dermatome of the trigeminal nerve that has been rendered anesthetic by a surgical or other process involving the trigeminal nerve or its central sensory connections. A history of paresthesias and self-induced trauma to the area further support the diagnosis. Important etiologies of nasal ulceration which should be excluded are: postsurgical herpetic reactivation and ulceration, syphilis, leishmaniasis, leprous trigeminal neuritis, yaws, blastomycosis, paracoccidioidomycosis, lethal midline granuloma, pyoderma gangrenosum, Wegener's granulomatosis, and basal cell carcinoma, which it may closely resemble.^{3,5,10}

Trigeminal trophic syndrome has been most frequently described as a complication of surgical trigeminal ablation for treatment of trigeminal neuralgia. TTS was first described as a clinical entity in 1933 by Loveman¹¹ and independently by McKenzie¹² that same year. Since that time, numerous authors have described similar cases in which chronic facial ulceration and erosion of the ala nasi developed following impairment of trigeminal sensory function. In a recent review of 63 cases of TTS, Weintraub, *et al.* categorized the distribution of patients by etiological factor and found that 75% were

associated with surgical trigeminal ablation by rhizotomy or alcohol injection into the gasserian ganglion.³ The less common etiological factors were vertebral basilar insufficiency, acoustic neuroma, postencephalitic parkinsonism, and syringobulbia. In some cases, the etiology was unknown.³

In the case reported here, the diagnosis of TTS was made primarily as a result of previous experience with the syndrome, underscoring the importance of recognition of this unusual disorder.

CASE REPORT

A 62-year-old man with severe chronic obstructive pulmonary disease developed a deep unilateral nasal ulceration with a crescentic defect in the nasal ala and erythema and edema of the adjacent cheek. Six months earlier, a neurologist had evaluated the patient for a 2-month history of developing numbness of the entire left leg and paresthesias of the right side of his face. Neurologic examination revealed a definite but mild right Horner's syndrome and deviation of the palate to the left. Pain and temperature sensations were impaired over the right side of the face throughout the distribution of the trigeminal nerve. The right corneal reflex was absent. The same sensory modalities were impaired over the entire left side of the body including the left face, although the sensory loss on the left face was much less marked than the right. The left corneal reflex was present. An MRI showed an abnormality thought to be most consistent with an infarct in the right cerebellum, which seemed to extend into the inferior cerebellar peduncle and the medulla itself. There was no distortion of the fourth ventricle or other posterior fossa structures. The conclusion was that this infarction had occurred several months previously, coinciding with the onset of his symptomatology, and was the etiology of the neurological findings.

The patient and his wife admitted that he had been picking at his nose a great deal in the months following the stroke, but that the erosion of the right nostril had developed only during the past few weeks. On advice from the patient's internist, he sequentially consulted an infectious disease specialist, an otolaryngologist, and a dermatologist. An incisional biopsy taken from the edge of the ulcer on the right nostril was read as non-specific active granulation tissue with no evidence of malignancy or deep fungal infection. Trigeminal trophic syndrome was diag-

*From the Departments of Dermatology (R.A., M.M.) and Surgery, Division of Otolaryngology (W.J.G.), Emory University School of Medicine, Atlanta, GA.

Editor's Note: This Manuscript was accepted for publication June 18, 1988.

Send Reprint Requests to William J. Grist, MD, Section of Otolaryngology, The Emory Clinic, 1365 Clifton Rd. NE, Atlanta, GA 30322.

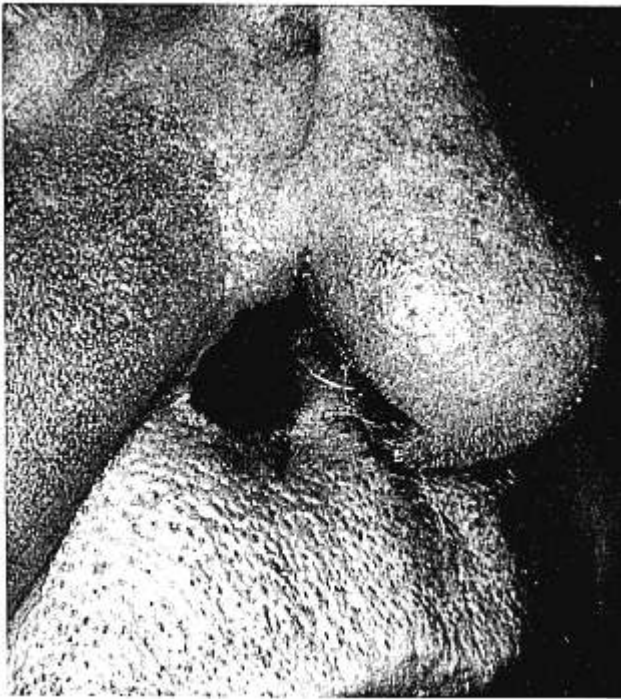


Fig. 1. The characteristic nasal ulceration seen in trigeminal trophic syndrome. The patient has a crescentic defect with loss of the ala nasi as a result of self-induced trauma. Erythema and induration of the cheek are the result of secondary infection.

nosed, secondary infection was treated with a 3-week course of an oral antibiotic, and the patient was instructed to avoid picking at the affected area. He was followed in the dermatology clinic intermittently for the next 1½ years.

At his last visit, the patient was noted to have retained the crescentic defect at the site of the right ala nasi, which was unchanged in size or shape. The defect, however, showed no evidence of active ulceration, inflammation, or infection, and in that regard appeared improved. The sensation to his face had returned. The patient reported that he had discontinued his habit of picking when he was instructed on the consequences, even using a bandage on his finger at one point to reduce nasal trauma. He firmly concurs that the entire problem resulted from a habit of aggressive and frequent picking, which began with the loss of sensation to his right face after his stroke.

DISCUSSION

This case is an example of an uncommon but characteristic condition in which nasal ulceration occurs subsequent to sensory impairment of the trigeminal nerve. Our patient would appear to fall into that small category of patients who develop this syndrome as a result of a stroke-induced trigeminal sensory deficit. Brainstem infarction and vascular insufficiency associated with TTS has been well described.^{5,8,13} As in our patient, a brainstem infarction may interrupt the central sensory connections of the trigeminal nerve, leaving sensory deficits in the trigeminal distribution.

The central sensory connections of the trigeminal nerve are complex, and processes involving any of the following areas may create a sensory deficit of varying degree and modality: sensory cortex, thal-

mus, trigeminothalamic tracts (midbrain, pons), main sensory nucleus (pons), entering trigeminal root fibers (pons), spinal tract, and nucleus (medulla). Irrespective of the specific etiology (brainstem infarction, lateral medullary syndrome, vertebrobasilar insufficiency, syndrome of the posterior inferior cerebellar artery), vascular disorders of the brainstem may interrupt these central connections, resulting in sensory impairment. The clinical and MRI findings in this case indicated involvement of the medulla by infarction. Lesions in the lateral medulla that damage the spinal tract and nucleus of the trigeminal (pain and temperature modalities of the face) are likely to include the lateral spinothalamic tract (pain and temperature modalities of the contralateral body) due to their close proximity. This creates the clinical picture seen in our patient of alternating and dissociated anesthesia, loss of pain and temperature sensation of the face ipsilaterally and the body contralaterally, with preservation of light touch. The preservation of light touch reflects the integrity of the main sensory nucleus of the trigeminal, which lies in the pons, cephalad to the area of infarction. Thus this central disruption has rendered the right trigeminal dermatome analgesic and thermo-anesthetic. The sensory impairment renders the area susceptible to self-induced traumatization, which is generally accepted to be the major factor in the development of this syndrome.

In a review of 63 patients with TTS, Weintraub, *et al.* found a mean age at presentation of 57 years. This study also found a greater incidence among female patients (2.2:1), and found that in all but one patient the ulcers occurred on the face ipsilateral to the trigeminal sensory impairment.³ It should be noted that 13% of these cases involved locations other than the nose, including the scalp, forehead, ear, palate, and jaw.³ The incidence of TTS is not known, but has been reported to occur in up to 18% of patients following surgical trigeminal ablation.¹

The gross and histological features are those of chronic nonspecific ulceration with crusting, erythema, tendency to bleed easily, and granulation tissue predominating. Occasionally there are changes of secondary infection. Clinically, the lesion may closely resemble basal cell epithelioma, thus histological examination may be necessary to differentiate the two entities.

Our patient illustrates the characteristic nasal ulceration (Fig. 1). Often there is a crescentic defect with loss of the ala nasi corresponding to the area of the nose lacking cartilage; thus, the description "ulceration en arc."⁹ The appearance of the defect has been described as being so uniform and characteristic that with a history of trigeminal surgery it can be readily distinguished from ulcerations of other neoplastic or inflammatory processes.¹⁴ The ulceration may also appear triangular or Y-shaped,⁴ and in more severe cases the ala nasi is completely de-

stroyed, scarring the adjacent cheek and upper lip and resulting in a drawing up of the upper lip into a characteristic sneer.^{2,3,15} The degree of deformity may be quite extensive. In a case of bilateral trigeminal sensory deficits after gasserian neurotomy, extensive nasal degeneration, including flattening of the nose, unroofing of the nasal chamber, absence of the nasal septum, turbinal distortion, and a midline cleft extending through the tip of the nose was described.¹⁰

The latent period between the initial trigeminal insult and the development of ulceration is variable. Reports range from 2 weeks to 10 years after ganglionic injection with alcohol¹⁵; 18 days to 18 years after neurological insult³; and a few months up to 23 years following ablation.¹⁴ In Weintraub's review of 63 cases, the median interval following initial neurological insult was 1 year.³

It is generally accepted that neurotrophic ulceration is the result of traumatic insult to the affected area, rather than a true trophic phenomenon, as the name trigeminal trophic syndrome might imply. Uncomfortable sensations around the ala nasi, provoking self-induced traumatic picking behavior, may include a variety of paresthesias (burning, pricking, formication) or sensations of nasal stuffiness, discharge, or dryness.^{3,14,15} In most cases the self-induced trauma is an attempt by the patient to relieve the annoying paresthesias when they are present.^{1,13} It is felt that in some instances, especially the elderly, the picking may become a compulsion,⁵ which results in chronic unremitting ulceration.

The role of trauma may be best understood in relation to the effect of the neurological insult itself. In trigeminal anesthesia the normal protective sensory input is abolished, and the vasomotor function to the skin and subcutaneous tissues may be abnormal.¹⁴ The absence of protective sensory feedback allows picking to occur without pain. Inflammation, hemorrhage, and crust formation encourage further picking, and a destructive cycle ensues. It has been postulated that disruption of normal wound healing furthers the development of these ulcerations, which occur in a normally rapidly healing area of the body.^{4,14} It has been suggested that ablation of the gasserian ganglion disrupts the normal autonomic vasomotor regulation to the affected region by interrupting the sympathetic fibers that arise from the internal carotid plexus and connect with the trigeminal nerve.⁴ Vasodilatation causes constant cooling of the skin and slows venous return, resulting in an unfavorable healing environment.⁴ Abyholm and Eskeland detailed the cycle of recurrent trauma, inflammation, hemorrhage, and infection that occurs in an area that may not heal at a normal rate. This cycle leads eventually to chronic ulceration, necrosis, atrophy of the soft tissues, scarring, and deformity.¹⁴

Therapy for TTS should be directed at preventing trauma and controlling any secondary infection that may accompany the lesion. Controlling self-induced trauma is a key step in managing this condition but may be difficult to achieve, especially in those cases where persistent paresthesias are the stimulus for the picking behavior or in demented or mentally impaired patients. The use of a protective device or prosthesis to protect the ulcerated area may be helpful when combined with efforts to convince the patient that the lesion will not heal if trauma persists. At one point our patient, with encouragement from his family, bandaged his finger to help reduce damage to his nose. Although some reports describe rapid healing of the ulcer after elimination of trauma, our patient's nasal defect has persisted, despite assurances that his picking behavior has stopped.

A variety of treatments have been reported to promote healing, including cervical sympathectomy and ionizing irradiation⁸; however, the efficacy of these modalities has not been established. The use of topical or systemic antibiotics to control secondary infection, if present, with "saline sniffs" and petrolatum to combat mucosal dryness and crusting are helpful conservative measures.¹⁶ Westerhof and Bos reported successful treatment of a patient using transcutaneous electrical nerve stimulation (TENS) to promote ulcer healing by enhancement of local blood supply⁴; however, the usefulness of TENS as a mode of therapy has not been established at this time.

Surgical therapy may have an important role in repairing TTS defects in cases where prophylaxis and conservative measures have failed to result in satisfactory healing. Obviously, it is essential that TTS be recognized, so that attempts at surgical reconstruction will not be doomed to failure at the patient's own hand. Attempts at surgical repair seem to be worthwhile only if tissue with functional innervation and its own blood supply is used in the repair. Previous reports describe excision and closure with ipsilateral skin, but this provided only temporary improvement.¹⁴ Repair of defects using flaps based on the unaffected side of the midline have shown more promising results in two cases reported by Abyholm and Eskeland. Less shrinkage, reulceration, and atrophy were observed after 23 and 11 months.¹⁴ In a more recent case, an innervated contralateral forehead flap was used to reconstruct a defect of the right ala nasi in a case of TTS without recurrence of the ulceration over a 3-year period.¹⁶

In summary, trigeminal trophic syndrome (TTS) is an unusual, but highly recognizable, complication of neurological compromise to a trigeminal dermatome. The classical presentation is that of a crescentic ulceration of the ala nasi, which may extend to involve the adjacent cheek and upper lip; however, in a small percentage of cases the ulceration may oc-

cur in different areas within the distribution of the trigeminal nerve including the scalp, forehead, and ear. Because of its unusual presentation, TTS may be encountered by a variety of specialists. As a result, reports have appeared most often in the dermatological, neurological, and neurosurgical literature, although the otolaryngologist would seem equally likely to see this problem. Awareness of this syndrome increases the likelihood of proper diagnosis and management, especially if surgical intervention is considered.

BIBLIOGRAPHY

1. Finlay, A. Y.: Trigeminal Trophic Syndrome. *Arch. Dermatol.*, 115:1118, 1979.
2. Harper, N.: Trigeminal Trophic Syndrome. *Postgrad. Med. J.*, 61:449-451, 1985.
3. Weintraub, E., Soltani, K., Hekmatpanah, J., et al.: Trigeminal Trophic Syndrome. *J. Am. Acad. Dermatol.*, 6:52-57, 1982.
4. Westerhof, W. and Bos, J. D.: Trigeminal Trophic Syndrome: A Successful Treatment with Transcutaneous Electrical Stimulation. *Br. J. Dermatol.*, 108:601-604, 1983.
5. Walton, S. and Keczkas, K.: Trigeminal Neurotrophic Ulceration—A Report of Four Patients. *Clin. Exp. Dermatol.*, 10:485-490, 1985.
6. Spillane, J. D. and Urich, H.: Trigeminal Neuropathy with Nasal Ulceration: Report of Two Cases and One Necropsy. *J. Neurol. Neurosurg. Psychiatry*, 39:105-113, 1976.
7. Freeman, A. G.: Trigeminal Neuropathy with Nasal Ulceration. *J. Neurol. Neurosurg. Psychiatry*, 39:821-822, 1976.
8. Bauer, F.: Trophic Ulceration of the Ala Nasi Following Trigeminal Denervation. *J. Laryngol. Otol.*, 80:422-425, 1966.
9. Jaeger, H.: New Type of Neurotrophic Ulcer of the Ala Nasi Following Retrogasserian Neurotomy. *Dermatologica*, 100:201, 1950.
10. Willson, N. J., Sharer, L. R., Jung, H. J., et al.: Bilateral Trigeminal Nerve Sensory Deficits and Nasal Deformity. *Arch. Otolaryngol.*, 104:474-476, 1978.
11. Loveman, A.: An Unusual Dermatitis Following Section of the Fifth Cranial Nerve. *Arch. Dermatol. Syph.*, 28:369-375, 1933.
12. McKenzie, K. G.: Observations on the Results of the Operative Treatment of Trigeminal Neuralgia. *Can. Med. Assoc. J.*, 29:492-496, 1933.
13. Freeman, A. G.: Neurotrophic Ulceration of the Face with Erosion of the Ala Nasi in Vascular Disorders of the Brain Stem. *Br. J. Dermatol.*, 78:322-331, 1966.
14. Abyholm, F. E. and Eskeland, G.: Defect of the Ala Nasi Following Trigeminal Denervation. Case Report. *Scand. J. Plast. Reconstr. Surg.*, 11:87-90, 1977.
15. Howell, J. B.: Neurotrophic Changes in the Trigeminal Territory. *Arch. Dermatol.*, 86:442-449, 1962.
16. McLean, N. R. and Watson, A. C. H.: Reconstruction of a Defect of the Ala Nasi Following Trigeminal Anaesthesia with An Innervated Forehead Flap. *Br. J. Plast. Surg.*, 35:201-203, 1982.

AMERICAN DIOPTER AND DECIBEL SOCIETY

The American Diopter and Decibel Society will be holding a combined seminar for Ophthalmology and Otolaryngology at the Acapulco Princess Hotel in Acapulco, Mexico. The meeting will take place from January 21-28, 1989. Attendees will be eligible for 20 Category I CME credits given.

For further information, contact: Jeannine L. Nee, Meeting Coordinator, 3518 Fifth Avenue, Pittsburgh, Pennsylvania 15213, phone (412) 682-6300.