

Thrombosed Arteriovenous Malformations: A Type of Occult Vascular Malformation

Magnetic Resonance Imaging and Histopathological Correlations

John D. Ebeling, M.D., Bruce I. Tranmer, M.D., Kathleen A. Davis, M.D., Glenn W. Kindt, M.D., and B. K. DeMasters, M.D.

Department of Neurosurgery (JDE), University of Missouri, Columbia, Missouri, and Departments of Neurosurgery (BIT, GWK), Radiology (KAD), and Pathology (BKD), University of Colorado, Denver, Colorado

Thrombosed arteriovenous malformations (AVMs) are the predominant type of occult vascular malformation and do not seem to differ significantly in clinical or radiographic presentation from other types of occult vascular malformations. Thrombosed AVMs and occult vascular malformations occasionally present with symptoms secondary to subacute or occult hemorrhage that requires operation. The histopathology of thrombosed AVMs and occult vascular malformations does not seem to have prognostic significance. Five patients with histologically verified thrombosed AVMs are reported. Two patients had previous incomplete resection of histologically proven thrombosed AVMs and presented with recurrence and bleeding. Two patients presented with seizures and headaches, and one patient presented with hemiparesis and headache. All histology specimens had evidence of hemorrhage. The pathological findings of these lesions seem variable; two specimens contained a mixture of cavernous angioma and AVM. Two previously resected lesions had been defined histologically as thrombosed AVMs. Successful excision of the lesions was accomplished in four patients, and one patient had stereotactic biopsy. The magnetic resonance imaging characteristics of lesions seem to add a degree of specificity over computed tomography and angiography. We have found that the literature poorly describes the natural history and histology of these lesions. Conservative management for seizures and headaches due to thrombosed AVMs may not be warranted because of a propensity for hemorrhage and recurrence. (*Neurosurgery* 23:605-610,1988)

Key words: Arteriovenous malformation, Intracerebral hemorrhage, Magnetic resonance imaging

Thrombosed arteriovenous malformations (AVMs) are often referred to as cryptic or occult vascular malformations. Crawford and Russell in 1956 introduced the term "cryptic" to describe cerebrovascular malformations that were silent clinically before resulting in spontaneous hemorrhage (4). Because of the small size of these malformations, angiographic investigation was often negative for shunting or blush, leading to the term "angiographically occult vascular malformations."

The spectrum of occult or cryptic vascular malformations includes capillary telangiectasias, venous malformations, cavernous angiomas, and AVMs (14). Capillary telangiectasias are formed of plentiful small vessels dispersed in normal cerebral tissue. Venous angiomas are little more than varices with intervening tissue, often stained by hemosiderin. The intervening tissue of cavernous angiomas, if present at all, is gliotic and is present between sinusoidal channels. AVMs are composed of vessels varying in caliber and mural thickness. Internal elastic lamina is present in arterial components of the malformation. Intervening tissue is gliotic and often hemosiderin-stained. Mural calcification of vessels can occur, and calcification may speckle gliotic tissue (1, 6, 12, 18).

The majority of these cryptic vascular malformations are AVMs (3, 12, 16). Usually, cryptic AVMs are less than 3 cm in size. They are not angiographically verifiable because of small size, partial or complete thrombosis, or obliteration by hemorrhage. Thrombosis is thought to occur spontaneously from several factors, including hemorrhage causing compression of vessel walls, intravascular turbulence, and arteriosclerosis (5, 17).

Throughout the literature, the terms thrombosed AVM, cryptic AVM, and occult cerebrovascular malformation have been used interchangeably, often without precise histological

definition. The radiographic findings of occult cerebrovascular malformations have been discussed, but the prognostic implications of each histological grade are unclear (2, 7-14, 17). Can an angiographically occult AVM safely be presumed to be thrombosed and not likely to hemorrhage? Can an occult AVM presenting with hemorrhage be presumed obliterated or thrombosed and not likely to bleed again? In the face of hemorrhage and the usual fragmentary pathological specimen, the histological findings may not accurately reflect the type of vascular lesion, the state of total vs. partial thrombosis, and the prognosis of the lesion. The term "thrombosed AVM" is artificial and may impart a false sense of security to conservative therapy.

In this report, we present five patients with histologically verified thrombosed AVMs and discuss their magnetic resonance imaging (MRI) characteristics. These patients were operated on at the University of Colorado from 1984 through 1987. Computed tomographic (CT) and MRI scans were reviewed by members of the neuroradiology and neurosurgery staff. The original pathology reports were obtained and the microscopic specimens were also reviewed by neurosurgery and neuropathology staff members.

Follow-up was obtained by review of clinic charts. These case reports illustrate the propensity for thrombosed AVMs to bleed or rebleed, the characteristic MRI findings, and the uncertainty of histopathological analysis.

CASE REPORTS

Case 1

A 29-year-old woman presented with a 2-year history of left-sided jacksonian seizures. The neurological examination

was normal. The CT scan showed a 25-mm left temporal lobe lesion with delayed enhancement and calcification. The MRI scan showed mixed signal intensity on the T1-weighted images with isointensity centrally, consistent with tissue matrix, and hyperintensity peripherally, consistent with methemoglobin due to subacute blood leakage (Fig. 1A). The T2-weighted images demonstrate eccentric hyperintensity consistent with tissue matrix and progressive hypointensity elsewhere consistent with hemosiderin in an area of more chronic clot (Fig. 1B and C). The angiogram was normal. The preoperative diagnosis was thrombosed AVM.

A left temporal craniotomy showed hemosiderin-stained brain and thrombosed AVM, which was completely excised. Pathological examination at the time of operation confirmed thrombosed AVM. Review of the specimen was consistent with vascular malformation of an uncertain type. The patient is seizure-free on carbamazepine therapy with 1 year of follow-up.

Case 2

A 22-year-old man was referred with the new onset of generalized seizures and 1 year of frontal headaches. The neurological examination was normal. The CT scan showed a 25-mm-diameter right frontal lesion with punctate calcification and delayed enhancement (Fig. 2). No MRI was performed. The angiogram showed no shunt or blush, but a few late draining veins in the area of the lesion. The preoperative diagnosis was cerebrovascular malformation.

A right frontotemporal craniotomy was performed with subtotal excision of the lesion. The surrounding tissue was stained with hemosiderin, and calcified hematoma was removed. Pathological examination showed gliosis and calcified vessels consistent with thrombosed AVM. Review of the specimen was consistent with vascular malformation of an uncertain type. The patient is seizure-free after 2 years of follow-up.

Case 3

A 17-year-old man had suffered a seizure disorder since age 7 years. In 1980, a right temporal lobe thrombosed AVM was partially excised. He did well until 1986, when he began having increasing headaches with nausea. The neurological examination was without lateralizing signs. A noncontrast CT scan showed a right frontal lobe calcification surrounded by a 4-cm-diameter hematoma (Fig. 3A). The angiogram showed nonspecific changes consistent with an avascular mass; no

AVM was seen. The MRI scan showed the majority of the lesion to be subacute hemorrhage with free methemoglobin hyperintense on T1- and T2-weighted images. Posteriorly, there was a mottled hypointense region consistent with tissue matrix and calcification (Fig. 3, B and C), subacute hematoma centrally, and edema peripherally. The preoperative diagnosis was a subacute hemorrhage from a partially thrombosed AVM.

The operative findings were a right frontal lobe subacute hematoma and partially thrombosed AVM, which was totally excised. Pathological examination showed gliosis, hemosiderin deposition, and hyalinized arteries with numerous capillary size vascular channels. Most channels were thrombosed. The diagnosis was partially thrombosed AVM. Review of the specimen was most consistent with cavernous angioma altered by multiple thromboses. At the 7-month follow-up examination, there were no seizures or headaches.

Case 4

A 10-year-old girl had undergone the partial excision of a right parietal lobe thrombosed AVM in 1985; the AVM had presented with episodic left arm paresis and paresthesia. Her symptoms had abated postoperatively, but recurred in March 1986. The neurological examination on admission was normal. The CT scan showed an enhancing right parietal lesion with calcification and hemorrhage; MRI showed a 23-mm lesion in the right parietal lobe with mixed iso- and hyperintense regions consistent with tissue matrix and subacute hemorrhage on T1-weighted images (Fig. 4A). T2-weighted images showed central hyperintensity with peripheral signal dropout consistent with peripheral hemosiderin. The angiogram was without shunting, blush, or abnormal vessels.

The lesion was excised totally through a right parietal craniotomy. The brain was stained with hemosiderin, and the lesion appeared to be a partially thrombosed AVM. Pathological examinations showed gliosis, hemosiderin, and calcification with findings of a mixed AVM-cavernous malformation. Review of the specimen was most consistent with cavernous angioma. The postoperative MRI scan showed total removal of the lesion, and the patient is seizure-free 2 months postoperatively.

Case 5

A 28-year-old woman presented with a 1-year history of increasing headaches and 6 weeks of slight left arm paresis and paresthesia. The neurological examination showed a

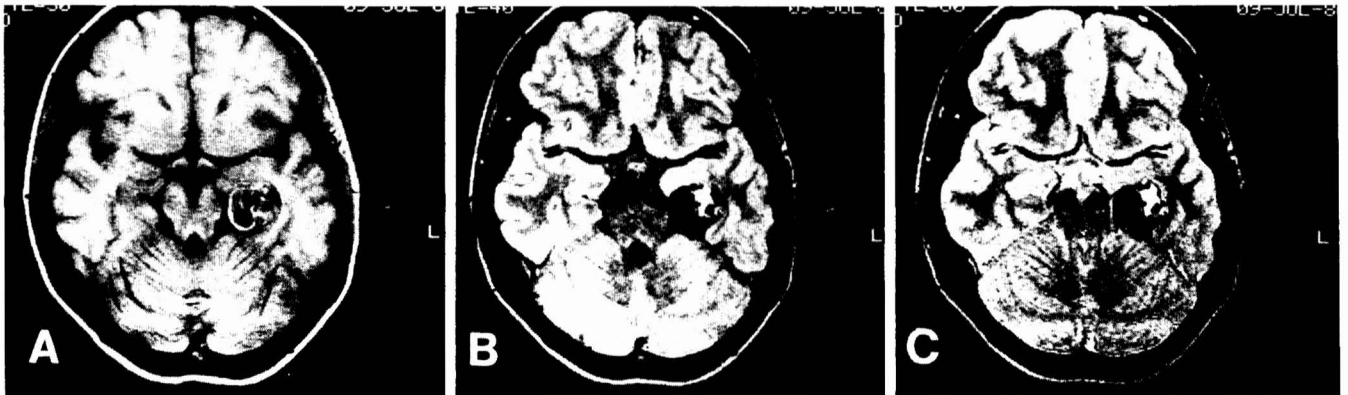

FIG. 1. Case 1. A: T1-weighted image (TR 500 ms/TE 30 ms) showing central mixed signal intensity consistent with tissue matrix and chronic clot and rim of hyperintensity consistent with subacute blood (methemoglobin). B and C: T2-weighted images (TR 2000/TE 40,80) demonstrating progressive hypointensity in chronic clot (hemosiderin) and hyperintensity in tissue matrix.

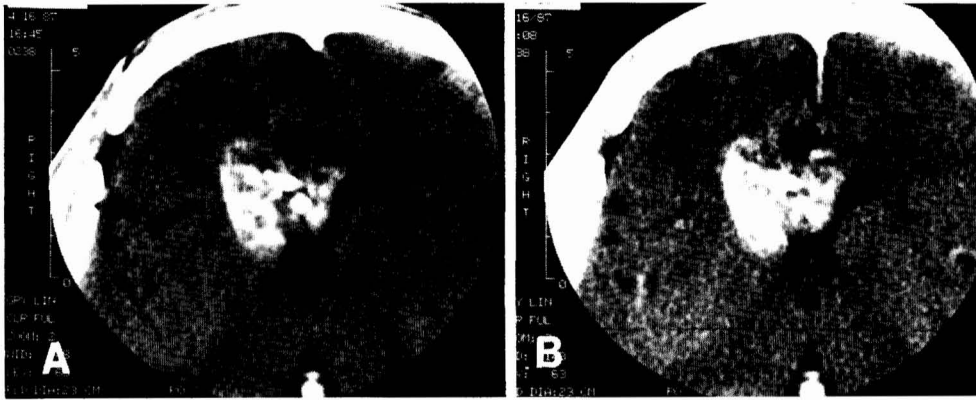


FIG. 2. Case 2. *A*: Non-contrast enhanced CT scan showing dense scattered calcification in a mixed density tissue matrix. *B*: Contrast-enhanced CT scan demonstrating some tissue matrix enhancement, especially along the right periphery.

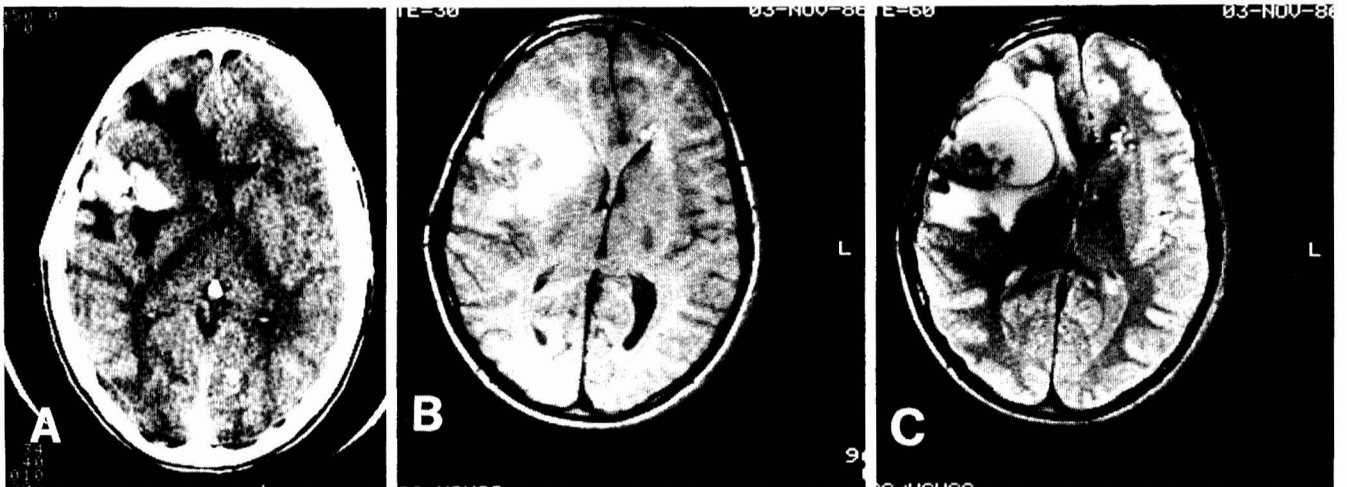


FIG. 3. Case 3. *A*: Non-contrast enhanced CT scan demonstrating a partially hemorrhagic, heavily calcified mass with surrounding edema. *B* and *C*: T1-weighted image and T2-weighted image showing hyperintense free methemoglobin anterior to mixed tissue matrix and calcification, with surrounding edema. Note the second, smaller malformation adjacent to the left frontal horn, also containing subacute blood, seen on the CT scan only in retrospect.

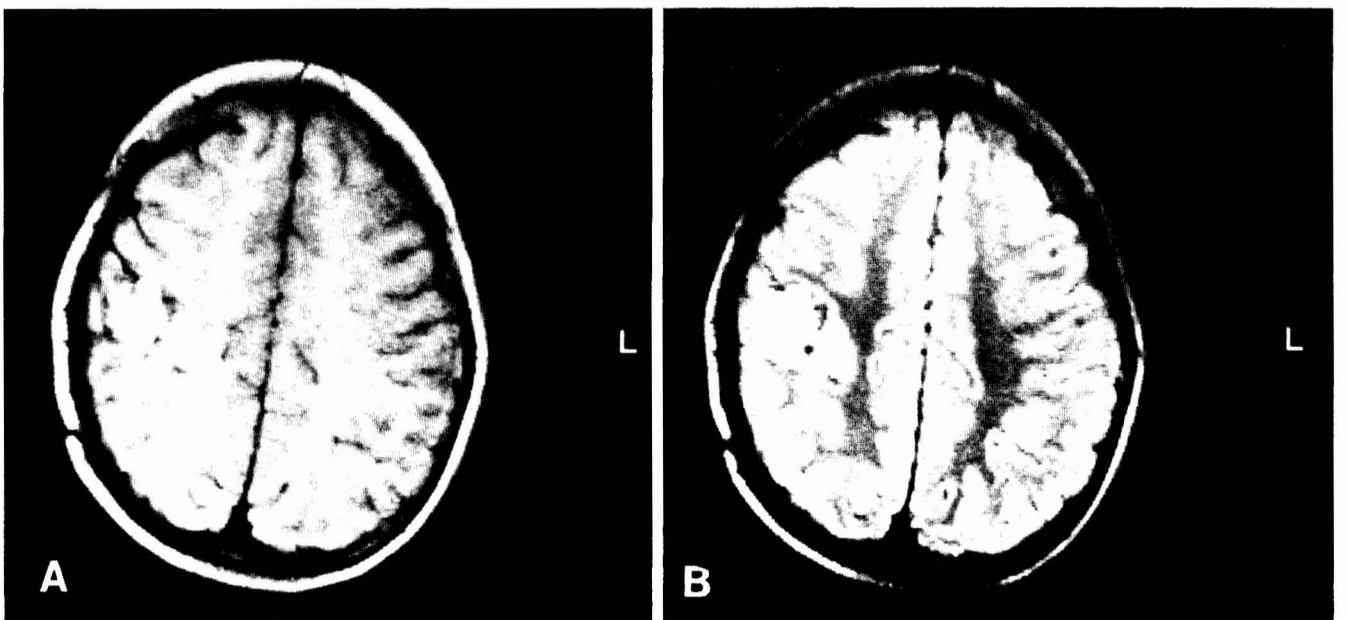


FIG. 4. Case 4. *A*: T1-weighted image consistent with subacute hemorrhage and tissue matrix. *B*: T2-weighted image showing central free methemoglobin with a rim of hemosiderin and peripheral edema.

slight left hemiparesis. The initial CT scan showed a 20-mm enhancing lesion near the right posterior internal capsule. The MRI scan showed a 20-mm lesion with T1 intensity that became more intense on T2 images. The angiogram was normal. The preoperative diagnosis was cerebrovascular malformation vs. glioma.

A stereotactic biopsy was done without complications. Histological examination showed gliosis, hemosiderin, and minute fragments of vessel walls with incomplete elastic laminae. The histological diagnosis was thrombosed AVM. Review of the pathological findings was consistent with vascular malformation of an uncertain type. There is a mild left hemiparesis and no seizures or headaches 9 months after biopsy.

Summary

A summary of these cases is presented in Table 1, and the histopathological findings are reviewed in Table 2.

DISCUSSION

Because of common radiographic findings and a spectrum of common histopathological findings, thrombosed AVMs and occult vascular malformations seem to have similar presentations and prognosis and indeed may represent the same disease entity (2, 8, 12, 14). Differentiation of the histopathology does not seem to aid practically in determining prognosis (12, 17). MRI is helpful in diagnosis, but not in determining the histopathological type of occult vascular malformation (11, 13). Thrombosed AVMs or occult vascular malformations with clinical symptoms should be excised when they are accessible because of their propensity to bleed (12).

The most common symptoms associated with thrombosed AVMs are seizures, headaches, and hemiparesis (2, 6, 16, 18). The incidence of associated intracerebral hemorrhage is not known, but such hemorrhage is not uncommon (3, 6, 12, 15, 16, 18). Thrombosed AVM has been diagnosed when the angiogram is negative for blush or shunt and the CT scan shows hyperdense or isodense lesions, generally less than 3 cm in diameter and often containing punctate or small dense foci of calcification (14).

The diagnosis of thrombosed AVM is tentative without an

adequate histological specimen. An angiographically occult lesion presenting without hemorrhage and with seizures may be interpreted as a low grade glioma (12, 18).

CT scanning has shown a sensitivity equal to that of MRI in the detection of cerebrovascular malformations, including thrombosed AVMs. Thrombosed AVMs usually appear as a circumscribed area of increased density, either homogeneous or mottled, with patchy or homogeneous enhancement with contrast material. This appearance can be confused with that of calcific or hemorrhagic low grade tumor (8, 11, 12, 14).

MRI, although no more sensitive than CT scanning in the detection of thrombosed AVMs, adds a degree of specificity, especially in the presence of subacute or chronic hematoma (8, 11, 14). In the posterior fossa, the absence of bone artifact on MRI is a well-established advantage over CT scanning. At this time, because of small case series numbers, the degree of increased specificity of MRI vs. CT has not been well established. Occult vascular malformations and AVMs display high signal intensity on T1- and T2-weighted images because of subacute and previous hemorrhage (11, 14). The absence of abnormal vessels in the area of the lesion demonstrated by MRI supports the diagnosis of thrombosed AVM (14). Hemosiderin acts as a paramagnetic substance that serves locally to distort the magnetic field. This results in signal dropout or void regions (14). Thrombosed AVMs that have undergone subclinical hemorrhage or "leaks" due to diapedesis of red blood cells through abnormal vessel walls will have a ring of signal void surrounding a region of T1 or T2 intensity (11, 14, 15). Regions of punctate or globular signal void are interpreted as calcification as they lack the serpiginous course of vessels with high flow. At present, because of small size and similar clinical presentations, it is difficult to differentiate with MRI the spectrum of occult cerebral vascular malformations (11, 14).

Thrombosed AVMs and occult vascular malformations are often indistinguishable. Histological verification is consistent in finding hemosiderin-stained tissues, gliosis, and areas of calcification. Abnormal vessels are usually identified, with some degree of thrombosis present. In some cases, there is doubt as to the type of vascular abnormality, indicating that a spectrum of pathology rather than a single entity may be present (6, 12, 16). In one series of 21 cases of occult vascular

TABLE 1
Clinical and Radiographic Findings

Case	Age/Sex	Symptoms	CT Findings	Angiography	MRI
1	29/F	Jacksonian seizures	Delayed enhancement, calcification	Normal	T1 high intensity peripherally; T2 hyperintense tissue matrix with peripheral hemosiderin
2	22/M	Headaches, seizures	Delayed enhancement, calcification	Few late draining veins	None
3	17/M	Headaches	Hematoma, calcification	Mild shunting and blush	T1 hyperintense secondary to methemoglobin and T2 hyperintense with peripheral isodensity (subacute hematoma and calcification)
4	10/F	Paresthesias, hemiparesis	Hemorrhage, calcification, enhancement	Normal	T1 hyperintense with subacute hemorrhage and T2 central hyperintensity with peripheral hemosiderin
5	28/F	Hemiparesis, headaches	Enhancement	Normal	T1 intense

TABLE 2
Pathology of Five Cases of AVM

Case	Original Report	Review Report
1	Thrombosed AVM surrounded by gliosis and hemosiderin	Vascular malformation, type uncertain, with areas of gliosis and hemosiderin deposition; no thrombosis present in abnormal endothelium-lined vascular channels
2	Thrombosed AVM; calcified vessels surrounded by gliosis and hemosiderin	Vascular malformation, type uncertain, with surrounding areas of gliosis and hemosiderin deposition; no acute thrombosis, but one vessel showed recanalization
3	Partially thrombosed AVM; hyalinized vessels with numerous capillary size channels surrounded by gliosis and hemosiderin	Cavernous angioma with hyalinized, sinusoidal, recanalized vessels; acute thrombosis and calcification of vessels; gliosis and hemosiderin deposition
4	Mixed thrombosed AVM-cavernous angioma; thrombus in some vessels surrounded by gliosis and hemosiderin; calcification	Cavernous angioma with vessels not identifiable as arteries or veins; hyalinization and calcification of a vessel; recent and remote thrombosis; gliosis and hemosiderin deposition
5	Thrombosed AVM; minute fragments of vessel wall with irregular and incomplete elastic laminae surrounded by gliosis and hemosiderin	Vascular malformation, type uncertain, with several small hyalinized, non-calcified juxtaposed arteries without thrombosis; gliosis and hemosiderin deposition

malformation, 8 cases were AVMs, 7 were venous angiomas, 1 was a cavernous angioma, 1 was capillary telangiectasia, and 4 cases showed mixed pathology (12). Thrombosis was found in 85% of this series. Hemosiderin, gliosis, and calcification were consistent findings. Ten of 21 cases required operation because of intracranial hematoma or subarachnoid hemorrhage. Of these 10 cases, 5 were AVMs, 3 were venous angiomas, 1 had mixed pathology, and 1 was indeterminate (12).

A review of 241 histologically documented cases of occult vascular malformation showed an approximate incidence of 43% AVMs, 31% cavernous angiomas, 10% venous angiomas, 4% capillary telangiectasia, and 11% unclassified malformations (12). A high percentage of these lesions exhibited degrees of thrombosis, and in more than half of these cases there was macroscopically visible hematoma or subarachnoid blood.

Because of small series sizes and unclear pathological diagnoses, the natural history of thrombosed AVMs is unclear as to the rate of hemorrhage and morbidity. Some authors have cited figures known for hemorrhage in AVMs as guides for the hemorrhage of thrombosed AVMs and occult vascular malformations; however, these are different entities and are not comparable. Wakai et al. found pathological evidence of hemorrhage in 101 of 172 cases of angiographically occult vascular malformations (16). Ninety of the 101 cases had intraparenchymal hematoma, and 8 had intraventricular hematoma. Further analysis revealed that 42 of 57 thrombosed AVMs had evidence of bleeding. In Wakai's personal series of histologically confirmed occult AVMs, all cases had partially thrombosed vessels and evidence of hemorrhage (16). The evidence of previous hemorrhage and varying degrees of thrombosis in thrombosed AVMs is supported by other authors (3, 6, 12, 18). It seems that the diagnosis of thrombosed AVM may not be indicative of a "burned out" or benign lesion. Indeed, our 2 cases of previously excised thrombosed

AVMs that presented with repeat hemorrhage may indicate a propensity toward recurrence and bleeding in subtotally excised lesions.

Because of the similar radiological, histological, and operative appearance of thrombosed AVMs and occult vascular malformations, the diagnosis of thrombosed AVM cannot be made with confidence. Indeed, there may not be an entity such as a completely thrombosed AVM that cannot recanalize to some degree and be at risk for hemorrhage. It seems that, regardless of the proposed preoperative diagnosis, angiographically occult vascular malformations and thrombosed AVMs may require excision when they present in accessible areas and correlate with neurological symptoms. Total excision rather than biopsy should be the goal because of the suspected propensity of thrombosed AVMs to bleed. Biopsy in deeper areas may be indicated to rule out glioma. It does not seem that the histopathological difference between thrombosed AVMs and other types of occult vascular malformations practically affects the clinical presentation, treatment, or prognosis of the patient. As MRI specificity increases for occult vascular malformations and thrombosed AVMs, more asymptomatic or marginally symptomatic lesions may be found. As our knowledge increases with regard to the natural history and rate of hemorrhage, surgical excision of accessible lesions will be considered more readily, and perhaps radiation therapy of inaccessible lesions may become an issue in the future.

ACKNOWLEDGMENTS

We thank Janet Sapp and Bridget Crabtree for their expert secretarial assistance and Dr. Mary K. Gumerlock for editorial assistance.

Received for publication, February 18, 1988; accepted, final form, May 11, 1988.

Reprint requests: John D. Ebeling, M.D., University of Missouri Hospital and Clinics, One Hospital Drive, Columbia, MO 65212.

REFERENCES

1. Burger PC, Vogel FS: *Surgical Pathology of the Nervous System and Its Covering*. New York, John Wiley and Sons, 1985, ed 2, pp 411-418.
2. Chin D, Harper C: Angiographically occult cerebral vascular malformations with abnormal computed tomography. *Surg Neurol* 20:138-142, 1983.
3. Cohen HCM, Tucker WS, Humphreys RP, Perrin RJ: Angiographically cryptic histologically verified cerebrovascular malformations. *Neurosurgery* 10:704-714, 1982.
4. Crawford JV, Russell DS: Cryptic arteriovenous and venous hamartomas of the brain. *J Neurol Neurosurg Psychiatry* 19:1-11, 1956.
5. Dyck P: Spontaneous thrombosis of an arteriovenous malformation. *Neurosurgery* 1:287-290, 1977.
6. Hashim ASM, Asakura T, Kiochi U, Kadota K, Awa H, Kusumoto K, Yamashita K: Angiographically occult arteriovenous malformations. *Surg Neurol* 23:431-439, 1985.
7. Hayman LA, Fox AJ, Evans RA: Effectiveness of contrast regimens in CT detection of vascular malformations of the brain. *AJNR* 2:421-425, 1981.
8. Kucharczyk W, Lemme-Pleghos L, Uske A, Brant-Zawadzki M, Doms G, Norman D: Intracranial vascular malformations: MR and CT imaging. *Radiology* 156:383-389, 1985.
9. Laster DW, Penry JK, Moody DM, Ball MR, Witcofski RL, Riela AR: Chronic seizure disorders: Contribution of MR imaging when CT is normal. *AJNR* 6:177-180, 1985.
10. Lee BCP, Herzberg L, Zimmerman RD, Deck MDF: MR imaging of cerebral vascular malformations. *AJNR* 6:863-870, 1985.
11. Lemme-Plaghos L, Kucharczyk W, Brant-Zawadzki M, Uske A, Edwards M, Norman D, Newton TH: MRI of angiographically occult vascular malformations. *AJR* 146:1223-1228, 1986.
12. Lobato RD, Perez C, Rivas JJ, Cordobes F: Clinical, radiological and pathological spectrum of angiographically occult intracranial vascular malformations. *J Neurosurg* 68:518-531, 1988.
13. Mitnick JS, Pinto RS, Lin JP, Rose H, Lieberman A: CT of thrombosed arteriovenous malformations in children. *Radiology* 150:385-389, 1984.
14. New PFJ, Ojemann RG, Davis KR, Rosen BR, Heros R, Kjellberg RN, Adams RD, Richardson EP: MR and CT of occult vascular malformations of the brain. *AJR* 147:985-993, 1986.
15. Steiger HJ, Tew JM Jr: Hemorrhage and epilepsy in cryptic cerebrovascular malformations. *Arch Neurol* 41:722-724, 1984.
16. Wakai S, Ueda Y, Inoh S, Nagai M: Angiographically occult angiomas: A report of thirteen cases with analysis of the cases documented in the literature. *Neurosurgery* 17:549-556, 1985.
17. Weisberg LA: Clinical and computed tomographic findings in thrombosed and cryptic cerebrovascular malformations. *Comput Radiol* 6:161-170, 1982.
18. Wharen RE, Scheithauer BW, Laws ER: Thrombosed arteriovenous malformations of the brain. *J Neurosurg* 57:520-526, 1982.

COMMENTS

This report raises important questions regarding the treatment of vascular malformations that are not evident on angiography except for possible mass effect. In 1982, we presented seven cases of thrombosed AVMs, emphasizing the importance of surgical exploration for the accurate diagnosis and treatment of these lesions, which are often difficult to distinguish from low grade glioma (1). With further improvement in imaging techniques and the introduction of MRI, it may now be possible accurately to diagnose these lesions in some cases without exploration. Ebeling et al. have now suggested that all angiographically occult vascular malformations, if accessible, be excised because of the risk of hemor-

rhage. Of the five cases presented, however, only Case 4 represents an angiographically occult lesion presenting with a hemorrhage. The pathological identification of hemosiderin staining around a vascular malformation cannot necessarily be equated to a lesion presenting clinically with hemorrhage. The natural history or risk of hemorrhage of an angiographically occult malformation is currently unknown. There is no doubt that some of these lesions do hemorrhage, but how many others do not? Over the ensuing few years, further reports will no doubt contribute to our knowledge regarding the natural history of these lesions and enable us to define more precisely which lesions should be excised. Until then, some will still require operation for accurate diagnosis, whereas others may be excised for seizure control. The question of what to do with an asymptomatic lesion will remain until the natural history is better defined.

Robert E. Wharen
Jacksonville, Florida

1. Wharen RE, Scheithauer BW, Laws ER: Thrombosed arteriovenous malformations of the brain: An important entity in the differential diagnosis of intractable focal seizure disorders. *J Neurosurg* 57:520-526, 1982.

Once again, as Ebeling et al. clearly show, the MRI scan is rapidly becoming the standard technique for early identification of the vascular lesion. The authors further link the so-called "cryptic malformation" to the lesion referred to as a "thrombosed" AVM. Hemosiderin deposition, indicating previous hemorrhage, was found in histological examination of all of their cases. This is consistent with the reports of others. The authors demonstrate in their case reports that these angiographically occult lesions are not to be trusted and may be a source of recurrent hemorrhage. In the five cases presented, the angiogram was completely normal in three in which the MRI showed evidence of hemorrhage. This series is small, but if these assumptions prove true, any vascular malformation seen on the MRI scan (whether it has bled or is angiographically demonstrable) must raise concern for both mortality and morbidity. Recent reports indicate that late bleeding from arteriovenous malformations in asymptomatic patients occurs much more frequently than most of us had expected (1).

If these so-called thrombosed malformations do prove to be a serious threat, and this can only be determined for certain after a nonoperative series becomes available, then several questions arise: How should we manage malformations that have been thrombosed: with surgery, embolization, or radiotherapy? Late recanalization and hemorrhage is being recognized more frequently. For the lesion that has not hemorrhaged, is occult angiographically, and is not easily accessible surgically, a nonoperative approach combined with follow-up MRI to evaluate for hemorrhage seems to be favored.

Robert R. Smith
Jackson, Mississippi

1. Brown RD Jr, Wiebers DO, Forbes G, O'Fallon O, Piepgras DG, Marsh R, Maciunas RJ: The natural history of unruptured intracranial arteriovenous malformations. *J Neurosurg* 68:352-358, 1988.