

# Checkerboard Visual Field Defect in Occipital Stroke

Sarah Kamal, BA, Bayan A. Al Othman, MD, Ashwini T. Kini, MD, Andrew G. Lee, MD

**Abstract:** A 74-year-old man with vasculopathic risk factors presented to the emergency room with a chief complaint of peripheral vision loss resulting from an intracranial hemorrhage in his right parietal and occipital lobes. Urgent craniotomy and ventriculostomy led to a stable clinical condition with subsequent development of a crossed quadrant homonymous hemianopsia (checkerboard visual field) due to a new right parieto-occipital infarct superimposed on a prior left occipital infarct. This uncommon visual field defect represents juxtaposed homonymous quadrantanopias that produce a striking checkerboard appearance that is almost pathognomonic for bilateral occipital lesions.

**Journal of Neuro-Ophthalmology 2020;40:e13–14**

**doi: 10.1097/WNO.0000000000000892**

© 2020 by North American Neuro-Ophthalmology Society

A 74-year-old man presented with acute, bilateral, simultaneous visual loss. Medical history was significant for congenital aortic valve disease, hypertension, hyperlipidemia, coronary artery disease, and prior carotid endarterectomy and stenting. His medications included low-dose aspirin and prasugrel. Computed tomography (CT) scan of the brain showed an acute large right parieto-occipital hemorrhage with shift and mass effect and a prior left occipital hypodensity consistent with prior ischemic occipital infarction (Fig. 1). He subsequently underwent an emergent right occipitoparietal craniotomy and decompression of the hemorrhage. Postoperative CT scans of the brain demonstrated an interventricular hemorrhage and bifrontal

pneumocephalus and hydrocephalus, which necessitated a ventriculostomy. Serial CT scans showed evolution and resolution of the hemorrhage and hydrocephalus and the ventriculostomy catheter was removed.

Neuro-ophthalmic examination revealed a visual acuity of 20/20 in both eyes. Both pupils were reactive to light with no relative afferent pupillary defects or anisocoria. External, anterior segment, intraocular pressure and dilated fundus examinations were normal. Automated perimetry (Humphrey visual field 24-2) demonstrated a right, superiorly congruous homonymous quadrantanopia with a juxtaposed left, inferiorly congruous, macular sparing homonymous quadrantanopia (Fig. 2). These findings illustrate a crossed quadrant homonymous hemianopsia (i.e., checkerboard visual field).

## DISCUSSION

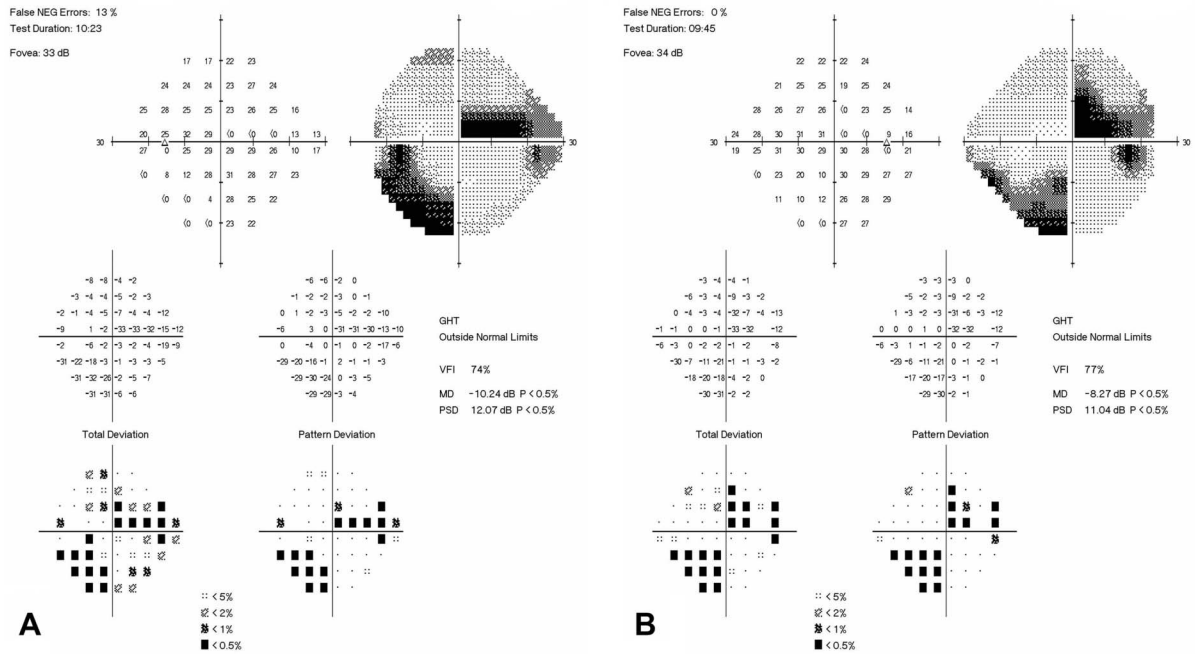
Our patient presented with a crossed quadrant homonymous hemianopsia (checkerboard visual field) due to an acute parieto-occipital infarct superimposed on a prior asymptomatic chronic occipital infarct. This uncommon visual field defect represents juxtaposed homonymous quadrantanopias that produce a striking checkerboard appearance that is almost pathognomonic for bilateral occipital lesions. Homonymous hemianopias and quadrantanopias may be symptomatic or asymptomatic depending on various factors including the extent of field loss, cognitive status, and fixation involvement. Patients often misinterpret homonymous field defects as monocular vision loss on the side of the field defect, highlighting the importance of bilateral visual field testing in patients with monocular complaints.

To the best of our knowledge, the checkerboard visual field defect has been reported worldwide in 12 prior cases, initially presenting in the literature in 1891 (1–4). The most common cause (as in our case) is an ischemic or hemorrhagic infarct—the infarct may be associated with a spontaneous thromboembolic event, dissection, or cervical vertebral trauma (3). Other previous causes identified have included multiple sclerosis (2 cases reported), syphilis, and

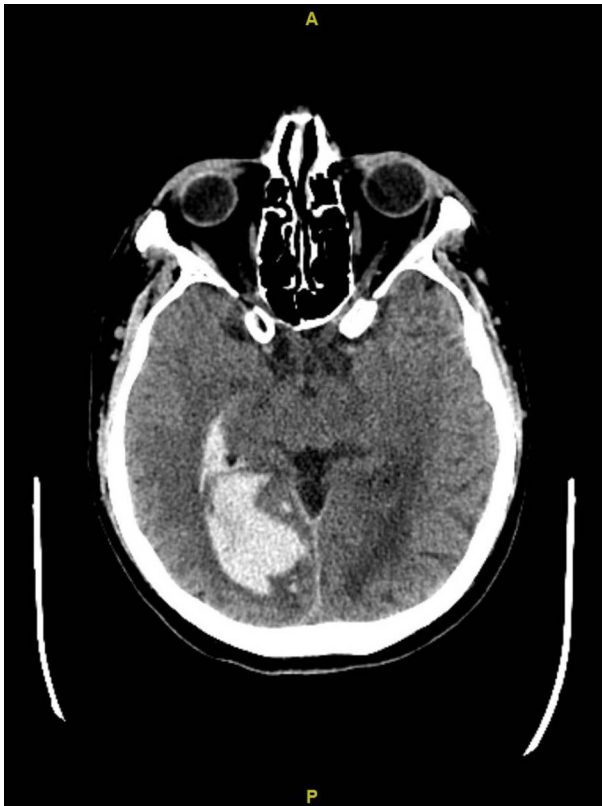McGovern Medical School (SK), Houston, Texas; Department of Ophthalmology (BAAO, ATK, AGL), Blanton Eye Institute, Houston Methodist Hospital, Houston, Texas; Departments of Ophthalmology, Neurology, and Neurosurgery (AGL), Weill Cornell Medicine, New York, New York; Department of Ophthalmology (AGL), University of Texas Medical Branch, Galveston, Texas; University of Texas MD Anderson Cancer Center (AGL), Houston, Texas; Department of Ophthalmology (AGL), Texas A and M College of Medicine, Bryan, Texas; and Department of Ophthalmology (AGL), The University of Iowa Hospitals and Clinics, Iowa City, Iowa.

The authors report no conflicts of interest.

Address correspondence to Andrew G. Lee, MD, Blanton Eye Institute, Houston Methodist Hospital 6560 Fannin Street Suite 450 Houston, TX 77030; E-mail: aglee@houstonmethodist.org



**FIG. 1. A and B,** Humphrey visual field testing (24-2 HVF) shows right, denser superiorly congruous homonymous quadrantanopia with a juxtaposed left, denser, inferiorly congruous, macular sparing homonymous quadrantanopia (i.e., the checkerboard field).



**FIG. 2.** Computed tomography (CT) scan of the brain shows the right parieto-occipital hemorrhage and the left occipital hypodense area.

a necrotizing ependymomyelitis (1,2,4). Clinicians should recognize the juxtaposed, crossed quadrant, homonymous quadrantanopia (the checkerboard visual field), understand the localizing value of the finding, and be aware that the bilateral visual pathway events may be simultaneous or sequential.

**REFERENCES**

1. **Cesareo M,** Pozzilli C, Ristori G, Roscioni AM, Missiroli A. Crossed quadrant homonymous hemianopsia in a case of multiple sclerosis. *Clin Neurol Neurosurg.* 1995;97:324–327.
2. **Cross SA,** Smith JL. Crossed-quadrant homonymous hemianopsia. The “checkerboard” field defect. *J Clin Neurol Ophthalmol.* 1982;2:149–158.
3. **Dyer JA,** Hirst LW, Vandeleur K, Carey T, Mann PR. Crossed-quadrant homonymous hemianopsia. *J Clin Neuro Ophthalmol.* 1990;10:219–222.
4. **Tamhankar MA,** Markowitz CE, Galetta SL. Checkerboard fields in multiple sclerosis. *J Neurol Neurosurg Psychiatry.* 2005;76:268.