

UCSF

UC San Francisco Previously Published Works

Title

Bilateral basal ganglia infarcts presenting as rapid onset cognitive and behavioral disturbance

Permalink

<https://escholarship.org/uc/item/0vd0q28v>

Journal

Neurocase, 26(2)

ISSN

1355-4794

Authors

Hellmuth, Joanna
Casaletto, Kaitlin
Cuneo, Richard
[et al.](#)

Publication Date

2020-03-03

DOI

10.1080/13554794.2020.1728341

Peer reviewed



Published in final edited form as:

Neurocase. 2020 April ; 26(2): 115–119. doi:10.1080/13554794.2020.1728341.

Bilateral basal ganglia infarcts presenting as rapid onset cognitive and behavioral disturbance

Joanna Hellmuth, MD, MHS¹, Kaitlin Casaletto, PhD¹, Richard Cuneo, MD², Katherine L. Possin, PhD¹, William Dillon, MD³, Michael D. Geschwind, MD, PhD¹

¹Memory and Aging Center, Department of Neurology, University of California, San Francisco, CA, US

²Department of Neurology, University of California San Francisco, CA, US

³Department of Radiology, University of California, San Francisco, CA, US

Abstract

We describe a rare case of a patient with rapid onset, prominent cognitive and behavioral changes who presented to our rapidly progressive dementia program with symptoms ultimately attributed to bilateral basal ganglia infarcts involving the caudate heads. We review the longitudinal clinical presentation and neuropsychological testing for this patient, and discuss the implicated basal ganglia and frontal lobe neuroanatomy.

Keywords

Bilateral basal ganglia; caudate head; frontal lobe syndrome; executive function; spatial working memory

Introduction

Rapidly progressive dementias (RPDs) can present with a cognitive and behavioral decline and require swift diagnosis, given that some causes are treatable. While RPDs are typically associated with an underlying prion disease, additional non-prion etiologies include neurodegenerative disease, autoimmune encephalopathies, infectious causes, and vascular disease (Geschwind, 2016). We describe the clinical course and longitudinal neuropsychological testing of a patient who presented with a rapid onset cognitive and

Correspondence to: Dr. Joanna Hellmuth, 675 Nelson Rising Lane, Suite 190, San Francisco, California, 94158. Telephone: 415/514-2384. Fax: 415/353-8292. joanna.hellmuth@ucsf.edu.

Author contributions: Dr. Hellmuth: acquisition of data, analysis, interpretation, draft of the manuscript, and critical revision of the manuscript for important intellectual content. Dr. Casaletto: acquisition of data, analysis, interpretation, draft of the manuscript, and critical revision of the manuscript for important intellectual content. Dr. Possin: acquisition of data, analysis, interpretation, draft of the manuscript, and critical revision of the manuscript for important intellectual content. Dr. Cuneo: acquisition of data, draft of the manuscript, and critical revision of the manuscript for important intellectual content. Dr. Dillon: analysis and interpretation of data, and critical revision of the manuscript for important intellectual content. Dr. Geschwind: acquisition of data, analysis, interpretation, draft of the manuscript, and critical revision of the manuscript for important intellectual content.

Disclosure Statement: Dr. Hellmuth reports no disclosures. Dr. Casaletto reports no disclosures. Dr. Cuneo reports no disclosures. Dr. Dillon reports no disclosures. Dr. Geschwind reports consulting for Advanced Medical Inc., Best Doctors Inc., Grand Rounds Inc., Second Opinion Inc., Gerson Lehrman Group Inc., Guidepoint Global LLC, MEDACorp, LCN Consulting, Optio Biopharma Solutions, Teva Pharmaceuticals, Biohaven Pharmaceuticals, Quest Diagnostics and various medical-legal consulting.

behavioral change and was found to have bilateral basal ganglia infarcts with caudate head involvement.

Case report

An 81-year-old man, a retired lawyer with hypertension, hyperlipidemia, and a pacemaker for sinus node dysfunction was referred for evaluation of a rapidly progressive dementia (RPD), consisting of new onset confabulation, disorientation, and disinhibition, with a concern for evolution of symptoms. These behaviors started several days into a trip to Asia with his partner, when he awoke markedly confused about his location and confabulating about a professional appointment he needed to attend. This stark behavioral change prompted arrangements to return to the United States that day, and he experienced emesis and diarrhea on the flight back. Upon his return home, family noticed that he now became tearful to sentimental stimuli, was often disoriented to time and place (e.g. at times thought he was in the incorrect state and dressed for work at 4 AM, although he was retired), exhibited poor memory of recent events, and frequently confabulated (e.g. discussed a recent fishing trip that never occurred). This was interpreted as a fluctuating mental status. He engaged in overly familiar touching with family members and made disinhibited comments in public to women about their appearance. In retrospect, the family recalls an odd conversation approximately a month prior to symptom onset when the patient discussed an application to join the National Rifle Association, which was not consistent with his prior interests or character. He was brought to his primary care physician, who obtained a head CT ten days after the symptom onset. The head CT revealed bilateral caudate head and basal ganglia hypodensities (Figure 1a–b), interpreted by the local radiologist as “lacunar infarctions.” Unfortunately, no further explanation or diagnosis was provided to the family. The family later brought him to a neurologist in another state who was concerned about the unusual symptom onset during international travel, possible preceding behavioral changes, and persistent and potentially evolving behavioral and cognitive deficits. The patient was referred to our tertiary neurology center for a rapidly progressive dementia evaluation.

The patient denied headache or neck pain, was afebrile and had a neurologic examination notable only for absent vibratory sense to the ankles bilaterally and some mild difficulty with tandem gait. He displayed behaviors throughout the evaluation that often required redirection: he was disinhibited (e.g. making inappropriately personal comments to the examiner such as, “Are we going to get married? Joking!”); distractible (e.g. talking during testing); and impulsive (e.g. starting tests before listening to the instructions).

Detailed neuropsychological testing three months after symptom onset revealed prominent executive dysfunction and impaired retrieval of new verbal and visual information after delays (Table 1). Regarding the executive dysfunction, he was slow and error prone on the Delis-Kaplan Executive Function System (D-KEFS) Trail Making Test-Switching condition, which tests visual set-shifting, and he unable to complete the practice trials of a separate visual set shifting task (DKEFS Design Fluency, Switching). He displayed a high number of errors on numerous tasks, and was prone to interference. One example of this is that he falsely recalled “sander” as a tool on verbal memory testing (California Verbal Learning Test-Short Form; CVLT-SF) after discussing political figure Bernie Sanders. He also

demonstrated difficulties initiating and generating novel verbal and visual information (DKEFS Design Fluency and Verbal Fluencies) and poor working memory (digit span backwards). His episodic memory was impaired with a shallow learning curve during the CVLT-SF list-learning task with a high tendency for erroneous intrusions (i.e., false recalling), particularly during cueing and recognition trials after a 10-minute delay. Though his delayed recall was average for structured verbal information (Wechsler Memory Scale – Fourth Edition; WMS-IV Logical Memory stories) and visual information (WMS-IV Visual Reproductions), he continued to demonstrate false elaborations when recalling the information (e.g., when recalling a story about a woman who was robbed, he noted, “It was about a poor lady...who was basically out on the street.”). He demonstrated strengths in language (receptive vocabulary and confrontation naming), processing speed (Wechsler Adult Intelligence Scale – Fourth Edition; WAIS-IV Coding and DKEFS Trail Making Test, Motor Speed), and visuoconstructional tasks (WMS-IV Visual Reproductions Copy), and reported minimal depressive symptoms on the Geriatric Depression Scale.

He also was administered an experimental cognitive neuroscience paradigm that separately assessed spatial working memory for locations defined in self-based (egocentric) or landmark-based (allocentric) coordinates. These two conditions of the assessment show a neuroanatomical double dissociation such that egocentric performance is associated with caudate volumes, specifically the dorsolateral caudate head, and allocentric performance with hippocampal volumes, specifically the intermediate and posterior regions (Possin *et al.*, 2017). His performance was compared to a sample of 15 neurologically healthy age-matched (81+/-3) older adults. Although impaired on both conditions, he had greater impairment on the egocentric ($z=-4.6$) than allocentric ($z=-1.8$) conditions.

Normal studies included a serum paraneoplastic panel (Mayo Clinic), basic CSF studies, IgG index, and 1-hour EEG. A hypercoagulability panel was normal except for an elevated Factor VIII level of 216% activity (normal range 43–168%). A transthoracic echocardiogram with bubble study revealed a patent foramen ovale versus small atrial septal defect. A sleep study revealed severe obstructive sleep apnea, and he was started on CPAP. He could not undergo brain MRI due to being pacemaker dependent. Suspecting potential anomalous neurovasculature leading to bilateral strokes, he underwent a CT head, and a CT angiogram head/neck 51 days after rapid symptom onset. This revealed a congenitally hypoplastic right anterior cerebral artery A1 segment with a prominent left A1 segment, and encephalomalacia in the putamen and globus pallidi (Figure 1d–f). The bilateral caudate head hypodensities prominent on his initial head CT were no longer evident (Figure 1d,e). He was followed by a neurovascular specialist.

During the eight months after symptom onset, the patient had great improvement in confabulation (per the family, going from a 9/10 to a 2/10) and better subjective short-term memory. He still exhibited impulsive, disinhibited behavior, such as commenting on the appearance of others, using coarse language, overly familiar touching, and throwing used tissues on the floor. He also continued to be tearful to minimally emotional stimuli, and now had compulsive behaviors such as foot tapping and rubbing.

Repeat neuropsychological testing was conducted nine months after onset of symptoms and reliable change indices (95% confidence interval) were calculated (Table 1). He demonstrated significantly improved generativity (DKEFS Design Fluency), processing speed (WAIS-IV Coding), and set-shifting (DKEFS Trail Making Test and Design Fluency Switching), though the latter still remained in the impaired range. Regarding executive functions, he continued to demonstrate high levels of intrusions and perseverations across tasks. On memory tasks, he demonstrated significantly improved immediate recall, consistent with his improved executive functions, though he continued to have difficulty recalling novel verbal and visual information after longer delays. Qualitatively, although he continued to demonstrate mild intrusive and elaborative errors such as recalling words from a different task, these were significantly less so than in his previous evaluation, at which time he mixed personal information of the examiner with memory testing information. His basic visuoconstructional abilities and language abilities remained normal and unchanged. On the cognitive neuroscience measure of spatial working memory, he was still severely impaired on the egocentric condition, although he significantly improved (from $z=-4.6$ to -2.7), and mild improvement was observed on the allocentric condition (from $z=-1.8$ to -1.2). Behaviorally, he continued to display personality changes, such as sarcasm and cursing during testing, and mildly impulsivity, such as falsely drawing a cow on the visual memory test. Though he was less disinhibited during testing, he still demonstrated behavioral dyscontrol. For instance, he took what he thought was a covert picture of a female research coordinator on his phone because he wanted to “set her up” with his grandson, and his self-generated sentence on the Mini Mental State Exam was, “I love women!”.

Approximately a year after symptom onset, he developed new onset vertigo with nausea with vomiting after cardiac catheterization. This was identified as a new right cerebellar stroke, identified on head CT, which also showed the original bilateral caudate infarcts (Figure 1g–i). After the cerebellar stroke, he had mild right upper extremity dysmetria and difficulty with tandem gait. His family noticed worsened cognitive functioning. By 22 months after initial symptom onset, the motor symptoms of the cerebellar stroke had resolved, however he continued to display disinhibition and impulsive behaviors such as eating from bulk food bins in the grocery store, and inappropriate touching of female family members. He was seen in a behavioral consultation clinic to address these issues.

Discussion

Despite initial concerns for a rapidly progressive dementia caused by an autoimmune or prion mechanism, the patient’s cognitive and behavioral syndrome is best explained by a stroke to an anomalous, single origin recurrent artery of Heubner from the dominant left anterior cerebral artery A1 segment, leading to bilateral basal ganglia infarcts, particularly the caudate heads (Matsuda et al., 2018; Kumral, Evyapan & Balkir, 1999; Mendez, Adams & Lewandowski, 1989). This may have been facilitated by his elevated Factor VIII level. The initial CT findings of bilateral caudate hypodensities were largely isodense on repeat neuroimaging at 51 days, possibly due to resolution of acute edema or the fogging effect; the latter can occur due to a delayed infiltration of phagocytic cells into brain parenchyma (Bech & Skyhoj, 1981; Scutto, Cappabianca, Melone, & Puoti, 1998). While the referring

physician considered Creutzfeldt-Jakob disease (CJD) based on the concerning, new history of prominent behavioral disturbances, CJD does not present with CT hypodensities and rarely has an acute onset (Paterson, Takada & Geschwind, 2012; Geschwind, 2016). In contrast, cerebrovascular disease can cause the appearance of a rapidly progressive dementia in patients, and comprises 2 to 12% of cases at major rapidly progressive dementia referral centers (Geschwind, 2016). Additionally, it's possible that the patient's subsequent cerebellar stroke resulted in an additional cerebellar cognitive affective disorder (Schmahmann, 2018).

This case report provides a comprehensive, longitudinal behavioral and neuropsychological characterization of a patient with bilateral basal ganglia infarcts involving the dorsal caudate. The patient initially presented with significant confabulation that decreased over time, and may have contributed to the initial concerns of disorientation, as he seemed to frequently confabulate about his location. At the first neuropsychological evaluation, his most impaired domain was executive functioning with significant set-shifting difficulties, poor generativity, and limited working memory on testing, consistent with caudate lesions (Mendez, Adams & Skoog Lewandowski, 1989). He was also disproportionately impaired on spatial working memory for the locations of stimuli coded in an egocentric reference frame, as compared to an allocentric reference frame; these findings are attributed to caudate head neuroanatomy (Possin *et al.*, 2017). His executive dysfunction also likely impacted his memory testing performance through intruding novel items and false elaboration, particularly after a delay. He demonstrated a shallow verbal learning curve, and though error-prone, his delayed recall mildly benefited from cueing and recognition. This memory pattern suggests more prominent difficulty with strategic organization and retrieval of information rather than an information storage deficit. In contrast, his processing speed, basic visuoconstructional, and language abilities were normal. After the six-month test-retest interval (9 months after symptom onset), he demonstrated significantly improved executive functions, processing speed, immediate recall, and egocentric working memory. His set-shifting, working memory, including egocentric working memory, and episodic delayed retrieval remained in the impaired range. Behaviorally, aspects of his social disinhibition and impulsive nature remained nearly two years after initial presentation.

This patient's marked executive dysfunction and behavioral dyscontrol, marked by social disinhibition and initial confabulation, underscores the affected neuroanatomy connecting the basal ganglia to frontal networks (Mendez, Adams & Skoog Lewandowski, 1989). His case demonstrates how injury to the caudate heads may lead to disruption of the associative and limbic striatal loops and cause a frontal disconnection syndrome. The associative loop receives direct inputs from dorsolateral, pre-supplementary motor, and posterior parietal cortices, areas that subserve set-shifting, self-monitoring, and working memory (Chow & Cummings, 2007). The ventromedial striatum in the limbic loop receives inputs from orbital and medial prefrontal cortices, regions that when injured can result in risky decision-making, disinhibition and impulsivity. The striatum and globus pallidi are also involved in circuits of the dorsolateral and orbitofrontal cortices. (Chow & Cummings, 2007; Mrabet, Mrad-Ben Hammouda, Abroug, Smiri, & Haddad, 1994). Other rare case reports involving bilateral caudate infarcts document a cognitive and behavioral syndrome that can include abulia, inattention, impaired memory, and ventromedial caudate infarcts have similarly been

associated with disinhibition and impulsivity. (Mrabet, Mrad-Ben Hammouda, Abroug, Smiri, & Haddad, 1994; Lim & Yap, 1999; Wang, 1991). This case demonstrates how potential disruption of both associative and limbic loops by stroke can lead to a sudden, dysregulated executive syndrome that occurs in the absence of significant cortical damage or atrophy. This case study also adds to the evidence that the caudate is critical for egocentric spatial processing. (Possin *et al.*, 2017; Postle & D'Esposito, 2003; Bohbet, Lerch, Thorndycraft, Iaria & Zijdenbos, 2007). This patient illustrates how rapid onset cognitive and behavioral symptoms can be caused by bilateral basal ganglia infarcts involving the caudate.

Acknowledgments

Study funding: J.H. was supported by NIH/NIMH grant K23MH114724. K.C. was supported by Larry L. Hillblom Fellowship Grant 2017-A-004-FEL and NIH-NIA K23AG058752. M.D.G. was supported by NIH/NIA grant R01 AG AG031189, Alliance Biosecure and the Michael J. Homer Family Fund. K.L.P. was supported by the National Institute on Neurological Disorders and Stroke (UG3 NS105557) and the Global Brain Health Institute.

He receives research funding from Quest Diagnostics, Teva Pharmaceuticals and Biohaven Pharmaceuticals. He has received speaking honoraria for various medical center lectures and from Oakstone publishing. Dr. Geschwind serves (volunteer) on the board of directors for San Francisco Bay Area Physicians for Social Responsibility and on the editorial board of *Dementia & Neuropsychologia*. Dr. Possin received research funding from Quest Diagnostics. Dr. Hellmuth takes full responsibility for the data, analyses, and interpretation. The author has received consent from the patient (and the patient's family) whose case is described.

References:

- Geschwind MD. Rapidly Progressive Dementia. *Continuum* 2016; 22:510–537. [PubMed: 27042906]
- Possin KL, Kim H, Geschwind MD, Moskowitz T, Johnson ET, Sha SJ et al. Egocentric and allocentric visuospatial working memory in premotor Huntington's disease: a double dissociation with caudate and hippocampal volumes. *Neuropsychologia* 2017; 101:57–64. [PubMed: 28427989]
- Matsuda W, Sonomura T, Honma S, Ohno S, Goto T, Hirai S et al. Anatomical variations of the recurrent artery of Heubner: number, origin, and course. *Anatomical Science International* 2018; 93:317–322.
- Kumral E, Evyapan D, Balkir K. Acute caudate vascular lesions. *Stroke* 1999; 30(1):100–108. [PubMed: 9880396]
- Mendez MF, Adams NL, Lewandowski KS. Neurobehavioral changes associated with caudate lesions. *Neurology* 1989; 39(3):349–354 [PubMed: 2927642]
- Bech SE and Skyhoj OT. Transient disappearance of cerebral infarcts on CT scan, the so-called fogging effect. *Neuroradiology* 1981; 22:61–65. [PubMed: 7301107]
- Scutto A, Cappabianca S, Melone MB, Puoti G. MRI “fogging” in cerebellar ischaemia: case report. *Neuroradiology* 1998; 39(11): 785–787.
- Paterson RW, Takada LT, Geschwind MD. Diagnosis and treatment of rapidly progressive dementias. *Neurology Clinical Practice* 2012; 2(3): 187–200. [PubMed: 23634367]
- Schmahmann JD. The cerebellum and cognition. *Neuroscience Letters* 2018; S0304-3940(18)30467-1 [Epub ahead of print].
- Chow TW, Cummings JL. Chapter 3. Frontal-Subcortical Circuits In: Miller B, ed. *The Frontal Lobes*, 2nd Edition, New York: The Guilford Press, 2007: 3–26.
- Mrabet A, Mrad-Ben Hammouda I, Abroug Z, Smiri W, Haddad A. Bilateral infarction of the caudate nuclei. *Revue Neurologique* 1994; 150(1):67–69. [PubMed: 7801044]
- Lim JKH and Yap KB. Bilateral caudate infarct – a case report. *Annals Academy of Medicine Singapore* 1999; 28:567–71.
- Wang PY. Neurobehavioral changes following caudate infarct. *Zhingham Yi Xue Zhi* 1991; 47(3):199–203.

- Postle BR and D'Esposito M. Spatial working memory activity of the caudate nucleus is sensitive to frame of reference. *Cognitive, Affective & Behavioral Neuroscience* 2003; 3(2): 133–144.
- Bohbot VD, Lerch J, Thorndyraft B, Iaria G, Zijdenbos AP. Gray matter differences correlate with spontaneous strategies in a human virtual navigation task. *Journal of Neuroscience* 2007; 27(38): 10078–10083. [PubMed: 17881514]

Author Manuscript

Author Manuscript

Author Manuscript

Author Manuscript

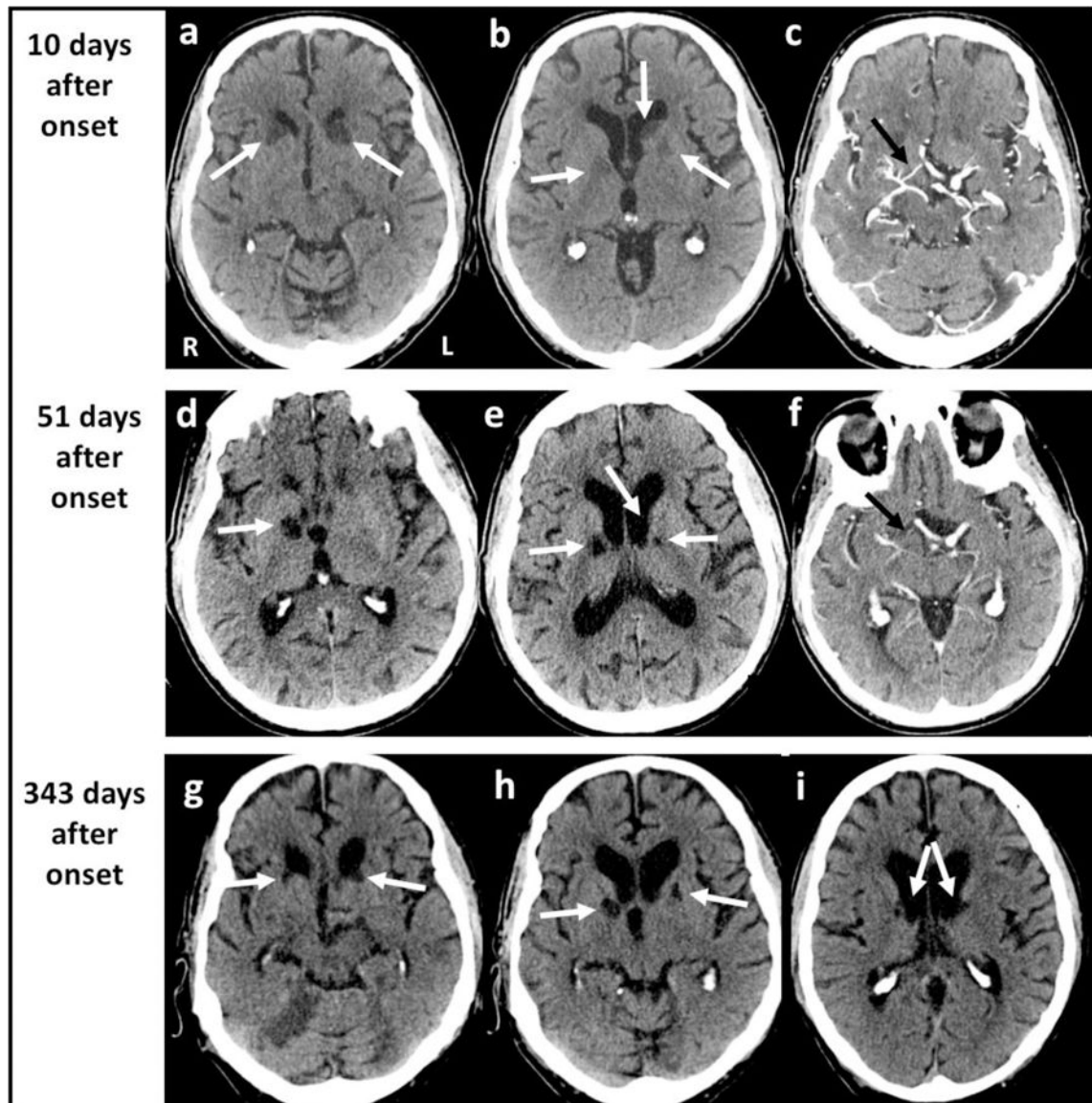


Figure 1.

Head CT at 10, 51, and 343 days after symptom onset. Orientation is radiologic. (a, b) Head CT and (c) CT with contrast 10 days after symptom onset revealing bilateral caudate and left anterior putamen and right basal ganglia hypodensities (white arrows); (d, e) Head CT and (f) CT angiogram 51 days after symptom onset with possible fogging of previously observed bilateral caudate head infarcts, showing bilateral encephalomalacia to the basal ganglia and internal capsule infarcts (white arrows); contrast scans (c, f) indicate congenitally hypoplastic right anterior cerebral artery A1 segment (black arrows); (g, h, i) Head CT 343 days after symptom onset revealing completed bilateral basal ganglia, including caudate head infarcts with new symptomatic right cerebellar infarct (g).

Table 1.

Neuropsychological performance over time.

Cognitive domain	Neuropsychological measure	3 months after onset	9 months after onset	95%CI Reliable Change Index
Global	MMSE	26/30 (-1 orientation, -3 delayed recall)	27/30 (-1 orientation, -2 delayed recall)	Stable
Episodic memory	CVLT-SF, 9 item			
	Learning Trials 1-4	3, 3, 5, 3	5, 4, 5, 6	Improved
	30' Recall	4 (1 intrusion)	4 (1 intrusion)	Stable
	10' Recall	2 (1 intrusion)	1 (3 intrusions)	Stable
	Cued Recall	5 (4 intrusions)	1 (4 intrusions)	n/a
	Recognition	9/9 (8 false positives)	9/9 (7 false positives)	Stable
	WMS-IV Logical Memory			
	Immediate Recall	25/50 (4 intrusions)	28/50 (3 intrusions)	Stable
	20' Recall	9/50 (5 intrusions)	15/50 (1 intrusion)	Stable
	WMS-IV Visual Reproductions			
	Immediate Recall	30/43	26/43	Decline
	20' Recall	8/43	0/43 (<i>drew a cow</i>)	Decline
	Recognition	3/7	2/7	n/a
Executive functions	Digit Span (longest)			
	Forward	7	7	Stable
	Backwards	4	4	Stable
	DKEFS Trail Making Test			
	Number Sequence	44"	40"	Stable
	Letter Sequence	31"	33"	Stable
	Switching	200" (4 errors)	95" (1 error)	Improved
	DKEFS Design Fluency			
	Filled Dots	6 (5 repetitions, 5 errors)	11 (6 repetitions)	Improved
	Empty Dots	4 (7 repetitions, 3 intrusions)	5 (8 repetitions, 2 intrusions)	Stable
	Switching	<i>Unable to complete practice trial</i>	2 (9 errors)	Improved
	Verbal Fluency			
	D words/60"	8 (1 repetition, 1 error)	12	Stable
	Animals/60"	13 (4 errors)	12	Stable
Processing speed	DKEFS Trail Making Test	55"	39"	Stable
	Motor Speed			
	Visual Scanning	30"	25"	Stable
	WAIS-IV Coding	46	61	Improved

Cognitive domain	Neuropsychological measure	3 months after onset	9 months after onset	95%CI Reliable Change Index
Language	Boston Naming Test-abbreviated	15/15	15/15	Stable
	Peabody Picture Vocab-revised	15/16	16/16	Stable
Visuospatial	MMSE Intersecting Pentagons	1/1	1/1	n/a
	Visual Object Space Perception Number Location	7/10	9/10	Stable
	WMS-IV Vis. Reproductions Copy	42/43	<i>n/a</i>	n/a
Mood	Geriatric Depression Scale	3/30	6/30	Stable

MMSE = Mini Mental State Examination; CVLT-SF = California Verbal Learning Test – short form; WMS-IV = Wechsler Memory Scale – 4th edition; DKEFS = Delis Kaplan Executive Function System; 95%CI Reliable Change Index = 95% confidence interval reliable change index, as determined via standard error of measurements as reported in the published technical manuals; “n/a” indicates lack of reliable change data.