

PROSOPAGNOSIA AND AGNOSIA FOR NONCANONICAL VIEWS

AN AUTOPSIED CASE

by T. LANDIS, M. REGARD, A. BLIESTLE and P. KLEIHUES

(From the Department of Neurology and Neuropathology Laboratory, Institute of Pathology, University Hospital, Zürich, Switzerland)

SUMMARY

It has been postulated that for prosopagnosia to occur, bilateral lesions of the central visual system are usually necessary. All but 1 of the 10 previously documented cases that came to autopsy showed this pattern. However, the long survival period after the onset of prosopagnosia in most of these patients limits the value of the autopsy findings for clinicopathological correlation. A patient is presented who died 10 days after she had developed prosopagnosia, topographagnosia and an agnosia for real objects seen from noncanonical views. These clinical symptoms corresponded directly to the autopsy finding of a recent large occipitotemporal ischaemic infarct in the territory of the right posterior cerebral artery. An additional right frontal infarct and a cortical microinfarct in a deep left lateral parieto-occipital sulcus were both old lesions and had passed unnoticed clinically. This first report of a direct clinicopathological correlation between a fresh right posterior lesion and prosopagnosia demonstrates that bilateral involvement of the visual system is not a prerequisite for prosopagnosia.

INTRODUCTION

Bodamer (1947), following the suggestion by Hoff and Pötzl (1937), considered the inability to recognize familiar faces as a specific agnosia which he named prosop-agnosia. However, impaired recognition of familiar faces had been noted long before in patients with disturbed visual recognition from cerebral lesions.

Wigan (1844), Quaglino (1867), Jackson (1876), Charcot (1883) and Wilbrand (1887, 1892) were among the first to describe this symptom. Its anatomical correlates, however, have become a matter for discussion. While Bodamer believed that for prosopagnosia to occur the lesions must be bilateral, Hécaen *et al.* (1957) emphasized the crucial role of the posterior right hemisphere lesion. Subsequent reviews (Gloning *et al.*, 1966; Meadows, 1974a; Benton, 1979; Damasio *et al.*, 1982) focused on the few pathology reports available (Wilbrand, 1892; Heidenhain, 1927; Arseni and Botez, 1958; Hécaen and Angelergues, 1962; Pevzner *et al.*, 1962; Gloning *et al.*, 1970; Lhermitte *et al.*, 1972; Benson *et al.*, 1974; Cohn *et al.*, 1977;

Correspondence to: Dr T. Landis, Neurologische Universitätsklinik, CH-8091 Zürich, Switzerland.

Nardelli *et al.*, 1982). These cases all showed a right medial occipitotemporal lesion and in all but 2 cases (Hécaen and Angelergues, 1962; Pevzner *et al.*, 1962) the corresponding area of the left hemisphere was also damaged. It is held therefore (Damasio *et al.*, 1982) that functionally symmetric damage to the medial occipitotemporal region is generally necessary for prosopagnosia to occur and that exceptions to this rule must be rare (Damasio *et al.*, 1986). There is, however, an increasing number of reports of patients with prosopagnosia who have clinical as well as radiological evidence only of right posterior cerebral damage (Hécaen *et al.*, 1956; Assal, 1969; Meadows, 1974a; Lhermitte and Pillon, 1975; Whiteley and Warrington, 1977; Torii and Tamai, 1985; De Renzi, 1986; Landis *et al.*, 1986b; Michel *et al.*, 1986). Moreover, for most of the cases with prosopagnosia who came to pathology there was a long delay between the onset of the symptom and death. Because of the possibility that the lesion on one side may have occurred after the onset of prosopagnosia such autopsy findings are of only limited value for clinicopathological comparison and a close temporal correlation seems necessary for the definitive association of symptom and lesion.

Comparing 22 patients with retrorolandic lesions *with* prosopagnosia to 393 patients with retrorolandic lesions but *without* prosopagnosia, Hécaen and Angelergues (1962) found aphasic defects and alexia less frequently in prosopagnosic patients than in those without prosopagnosia. While alexia and aphasia are seen with left posterior lesions, prosopagnosia occurs most often with topographagnosia, dressing apraxia, unilateral spatial agnosia or neglect and poor nonverbal learning, all of which are associated with right posterior lesions (Hécaen *et al.*, 1956; Tzavaras *et al.*, 1970; Meadows, 1974b; Landis *et al.*, 1986a). This finding emphasizes the importance of right posterior lesions for the manifestation of prosopagnosia. Patients with right posterior lesions may also have difficulty recognizing objects photographed from an unconventional angle, but recognize pictures of objects presented in a canonical view (Warrington and Taylor, 1973, 1978; Riddoch and Humphreys, 1986; Warrington and James, 1986).

We report a patient with an acute onset of prosopagnosia, topographagnosia and an agnosia for real objects shown in a noncanonical perspective, in whom the short survival period of only 10 days after a right posterior vascular lesion allowed a reliable clinicopathological correlation.

CASE REPORT

A 75-yr-old right-handed woman was admitted for evaluation of a left homonymous hemianopia. Apart from mild hypertension which had been treated for the last 10 years with diuretics, she had always been well. Two days before admission, while working in her vineyard, she had had two brief episodes of excessive sweating, nausea and tachycardia. Subsequently she had had difficulty in finding the way back to her farmhouse. She could no longer recognize relatives visually but identified them easily by their voices. This caused her no concern but she complained that she frequently collided with obstacles to her left. On admission she had a complete left homonymous hemianopia, and slowed optokinetic nystagmus to the left. Visual acuity was 0.8 in the right eye, 0.6 in the left;

ocular movements were full. The remaining cranial nerves were intact. Primary and cortical sensory modalities were intact and there was no extinction on double simultaneous tactile stimulation. Gait, motor strength and coordination were normal. On mental status examination she was alert, orientated, interested and cooperative, but she showed little concern about her illness. Although she occasionally cried and scored 10 points on the Hamilton Depression Scale she did not appear generally depressed. She denied visual hallucinations. Throughout the examination she was hemianopic and neglected the left half of her visual space. She could no longer recognize relatives or other familiar persons when she saw their faces, but immediately identified them when they spoke. She could learn to recognize the hospital staff only by voice, not by face. She was usually unable to recognize photographed faces of famous people; occasionally, however, she demonstrated a strange 'paradoxical knowledge' (e.g., confronted with a photograph of J. F. Kennedy she said 'this man could be a relative of Kennedy', or to the Mona Lisa 'this cannot possibly be Mona Lisa'). Neither in real life situations nor on photographs did she have difficulty in identifying a face as a face and she never saw faces as distorted. However, she was incapable of putting a face together from its single features (fig. 1), although she correctly named the parts and knew they should make




FIG. 1. *Right*, correct solution of a face puzzle. *Left*, the patient's attempt despite correct recognition of the single parts.

a face. She was also accurate in labelling emotional facial expressions on people and photographs. Thus she labelled an angry face 'a person who is not in the mood to talk', and imitated the appropriate expression. In a facial sorting test (Regard and Landis, 1986) she identified only 'friendly/unfriendly' out of five possible concepts (emotion, gender, headgear, age, fame). Control subjects found more than three concepts according to which they can sort these faces. Along with her prosopagnosia, she also suffered from severe topographagnosia. To find the way back to her room on the ward, the door had to be marked; she would usually deposit a personal object on the right side of the door. To find her bed she placed her pillow in the vertical position; if the position of the pillow was changed in her absence, she did not find her bed. She also confused her glasses with those of the examiner and insisted on exchanging them.

When shown objects or pictures she always took considerable time for visual inspection and, as an initial response, usually denied knowing what they represented. However, she correctly named most of the objects presented in a canonical view, that is in a prototypical representation (fig. 2). When shown real objects and small-scale models she was unable to identify the noncanonically presented items (Palmer *et al.*, 1981) but identified them correctly when the same objects were presented in a canonical view. When shown, for example, a folded pair of glasses (fig. 2, upper) she said 'something made of glass'; shown the same glasses in a more canonical perspective (fig. 2,

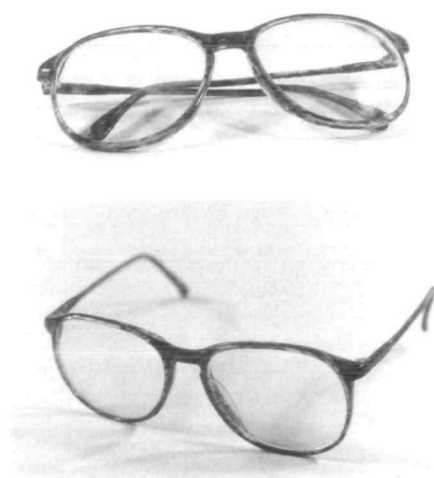


FIG. 2. *Upper*, noncanonical presentation of glasses.
Lower, canonical presentation of the same glasses.

lower) she recognized them. When presented with a toy trumpet from the front or from the top she said 'something made of metal'; when it was shown in a more canonical view from the side she identified it as a trumpet.

Although she could not identify an object presented noncanonically, she almost always identified the material out of which it was made and sometimes misidentified it as an object of the same material, such as a key lying flat in the examiner's hand as tweezers. Similar problems occurred with photographed objects taken from noncanonical angles, such as those presented by Warrington and Taylor (1973). When presented, for example, with the picture of a bucket seen from above, she described it as something which is empty inside and has the shape of a cylinder, but identified it as a bucket only when seen from the side. She immediately identified all objects by touch. As with the pictures of famous faces, she occasionally identified the object in a paradoxical way. When, for example, shown a pen she commented 'this is clearly not a pen', or for an eggbox she said 'a box made out of cardboard, but not one to put eggs in'. She was unable to identify Swiss currency unless she touched the coins. Clock reading was impossible and she wore her wrist watch upside down. From letters made up of small other letters she only identified the small letters; however, in pictures of overlapping drawings of highly stylized objects (Poppelreuter, 1917) she outlined and named all objects correctly. Another striking defect was her inability to recognize 'negative shape'. When shown a newspaper advertisement, where the picture of a car had been cut out, and asked to guess the missing part, she concentrated on the written legend, read and understood the text correctly, but was unable to recognize the missing shape as a car. The same happened, for example, with the advertisements for a hiking boot and bottle. Again she was unable to recognize the cut-out shape, despite verbal cues gathered from reading the accompanying text, but recognition improved when she followed the contours with her finger or when given the positive shape. She guessed 'foot' or 'hand' for the boot, and the negative shape of the bottle she named 'container made of glass, to drink out of it'. When the examiner enquired whether she meant a bottle, she denied it. However, when shown 12 assorted halves of 6 highly stylized canonical views she assembled and named them correctly. Colour perception was normal; she named and matched colours correctly and had no problems with the Farnsworth 16 hues test. She matched letters and words written in various typefaces with ease, had no alexia, and she understood words spelled out loud to her. However, she was unable to read mirror writing. Her spontaneous speech, repetition, auditory comprehension and prosody were intact. Naming of definitions, tactile naming and naming of

environmental sounds were normal. Writing was normal except for a left hemispatial neglect. Verbal memory was good: out of 10 words she learned 9 in 3 trials and recalled 8. She had a severe constructional apraxia. She was unable to copy or to draw a cube, a bicycle, a clock or a geometric figure with either hand. She had no buccolinguofacial, ideomotor or ideational apraxia.

The patient died of a pulmonary embolus 10 days after the onset of symptoms.

Postmortem findings

Massive recent pulmonary embolism was identified as the cause of death. There was an extensive subacute myocardial infarct in the region of the interventricular septum. The foramen ovale was patent. Both cardiac ventricles were dilated and the coronary arteries showed a nonstenosing

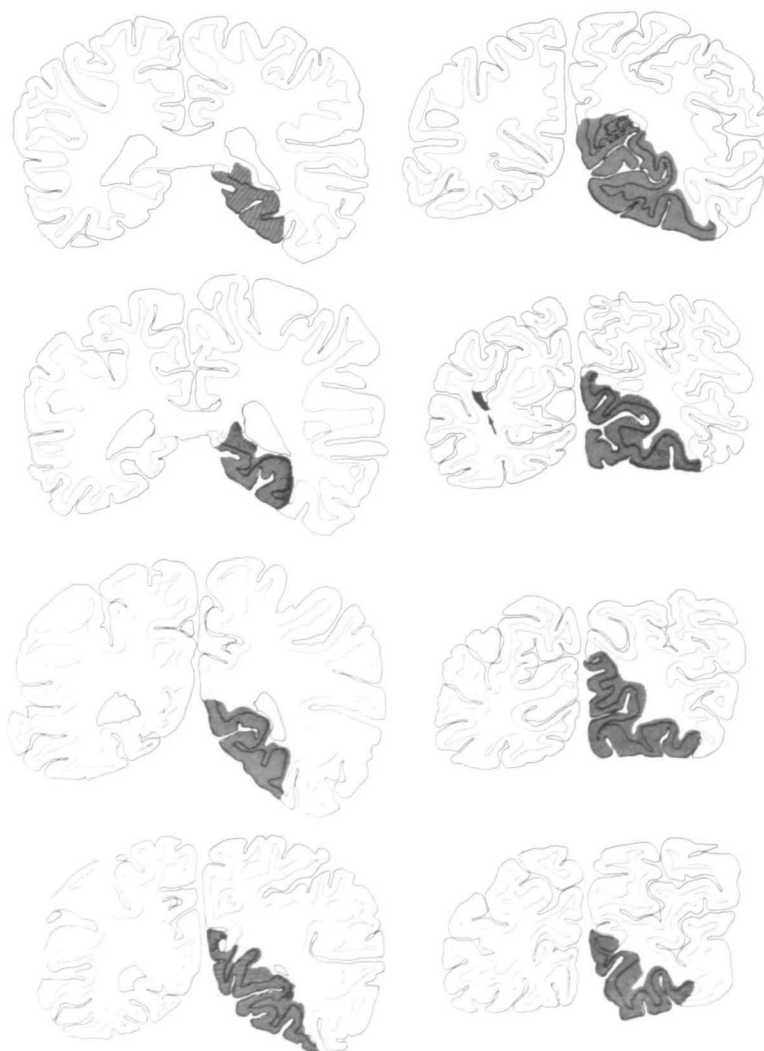


FIG. 3. Serial drawings of the parietal and occipital lobes. The hatched areas correspond to the recent infarct in the territory of the right posterior cerebral artery. The arrow indicates an old microinfarct in the left parieto-occipital region ($\times 0.8$).

atherosclerosis. The brain weighed 1,231 g. It was fixed in 4% formaldehyde and cut in 4–5 mm thick coronal sections. Following paraffin embedding, whole brain sections (7 μ m) were prepared using a Jung Tetrander microtome. Sections were stained with haematoxylin and eosin and luxol-Nissl. Morphological analysis revealed a large recent infarct in the territory of the right posterior cerebral artery (fig. 3), extending from the level of the splenium of the corpus callosum to the occipital pole. The rostral portion of the infarct involved the parahippocampal gyrus. The infarct largely corresponded to the anatomical distribution of the right posterior cerebral artery. There was no evidence of collateral blood supply via meningeal anastomoses from the anterior or middle cerebral artery. The entire visual cortex (areas 17 and 18) was therefore included in the infarction. Histologically, there were typical features of a recent infarction with eosinophilic neurons, loss of Nissl staining and a spongy demarcation from adjacent brain structures. The border zone showed marked vascular proliferation and macrophages as early indicators of resorption of the necrotic tissue. These changes were compatible with the clinical observation of a stroke 10 days before the patient's death.

In addition to this large recent infarct there were two circumscribed old vascular lesions. A U-shaped infarct was located in the right inferior frontal gyrus at the level of the anterior commissure (fig. 4). Histology revealed an old lesion with almost complete resorption of the necrotic tissue. A cortical microinfarct (diameter approximately 2 \times 5 mm) was present in a deep lateral parieto-occipital sulcus of the left cerebral hemisphere (fig. 3, arrow). This lesion, too, was old, appearing as a small glial scar.

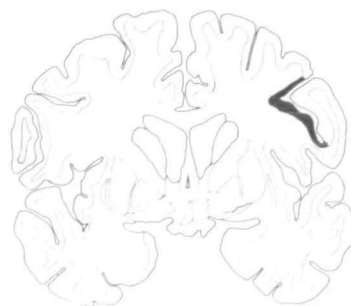


FIG. 4. Coronal section through the cerebral hemisphere at the level of the anterior commissure. The old infarct in the right inferior frontal gyrus is marked black.

DISCUSSION

The patient described had an acute onset of prosopagnosia, topographagnosia, agnosia for objects presented noncanonically and paradoxical visual knowledge. Autopsy 10 days after the event revealed a recent large ischaemic infarct in the territory of the right posterior cerebral artery. The short time lapse between the onset of these symptoms and autopsy and the absence of other recent lesions in this case make the correlation between the right posterior lesion and the symptomatology highly probable. In the previous cases of prosopagnosia which came to autopsy a causal connection could not be established directly because of a long delay between onset of symptoms and autopsy. This is perhaps best illustrated by the second patient described by Cohn *et al.* (1977). They state 'following the first episode, there were several other insults that left him blind' (p. 180). Clearly, the bilateral posterior lesions which were present at the time of

autopsy in this case cannot be taken as proof that functionally symmetric medial occipitotemporal lesions in the visual system are necessary for prosopagnosia to occur.

In addition to the *recent* large right posterior symptomatic infarct, we found in our case two additional *old* lesions, which were apparently clinically silent. One was a cortical microinfarct in the left lateral parieto-occipital area, the other a right frontal infarct. The left hemisphere microinfarct was much smaller than, but in a similar location to the lesion in the case described by Pevzner *et al.* (1962). Their patient showed at autopsy (4 years after the event), in addition to the typical right posteromedial infarct, a clinically silent left hemisphere posterolateral lesion in the middle of the inferior parietal lobule, angular gyrus, and upper part of the superior temporal sulcus. In their case the lesion was described as slight atrophy, gliosis and rarefaction of cells. Whether this left posterolateral pathology, however small and clinically silent, is a necessary prerequisite for prosopagnosia to occur or is just an incidental finding must remain open. It is, however, certain that in these 2 cases the lesions, though bilateral, are not symmetric. Benson *et al.* (1974) and Meadows (1974a), from their analysis of the few available pathology reports, emphasized the role of the right inferior longitudinal fasciculus, and Benson *et al.* (1974) envisaged a combination of a lesion of this structure with a lesion of the splenium of the corpus callosum as the possible neuroanatomical basis of prosopagnosia. As our case demonstrates, a single large lesion in the territory of the right posterior cerebral artery can damage both of these crucial fibre tracts. This view is supported by the increasing number of clinical reports of prosopagnosia subsequent to right posterior cerebral lesions without clinical or radiological evidence for additional left posterior damage (Whiteley and Warrington, 1977; Christen *et al.*, 1985; Torii and Tamai, 1985; De Renzi, 1986; Landis *et al.*, 1986b; Michel *et al.*, 1986).

The detailed pathological analysis of the posterior brain in our case shows virtually complete destruction of the *right* striate and peristriate cortex. The entire remaining visual recognition, therefore, was carried out by the primary and associative visual areas of the *left* hemisphere. Our patient was able to read and to recognize objects as long as they were presented from prototypical views. She was not, however, able to recognize faces (prosopagnosia), or places (topographagnosia) well known to her, nor was she able to recognize objects presented noncanonically. The isolated left hemisphere visual areas were thus not able to analyse the entire visual world. They appeared capable of visual categorization (e.g., to recognize a face as a face) but were unable to detect individuality (e.g., whose face) within a category. Moreover, they were only capable of categorizing objects within the narrow range of a canonical representation. Both phenomena, namely, impaired recognition of identity within a category (Lhermitte *et al.*, 1972; Whiteley and Warrington, 1977; Damasio *et al.*, 1982), and impaired identification and matching of common objects photographed from noncanonical views (Warrington and Taylor, 1973, 1978; Warrington and James, 1986) have previously

been associated with right posterior lesions. Our case not only confirms these findings, but also demonstrates that when there is complete destruction of the primary and associative visual system of the right hemisphere, the isolated visual structures of the left hemisphere are unable to provide this analysis. However, the present patient on several occasions explicitly denied knowing the correct item. This phenomenon, which we termed 'paradoxical knowledge', indicates that in some instances the left hemisphere visual system was even capable of analysing perceptually and categorizing faces of well-known people, but not with sufficient subjective certainty. We conjecture that the processing of faces or unusual objects by the left hemisphere visual structures, that is, those 'nondominant' for this analysis, lacks some specific features which estrange the percept from the inner model sufficiently to provoke active denial. The visual gnostic abilities of this patient are virtually the reverse of those seen in cases of major damage to the posterior *left* hemisphere. Since Lissauer's (1890) description of a patient with associative visual agnosia who subsequently came to pathology (Hahn, 1895), we know that a large lesion in the territory of the *left* posterior cerebral artery can render a patient unable to recognize visually-presented objects despite a visual capacity sufficient to copy objects. The intact visual system of the right hemisphere in these patients is apparently not capable on its own of providing object recognition. However, recognition of well-known faces, emotional facial expressions, familiar places and spatial orientation was relatively spared in most of the patients with visual associative agnosia due to isolated left posterior damage (Scheller, 1966; Lhermitte *et al.*, 1973; Hécaen *et al.*, 1974; Pillon *et al.*, 1981; Ferro and Santos, 1984; Larrabee *et al.*, 1985).

De Renzi *et al.* (1969) and Warrington and Taylor (1973, 1978), who compared the performance of patients with left or right hemisphere lesions on a variety of visual tasks, suggested 'apperception' (i.e., the identification and discrimination of complex pattern) (De Renzi *et al.*, 1969) or 'perceptual categorization' (Warrington and Taylor, 1978) to be impaired with right hemisphere damage; and 'association' or 'semantic categorization' to be deficient in patients with left hemisphere lesions.

Our patient had prosopagnosia, topographagnosia and an agnosia for non-canonical views, but could read and recognize prototypical objects easily. On the other hand, patients with similarly large lesions in the territory of the opposite (left) posterior cerebral artery have been reported to suffer from associative visual object agnosia and cannot read, but usually recognize well-known faces and places.

This pattern of double dissociation of function which emerges when comparing patients with large posterior lesions that isolate the visual areas of the opposite hemispheres, suggests that homologous areas of the visual systems of the right and the left hemispheres are specialized differently in the analysis of visual information.

ACKNOWLEDGEMENTS

We thank Ms B. Walker for her assistance and Drs Jane Casey, Roger Graves and Joe Bogen for their suggestions and editorial help. This study was supported by the Swiss National Science Foundation grant 3.884.0.83. Part of this study was presented to the 15th Annual International Neuropsychology Society meeting held in Washington, DC, in February, 1987.

REFERENCES

- ARSENI C, BOTEZ MI (1958) Consideraciones sobre un caso de agnosia de las fisonomias. *Revista Neuro-Psiquiatria, Lima*, **21**, 583-593.
- ASSAL G (1969) Régression des troubles de la reconnaissance des physionomies et de la mémoire topographique chez un malade opéré d'un hématome intracérébral pariéto-temporal droit. *Revue Neurologique*, **121**, 184-185.
- BENSON DF, SEGARRA J, ALBERT ML (1974) Visual agnosia-prosopagnosia: a clinicopathologic correlation. *Archives of Neurology, Chicago*, **30**, 307-310.
- BENTON A (1979) Visuo-perceptive, visuo-spatial, and visuo-constructive disorders. In: *Clinical Neuropsychology*. Edited by K. M. Heilman and E. Valenstein. New York and Oxford: Oxford University Press, pp. 186-232.
- BODAMER J (1947) Die Prosop-Agnosie (die Agnosie des Physiognomieerkennens). *Archiv für Psychiatrie und Nervenkrankheiten*, **179**, 6-53.
- CHARCOT JM (1883) Un cas de suppression brusque et isolée de la vision mentale des signes et des objets (formes et couleurs). *Progrès Médical*, **11**, 568-571.
- CHRISTEN L, LANDIS T, REGARD M (1985) Left hemispheric functional compensation in prosopagnosia? A tachistoscopic study with unilaterally lesioned patients. *Human Neurobiology*, **4**, 9-14.
- COHN R, NEUMANN MA, WOOD DH (1977) Prosopagnosia: a clinicopathological study. *Annals of Neurology*, **1**, 177-182.
- DAMASIO AR, DAMASIO H, VAN HOESEN GW (1982) Prosopagnosia: anatomic basis and behavioral mechanisms. *Neurology, New York*, **32**, 331-341.
- DAMASIO AR, DAMASIO H, TRANEL D (1986) Prosopagnosia: anatomic and physiologic aspects. In: *Aspects of Face Processing*. Edited by H. D. Ellis, M. A. Jeeves, F. Newcombe and A. Young. Dordrecht and Lancaster: Martinus Nijhoff, pp. 268-272.
- DE RENZI E (1986) Prosopagnosia in two patients with CT evidence of damage confined to the right hemisphere. *Neuropsychologia*, **24**, 385-389.
- DE RENZI E, SCOTTI G, SPINNLER H (1969) Perceptual and associative disorders of visual recognition: relationship to the side of cerebral lesion. *Neurology, Minneapolis*, **19**, 634-642.
- FERRO JM, SANTOS ME (1984) Associative visual agnosia: a case study. *Cortex*, **20**, 121-134.
- GLONING I, GLONING K, HOFF H, TSCHABITSCHER H (1966) Zur Prosopagnosie. *Neuropsychologia*, **4**, 113-132.
- GLONING I, GLONING K, JELLINGER K, QUATEMBER R (1970) A case of 'prosopagnosia' with necropsy findings. *Neuropsychologia*, **8**, 199-204.
- HAHN E (1895) Pathologisch-anatomische Untersuchung des Lissauer'schen Falles von Seelenblindheit. *Arbeiten aus der Psychiatrischen Klinik in Breslau*, No. 2, 105-119.
- HÉCAEN H, PENFIELD W, BERTRAND C, MALMO R (1956) The syndrome of apractognosia due to lesions of the minor cerebral hemisphere. *Archives of Neurology and Psychiatry, Chicago*, **75**, 400-434.
- HÉCAEN H, ANGELERGUES R, BERNHARDT C, CHIARELLI J (1957) Essai de distinction des modalités cliniques de l'agnosie des physionomies. *Revue Neurologique*, **96**, 125-144.
- HÉCAEN H, ANGELERGUES R (1962) Agnosia for faces (prosopagnosia). *Archives of Neurology, Chicago*, **7**, 92-100.

- HÉCAEN H, GOLDBLUM MC, MASURE MC, RAMIER AM (1974) Une nouvelle observation d'agnosie d'object. Deficit de l'association ou de la categorisation, spécifique de la modalité visuelle? *Neuropsychologia*, **12**, 447-464.
- HEIDENHAIN A (1927) Beitrag zur Kenntnis der Seelenblindheit. *Monatsschrift für Psychiatrie und Neurologie*, **66**, 61-116.
- HOFF H, PÖTZL O (1937) Über eine optisch-agnostische Störung des 'Physiognomie-Gedächtnisses' (Beziehungen zur Rückbildung einer Wortblindheit). *Zeitschrift für die Gesamte Neurologie und Psychiatrie*, **159**, 367-395.
- JACKSON JH (1876) Case of large cerebral tumour without optic neuritis, and with left hemiplegia and imperception. *Royal London Ophthalmic Hospital Reports*, **8**, 434-444.
- LANDIS T, CUMMINGS JL, BENSON DF, PALMER EP (1986a) Loss of topographic familiarity: an environmental agnosia. *Archives of Neurology, Chicago*, **43**, 132-136.
- LANDIS T, CUMMINGS JL, CHRISTEN L, BOGEN JE, IMHOF H-G (1986b) Are unilateral right posterior cerebral lesions sufficient to cause prosopagnosia? Clinical and radiological findings in six additional patients. *Cortex*, **22**, 243-252.
- LARRABEE GJ, LEVIN HS, HUFF FJ, KAY MC, GUINTO FC (1985) Visual agnosia contrasted with visual-verbal disconnection. *Neuropsychologia*, **23**, 1-12.
- LHERMITTE F, CHAIN F, ESCOUROLLE R, DUCARNE B, PILLON B (1972) Étude anatomo-clinique d'un cas de prosopagnosie. *Revue Neurologique*, **126**, 329-346.
- LHERMITTE F, CHEDRU F, CHAIN F (1973) A propos d'un cas d'agnosie visuelle. *Revue Neurologique*, **128**, 301-322.
- LHERMITTE F, PILLON B (1975) La prosopagnosie: rôle de l'hémisphère droit dans la perception visuelle (a propos d'un cas consécutif à une lobectomie occipitale droite). *Revue Neurologique*, **131**, 791-812.
- LISSAUER H (1890) Ein Fall von Seelenblindheit nebst einem Beitrage zur Theorie derselben. *Archiv für Psychiatrie und Nervenkrankheiten*, **21**, 222-270.
- MEADOWS JC (1974a) The anatomical basis of prosopagnosia. *Journal of Neurology, Neurosurgery and Psychiatry*, **37**, 489-501.
- MEADOWS JC (1974b) Disturbed perception of colours associated with localized cerebral lesions. *Brain*, **97**, 615-632.
- MICHEL F, PERENIN MT, SIEROFF E (1986) Prosopagnosie sans hémianopsie après lésion unilatérale occipito-temporale droite. *Revue Neurologique*, **142**, 545-549.
- NARDELLI E, BUONANNO F, COCCIA G, FIASCHI A, TERZIAN H, RIZZUTO N (1982) Prosopagnosia: report of four cases. *European Neurology*, **21**, 289-297.
- PALMER S, ROSCH E, CHASE P (1981) Canonical perspective and the perception of objects. In: *Attention and Performance 9*. Edited by J. Long and A. Baddeley. Hillsdale, NJ: Lawrence Erlbaum, pp. 135-151.
- PEVZNER S, BORNSTEIN B, LOEWENTHAL M (1962) Prosopagnosia. *Journal of Neurology, Neurosurgery and Psychiatry*, **25**, 336-338.
- PILLON B, SIGNORET J-L, LHERMITTE F (1981) Agnosie visuelle associative. Rôle de l'hémisphère gauche dans la perception visuelle. *Revue Neurologique*, **137**, 831-842.
- POPPELREUTER W (1917) *Die Psychischen Schädigungen durch Kopfschuss im Kriege 1914/16*, Volume 1. Leipzig: Leopold Voss.
- QUAGLINO A (1867) Emiplegia sinistra con amaurosi-Guarigione-Perdita totale della percezione dei colori e della memoria della configurazione degli oggetti. *Giornale d'Oftalmologia Italiano*, **10**, 106-117.
- REGARD M, LANDIS T (1986) Affective and cognitive decisions on faces in normals. In: *Aspects of Face Processing*. Edited by H. D. Ellis, M. A. Jeeves, F. Newcombe and A. Young. Dordrecht and Lancaster: Martinus Nijhoff, pp. 363-369.
- RIDDOCH MJ, HUMPHREYS GW (1986) Neurological impairments of object constancy: the effects of orientation and size disparities. *Cognitive Neuropsychology*, **3**, 207-224.

- SCHELLER H (1966) Benennen und Erkennen. Klinischer und anatomischer Bericht über einen Fall von optischer Aphasie, Alexie und optischer Agnosie. *Nervenarzt*, **37**, 93-96.
- TORII H, TAMAI A (1985) The problem of prosopagnosia: report of three cases with occlusion of the right posterior cerebral artery. *Journal of Neurology*, **232**, Supplement, 140.
- TZAVARAS A, HÉCAEN H, LE BRAS H (1970) Le problème de la spécificité du déficit de la reconnaissance du visage humain lors des lésions hémisphériques unilatérales. *Neuropsychologia*, **8**, 403-416.
- WARRINGTON EK, TAYLOR AM (1973) The contribution of the right parietal lobe to object recognition. *Cortex*, **9**, 152-164.
- WARRINGTON EK, TAYLOR AM (1978) Two categorical stages of object recognition. *Perception*, **7**, 695-705.
- WARRINGTON EK, JAMES M (1986) Visual object recognition in patients with right-hemisphere lesions: axes or features? *Perception*, **15**, 355-366.
- WHITELEY AM, WARRINGTON EK (1977) Prosopagnosia: a clinical, psychological, and anatomical study of three patients. *Journal of Neurology, Neurosurgery and Psychiatry*, **40**, 395-403.
- WIGAN AL (1844) *A New View of Insanity: The Duality of the Mind Proved by the Structure, Functions, and Diseases of the Brain, and by the Phenomena of Mental Derangement and Shown to Be Essential to Moral Responsibility*. London: Longman, Brown, Green and Longmans. Reprinted (1985): Malibu, CA: J. Simon.
- WILBRAND H (1887) *Die Seelenblindheit als Herderscheinung*. Wiesbaden: J. F. Bergmann.
- WILBRAND H (1892) Ein Fall von Seelenblindheit und Hemianopsie mit Sectionsbefund. *Deutsche Zeitschrift für Nervenheilkunde*, **2**, 361-387.

(Received July 31, 1987. Revised December 22, 1987. Accepted January 13, 1988)