



# Hypertrophic Olivary Degeneration and Holmes Tremor: Case Report and Review of the Literature

**Sebahat Nacar Dogan**

## Key words

- Guillain-Mollaret triangle
- Holmes tremor
- Hypertrophic olivary degeneration
- Midbrain hemorrhage
- Pontine hemorrhage

## Abbreviations and Acronyms

- GMT:** Guillain-Mollaret triangle  
**HOD:** Hypertrophic olivary degeneration  
**HT:** Holmes tremor  
**ION:** Inferior olivary nucleus

Department of Radiology, University of Health Sciences Turkey, Gaziosmanpasa Training and Research Hospital, Istanbul, Turkey

To whom correspondence should be addressed:  
 Sebahat Nacar Dogan, M.D.  
 [E-mail: [sebahatdogan@yahoo.com](mailto:sebahatdogan@yahoo.com)]

Citation: *World Neurosurg.* (2020) 137:286-290.  
<https://doi.org/10.1016/j.wneu.2020.02.068>

Journal homepage: [www.journals.elsevier.com/world-neurosurgery](http://www.journals.elsevier.com/world-neurosurgery)

Available online: [www.sciencedirect.com](http://www.sciencedirect.com)

1878-8750/\$ - see front matter © 2020 Elsevier Inc. All rights reserved.

## INTRODUCTION

Hypertrophic olivary degeneration (HOD) is a very rare transsynaptic degeneration that results from disruption of the Guillain-Mollaret triangle (GMT) and affects the inferior olivary nucleus (ION). GMT is disturbed generally by hemorrhage due to hypertension, trauma, posterior fossa surgery, or vascular malformation, such as cavernoma, but rarely by ischemia, demyelinating/degenerative diseases, or tumor.<sup>1,2</sup> In addition, abscess, metronidazole intoxication, gluten sensitivity, and multifocal leukoencephalopathy have been reported as etiologies.<sup>3-6</sup> Classic presentation of HOD is palatal myoclonus. Although Holmes tremor (HT) is correlated with HOD, presentation of HOD with HT is very rare. HT is characterized by rest tremor that is induced by posture and intention and disappears during sleep.<sup>7</sup> It generally appears in one upper extremity.<sup>8</sup> HTs reported as a result of HOD are very limited.<sup>7,9-19</sup> As in this

■ **BACKGROUND:** Hypertrophic olivary degeneration (HOD) is very rare type of degeneration that causes hypertrophy rather than atrophy. The classical presentation of HOD is palatal myoclonus. However, HOD may rarely present with Holmes tremor (HT). HT is unusual symptomatic tremor characterized by combination of rest and intention tremor. It has been reported in small case series, so far.

■ **CASE DESCRIPTION:** In this study, a man aged 62 years with HOD and HT spreading to the upper and lower extremities after pontine-midbrain hemorrhage due to cavernoma was presented.

■ **CONCLUSIONS:** Although pontine-midbrain hemorrhage may cause HT in the late period, HOD can be revealed on magnetic resonance imaging. Tract anatomy, especially the Guillain-Mollaret triangle, should be considered to explain the relationship between HT and HOD.

reported case, HT spreading to the lower extremity is very rare.<sup>13,16,18</sup>

In the present report, a man aged 62 years with HT after brainstem hemorrhage due to pontine cavernoma had HOD on magnetic resonance imaging. HT was spreading to the upper and lower extremities.

## CASE DESCRIPTION

A man aged 62 years presented to the emergency department with acute onset of weakness on the left upper and lower extremities and dysarthria. Nonenhanced computed tomography performed on admission depicted hemorrhage on the right side of the pons and mesencephalon, including the red nucleus. Hemorrhage extended to the fourth ventricle (Figure 1). Neurologic examination revealed left hemiplegia, left facial palsy, ptosis, and complete loss of motion of the left eye. Vision of the right eye was lost previously due to retinal detachment. He managed conservatively in the intensive care unit and was eventually transferred to a rehabilitation facility.

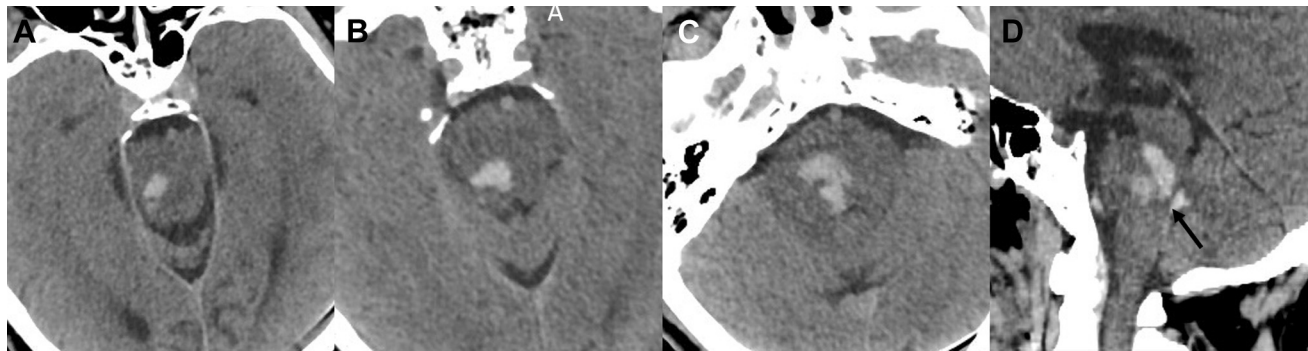
Nine months after insult, he had coarse, irregular, resting tremor of the left upper and lower extremities that was exacerbated by posture and activity. It was more

pronounced at the upper extremity. The tremor did not occur during sleep. Magnetic resonance imaging depicted prominent T2 and T2\* hypointensity related to hemosiderin and ferritin deposition along the pathway starting from the red nucleus to the middle cerebellar peduncle on the right side of the brainstem (Figure 2A and B). A cavernoma was also revealed on the right side of the pons (Figure 2C). Ipsilateral medulla oblongata corresponding to the ION was hypertrophic. It was hyperintense on T2-weighted and fluid-attenuated inversion recovery images, and isointense on T1-weighted image (Figure 2D-F). On contrast-enhanced T1-weighted images, there was no enhancement (Figure 2G). Diffusion restriction was not seen (Figure 2H).

Follow-up magnetic resonance imaging at 17 months after insult depicted that hypertrophy of HOD was regressed but hyperintensity was still observed on T2-weighted image (Figure 3).

## DISCUSSION

HT and HOD in a patient after brainstem hemorrhage was presented. Although HT is related to HOD, HOD rarely manifests as HT. HOD is caused by a lesion disturbing the GMT. However, HT results from a lesion



**Figure 1.** Nonenhanced computed tomography performed on admission revealed hemorrhage on right side of the pons and mesencephalon (A–C)

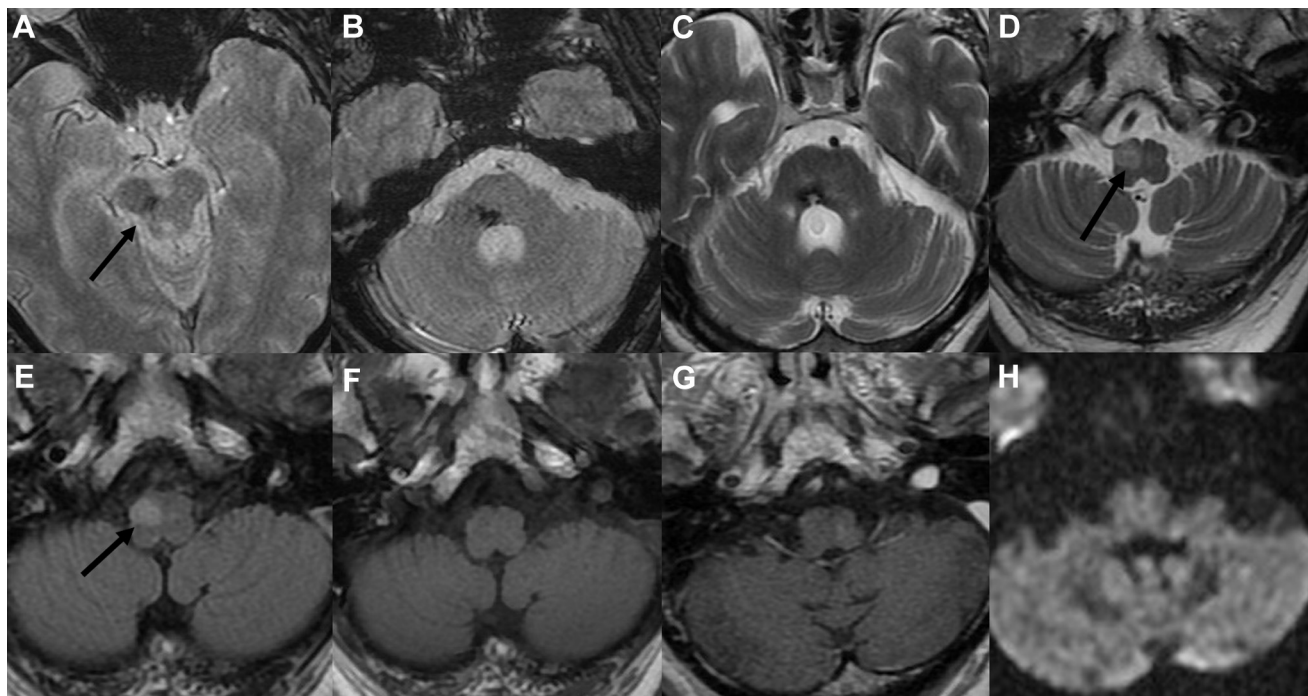
extending from red nucleus to middle cerebellar peduncle. Hemorrhage was revealed in the fourth ventricle (D).

covering both dopaminergic (nigrostriatal fibers) and cerebellothalamic/cerebello-olivary pathways.<sup>16</sup> In the presented case, brainstem hemorrhage due to pontine cavernoma had extended from the red nucleus to the middle cerebellar peduncle.

Consequently, nigrostriatal and GMT pathways were injured due to hemorrhage.

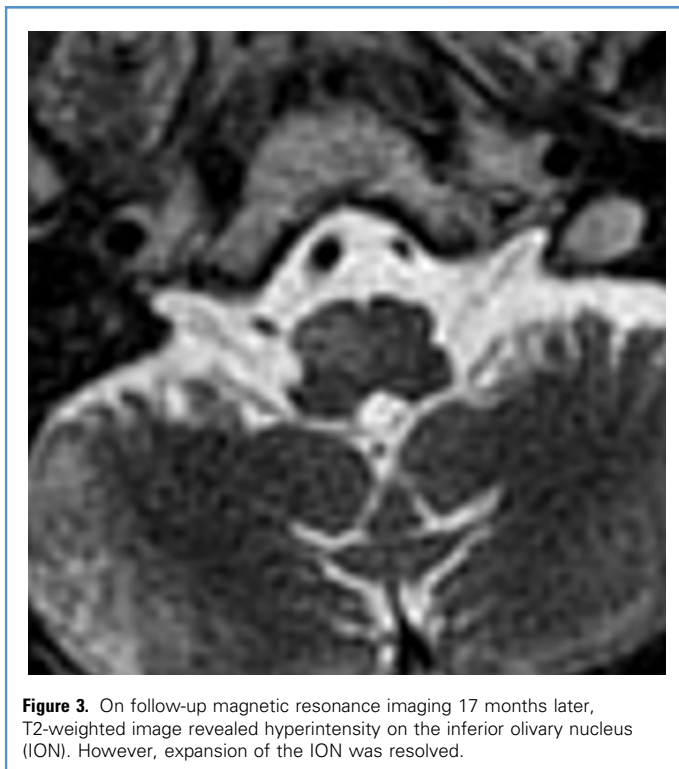
We performed a literature search using the PubMed database with the search terms “hypertrophic olivary degeneration,” “Holmes tremor” “pontine hemorrhage,”

“Guillain-Mollaret triangle” and “dentato-rubro-olivary tract” with the aim of reviewing related cases that have been reported thus far. Including the present report, a total of 16 cases were found according to PubMed research. Twelve



**Figure 2.** Magnetic resonance imaging performed 9 months later due to Holmes tremor. T2\* weighted images (A and B) depicted hypointensity related to hemosiderin and ferritin deposition on the right side of the brainstem extending from the substantia nigra-red nucleus of mesencephalon (arrow) to the middle cerebellar peduncle. Axial T2-weighted image (C) showed a cavernoma on the right side of the pons. Axial T2-weighted and fluid-attenuated inversion recovery images (D and E)

demonstrated hypertrophy and hyperintensity (arrows) on ipsilateral medulla oblongata corresponding to the inferior olivary nucleus. On T1-weighted images (F), hypertrophic olivary degeneration appeared isointense and mildly expansive. There was no enhancement on contrast-enhanced T1-weighted image (G). Diffusion restriction was not seen (H).



**Figure 3.** On follow-up magnetic resonance imaging 17 months later, T2-weighted image revealed hyperintensity on the inferior olivary nucleus (ION). However, expansion of the ION was resolved.

cases<sup>7,9,11-19</sup> had HT including upper extremity. Three cases<sup>13,16,18</sup> and the present case had HT that included both upper and lower extremities (Table 1).

GMT, known as the dentato-rubro-olivary tract, consists of the ipsilateral ION and the red nucleus, and the contralateral dentate nucleus. It is bidirectional pathway. This tract is the afferent pathway to the olive. The dentatorubral tract originating from the contralateral dentate nucleus of the cerebellum ascends to the superior cerebellar peduncle. Then it decussates at the level of the inferior colliculus (commissure of Wernekinck), and arrives at the contralateral red nucleus. The central tegmental tract originates from the red nucleus and reaches to the ipsilateral ION. Although this is a disynaptic pathway, there is also a parallel monosynaptic pathway that goes to the ION without entering the red nucleus. The efferent fibers of the olivocerebellar tract originated from the ION complete triangular circuit by passing through the inferior cerebellar peduncle. Then, they synapse with the contralateral cerebellar cortex.<sup>20,21</sup> Therefore the GMT connects the cerebellum with brainstem to control

spinal cord motor activity.<sup>8</sup> Degeneration of the monosynaptic tract is related to HOD. However, isolated injury of the inferior cerebellar peduncle does not result in HOD because there is no direct connection between the ION and the contralateral dentate nucleus.<sup>9,17</sup>

The uniqueness of HOD stems from hypertrophy of the ION as a consequence of degeneration rather than atrophy. Transsynaptic degeneration resulting from disruption of afferent fibers to the ION in the GMT by any insult is seen as neuronal cytoplasmic vacuolization, hypertrophy of astrocytes, gliosis and demyelination of olivary nucleus, and macroscopic hypertrophy on histopathologic examination.<sup>22</sup>

Goto et al.<sup>23</sup> have reported that the sequence of pathologic changes in HOD by postmortem studies was correlated with radiologic findings. These changes are classified into 6 stages: 1) no olivary changes within 24 hours; 2) degeneration of white matter capsule forming olivary amiculum at 2–7 days, or possibly more; 3) mild olivary hypertrophy (neuronal hypertrophy, no glial reaction) at approximately 3 weeks; 4) culminant olivary hypertrophy (hypertrophy of

both neurons and astrocytes); 5) pseudohypertrophy (neuronal dissolution with gemistocytic astrocytes) at approximately 9.5 months and later; and 6) olivary atrophy (neuronal disappearance) after a few years.<sup>23</sup>

Goyal et al.<sup>20</sup> have documented 3 distinct magnetic resonance stages in HOD. These 3 stages are attributed to the fact that radiologic changes are not seen at approximately 1 month after ictus. In the first stage of HOD, the ION has increased signal intensity on T2-weighted images without hypertrophy within the first 6 months of insult. The second stage depicts both hyperintensity and hypertrophy between 6 month and 3–4 years when hypertrophy resolves. In the third stage, hypertrophy regresses and only hyperintensity is seen. Hyperintensity persists indefinitely. Over time, the olives undergoes atrophy.

HOD is detected in 3 patterns according to the involvement of the GMT: ipsilateral, contralateral, and bilateral olivary hypertrophy. If the lesion disturbs the central tegmental tract, unilateral-ipsilateral HOD is seen. However, when the dentatorubral tract is injured, unilateral-contralateral HOD can develop.<sup>2</sup> When primary lesion involves both of the aforementioned tracts, or if a midline lesion is located in the commissure of Wernekinck at the superior cerebellar peduncle, bilateral HOD can occur.<sup>17,20,22,24</sup>

Classical presentation of HOD is palatal myoclonus. However, it is also presented as cerebellar ataxia, ocular symptoms (nystagmus, ophthalmoplegia, and ocular myoclonus), and other involuntary movement disorders. Although all patients with symptomatic palatal myoclonus have HOD, not all patients with HOD develop palatal myoclonus. Rarely, HT or ocular myoclonus are observed.

HT, also known as rubral tremor or midbrain tremor, is a rare symptomatic movement disorder caused by lesions in the brainstem, thalamus, or cerebellum. It is a low frequency (<4.5 Hz) resting tremor exacerbated by posture and is accentuated with intention.<sup>25</sup> It does not have a very regular rhythm differently from other tremors. It generally involves upper extremities. Because HOD has accompanied mostly to the patients with HT after brainstem stroke, interruption of the GMT might result in HT. Although

**Table 1.** Literature Review of Holmes Tremor and Hypertrophic Olivary Degeneration

Study	Sex	Age (years)	Underlying Pathology	Radiologic Finding	Tremor	Onset of HT (month)	Extremity that HT was Visualized
Shepherd et al., 1997 <sup>9</sup>	M	52	Brainstem hemorrhage	Bilateral HOD	HT	5	Upper extremity
Rieder et al., 2003 <sup>10</sup>	M	48	Brainstem hemorrhage	Bilateral HOD	HT Palatal tremor	5	Upper extremity
Arora et al., 2006 <sup>19</sup>	M	35	Brainstem hemorrhage	Unilateral HOD	HT	5	Upper extremity
Walker et al., 2007 <sup>13</sup>	M	43	Brainstem hemorrhage	Unilateral HOD	HT	5	Upper and lower extremities
Alstadhaug, 2007 <sup>12</sup>	M	54	Brainstem hemorrhage	Unilateral HOD	HT Oculopalatal tremor	NA	Upper extremity
Menéndez et al., 2014 <sup>16</sup>	M	27	Brainstem hemorrhage	Unilateral HOD	HT	7	Upper and lower extremities
Chhetri et al., 2014 <sup>15</sup>	M	51	Brainstem hemorrhage	Unilateral HOD	HT Palatal tremor	6	Upper extremity
Kim et al., 2014 <sup>7</sup>	F	58	Brainstem hemorrhage	Bilateral HOD	HT	7	Upper extremity
Lee et al., 2015 <sup>18</sup>	F	66	SAH+brainstem hemorrhage	Unilateral HOD	HT	3	All extremities
Cosentino et al., 2016 <sup>17</sup> Case 1	M	60	Brainstem hemorrhage	Bilateral HOD	HT	NA	Both upper extremities Head
Cosentino et al., 2016 <sup>17</sup> Case 2	F	69	Midbrain infarction	Bilateral HOD	HT	2*	Both upper extremities Head
Kipfer and Frigerio, 2013 <sup>14</sup>	F	63	Pontine infarction	Unilateral HOD	HT	6	Upper extremity
Yang et al., 2005 <sup>11</sup> Case 1	M	52	Midbrain infarction	Unilateral HOD	HT	6.5	Upper extremity
Yang et al., 2005 <sup>11</sup> Case 2	M	24	Head trauma	Unilateral HOD	HT	1	Upper extremity
Yang et al., 2005 <sup>11</sup> Case 3	M	50	Midbrain infarction	Bilateral HOD	HT	12	Both upper extremities
Present case	M	62	Brainstem hemorrhage	Unilateral HOD	HT	9	Upper and lower extremities

HT, Holmes tremor; M, male; F, female; SAH, subarachnoid hemorrhage; HOD, hypertrophic olivary degeneration; NA, not available.

\*Expressed in weeks.

degeneration of the disynaptic dentato-rubro-olivary tract is associated with tremor, degeneration of the monosynaptic tract is related to HOD.<sup>9,17</sup> Combined injury of the dopaminergic (nigrostriatal fibers) and cerebellothalamic/cerebello-olivary pathways are necessary for the development of HT.<sup>8,26,27</sup> Injury of the nigrostriatal pathways may cause tremor at rest.<sup>8</sup> HT can manifest approximately 4 weeks to 2 years after insult. The reason for the delayed onset is still unclear. However, there is a hypothesis suggesting that the new development of pathologic pathways after the recovery period takes time.<sup>8</sup> In the presented case, HT manifested 9 months later; however, onset of HT ranged between 2 weeks and 12 months in previous reported cases. Although HT could resolve spontaneously or regress

within 1 year after onset, it is constant in most of cases. HT was also constant in the presented case. Medical treatment is rarely successful, and in some cases surgery, such as thalamic stimulation, can be a chief part.<sup>28,29</sup>

Differential diagnosis of HOD based on T2 increased signal intensity in the anterior part of the medulla oblongata. It includes infarction, demyelination, tumor, and infection/inflammatory processes.<sup>1</sup> While diagnosing HOD, remote lesions should be kept in mind as a key point.

## CONCLUSIONS

Brainstem hemorrhage can result HOD and HT. The recognition of probable clinical-radiologic results of brainstem hemorrhage, especially around the

midbrain, could prevent inaccurate diagnosis and intervention. Especially, delayed onset of HT and delayed appearance of HOD should be remembered.

## REFERENCES

- Wein S, Yan B, Gaillard F. Hypertrophic olivary degeneration secondary to pontine haemorrhage. *J Clin Neurosci.* 2015;22:1213-1214.
- Konno T, Broderick DF, Tacic P, Caviness JN, Wszolek ZK. Hypertrophic olivary degeneration: a clinico-radiologic study. *Parkinsonism Relat Disord.* 2016;28:36-40.
- Chhetri SK, Dayanandan R, Bindman DC, Mathur S, Mills RJ. Symptomatic palatal tremor following multiple listerial brainstem abscesses. *Parkinsonism Relat Disord.* 2014;20:253-255.
- Seok JI, Yi H, Song YM, Lee WY. Metronidazole-induced encephalopathy and inferior olivary hypertrophy: lesion analysis with diffusion-weighted

- imaging and apparent diffusion coefficient maps. *Arch Neurol*. 2003;60:1796-1800.
5. Kheder A, Currie S, Romanowski C, Hadjivassiliou M. Progressive ataxia with palatal tremor due to gluten sensitivity. *Mov Disord*. 2012; 27:62-63.
  6. Mathew RM, Murmane M. MRI in PML: bilateral medullary lesions. *Neurology*. 2004;63:2380.
  7. Kim MK, Cho BM, Park SH, Yoon DY. Holmes' tremor associated with bilateral hypertrophic olivary degeneration following brain stem hemorrhage: a case report. *J Cerebrovasc Endovasc Neurosurg J Cerebrovasc Endovasc Neurosurg*. 2014;16:299-302.
  8. Choi S-M. Movement disorders following cerebrovascular lesions in cerebellar circuits. *J Mov Disord*. 2016;9:80-88.
  9. Shepherd GMG, Tauböll E, Bakke SJ, Nyberg-Hansen R. Midbrain tremor and hypertrophic olivary degeneration after pontine hemorrhage. *Mov Disord*. 1997;12:432-437.
  10. Rieder CRM, Rebouças RG, Ferreira MP. Holmes tremor in association with bilateral hypertrophic olivary degeneration and palatal tremor chronological considerations case report. *Arq Neuropsiquiatr*. 2003;61:473-477.
  11. Yang Y-W, Chang F-C, Tsai C-H, et al. Clinical and magnetic resonance imaging manifestations of Holmes tremor. *Acta Neurol Taiwan*. 2005;14:9-15.
  12. Alstadhaug KB. Oculopalatal and cerebellar limb tremor due to hypertrophic olivary degeneration. *Eur J Neurol*. 2007;14:e6-e7.
  13. Walker M, Kim H, Samii A. Holmes-like tremor of the lower extremity following brainstem hemorrhage. *Mov Disord*. 2007;22:272-274.
  14. Kipfer S, Frigerio SB. Post-ischemic stroke Holmes' tremor of the upper limb. *Mov Disord*. 2013;28:1347.
  15. Chhetri SK, Boothman B, Haq MA, Mathur S, Majeed T. Holmes' and palatal tremor following brainstem haemorrhage. *Parkinsonism Relat Disord*. 2014;20:673-675.
  16. Menéndez DF, Cury RG, Barbosa ER, Teixeira MJ, Fonoff ET. Hypertrophic olivary degeneration and Holmes' tremor secondary to bleeding of cavernous malformation in the midbrain. *Tremor Other Hyperkinet Mov (N Y)*. 2014;4:264.
  17. Cosentino C, Velez M, Nuñez Y, et al. Bilateral hypertrophic olivary degeneration and Holmes tremor without palatal tremor: an unusual association. *Tremor Other Hyperkinet Mov (N Y)*. 2016;6: 400.
  18. Lee S, Choi J, Son B. Rubral tremors associated with an inferior olivary lesion that developed after a brainstem hemorrhage. *The Nerve*. 2015;1:50-52.
  19. Arora V, Nijjar I, Sandhu P, Singh J, Abrol R, Roopa. Hypertrophic olivary degeneration following trauma—a case report. *Indian J Radiol Imaging*. 2006;16:701-704.
  20. Goyal M, Versnick E, Tuite P, et al. Hypertrophic olivary degeneration: metaanalysis of the temporal evolution of MR findings. *AJNR Am J Neuroradiol*. 2000;21:1073-1077.
  21. Lapresle J. [The dento-olivary pathway: demonstration, course and significance]. *Bull Acad Natl Med*. 1984;168:336-341.
  22. Kitajima M, Korogi Y, Shimomura O, et al. Hypertrophic olivary degeneration: MR imaging and pathologic findings. *Radiology*. 1994;192:539-543.
  23. Goto N, Kaneko M. Olivary enlargement: chronological and morphometric analyses. *Acta Neuropathol*. 1981;54:275-282.
  24. Uchino A, Hasuo K, Uchida K, et al. Olivary degeneration after cerebellar or brain stem haemorrhage: MRI. *Neuroradiology*. 1993;35:335-338.
  25. Deuschl G, Bain P, Brin M. Consensus statement of the Movement Disorder Society on Tremor. Ad Hoc Scientific Committee. *Mov Disord*. 1998; 13(suppl 3):2-23.
  26. Ash L, Srinivasan A. Case of the season: hypertrophic olivary degeneration. *Semin Roentgenol*. 2008;43:171-172.
  27. Ohye C, Shibasaki T, Hirai T, et al. A special role of the parvocellular red nucleus in lesion-induced spontaneous tremor in monkeys. *Behav Brain Res*. 1988;28:241-243.
  28. Kobayashi K, Katayama Y, Oshima H, et al. Multitarget, dual-electrode deep brain stimulation of the thalamus and subthalamic area for treatment of Holmes' tremor. *J Neurosurg*. 2014;120: 1025-1032.
  29. Vélez M, Cosentino C, Torres L. Levodopa-responsive rubral (Holmes') tremor. *Mov Disord*. 2002;17:741-742.

*Conflict of interest statement: The author declares that the article content was composed in the absence of any commercial or financial relationships that could be construed as a potential conflict of interest.*

*Received 28 January 2020; accepted 10 February 2020*

*Citation: World Neurosurg. (2020) 137:286-290.*

*<https://doi.org/10.1016/j.wneu.2020.02.068>*

*Journal homepage: [www.journals.elsevier.com/world-neurosurgery](http://www.journals.elsevier.com/world-neurosurgery)*

*Available online: [www.sciencedirect.com](http://www.sciencedirect.com)*

*1878-8750/\$ - see front matter © 2020 Elsevier Inc. All rights reserved.*