

Case reports

Spinal epidural hematoma without lesion of the

Report of 4 cases

L. Calliauw*, M. Dhara*, F. Martens*, and L. Vannerem* *

Introduction

Spinal fracture or dislocation can provoke a spinal epidural hematoma by extravasation from the bone. This type of case will not be discussed in this paper. On the contrary spinal epidural hematoma without a lesion of the spine occur relatively rarely. Foo and Rossier reviewed the world literature in 1981 and were able to collect 158 cases¹. The analysis of these cases enabled them to find a correlation between the presurgical neurological status and the postoperative outcome. Their correlation can be summarized as follows: Postoperative return of motor function was noted in 95.3%, 87% and 45.3% of the patients with incomplete sensorimotor, incomplete sensory but complete motor and complete sensorimotor lesion respectively. Complete sensorimotor recovery occurred in 41.9%, 26.1% and 11.3% of these 3 groups of patients, respectively. Since then other cases have been reported².

It is confirmed that pre-operative neurological status and delay of surgical treatment are the principle factors in determining the outcome. There is still doubt about the source of bleeding: whether the origin is arterial or venous, is a matter for debate.

In order to be able to participate in this discussion we present four cases of spinal epidural hematoma.

Summary

The authors report 4 cases of spinal epidural hematoma without a lesion of the spine. The medical literature relating to this subject is reviewed with special reference to the pathophysiology of the bleeding. There are arguments in favor of the venous origin as well the arterial origin of the bleeding.

As far as recovery following surgical treatment is concerned, the history of our cases confirms the opinion that the prognosis depends on two factors: the delay between onset of symptoms and operation and the severity of the neurological deficit.

Key words: Spinal epidural hematoma, spontaneous hematoma.

Case reports

Case 1

A 13-year-old boy had a fall from a ladder of 5 meters; he was admitted to the hospital on the same day. On admission he was conscious and complaining of pain in the left wrist. He was treated for luxation of the left wrist.

Roentgenograms of the lumbar vertebra did not show any evidence of fracture. The patient was discharged on the same day. One week later, at night, he awoke because of severe pain

* Department of Neurosurgery, University hospital, Ghent (Belgium), ** Department of Neurosurgery, St. Janshospitaal, Brugge (Belgium).

Address for correspondence and reprint requests: L. Calliauw, Department of Neurosurgery, University Hospital, De Pintelaan 185, 9000 Ghent, Belgium.

Accepted 2.11.87

in the cervico-dorsal region of the spine with weakness of both lower limbs. This weakness disappeared after 10 minutes. The following day he also complained of backache aggravated by walking; he was readmitted to the hospital. Neurological examination revealed tenderness over the lower cervical and T8-T9 thoracic vertebrals levels. Motor system examination of the lower limbs showed normal power, tone and bilaterally symmetrical knee and ankle reflexes. Plantar reflexes were flexor. Motor system examination of the upper limbs was normal. Sensory examination revealed hyperpathia from T8 to T12 and below this level hypesthesia was present. Micturition and defecation was normal. Bleeding and clotting time was normal. Blood analysis ruled out bleeding diathesis.

No fractures were seen on spinal radiograms. Myelography revealed widening of the ventral epidural space from the lower cervical vertebrae up to the level of T9; the spinal cord was pushed backward. The cerebrospinal fluid analysis was normal.

The computerized tomography suggested spinal epidural hematoma (Fig. 1). On 30.06.86 a laminectomy from T4 to T7 was done. Ventral to the dura an organized blood clot was found; the blood clot was evacuated. No traumatic lesions were seen. The clot did not reveal any abnormal vessels or neoplastic cells (histological examination).

Postoperatively the patient was relieved of pain and had improvement in his sensory deficits. At the time of discharge (12 days after admission) there were no neurological deficits. The patient is followed up at regular intervals; he has no complains.

Case 2

A 20-year-old man was admitted on 01.09.86 following a motorcycle accident. There was a short period of loss of consciousness. He was treated for fracture of the left humerus. Roentgenograms of skull and spine did not reveal abnormalities. He was discharged 8 days after admission to the hospital. Three months later he started to complain of weakness of the lower limbs. He also complained of decreased sensation in his lower limbs and thoracic region.

Neurological examination at that time revealed paresis of the lower limbs with hypes-

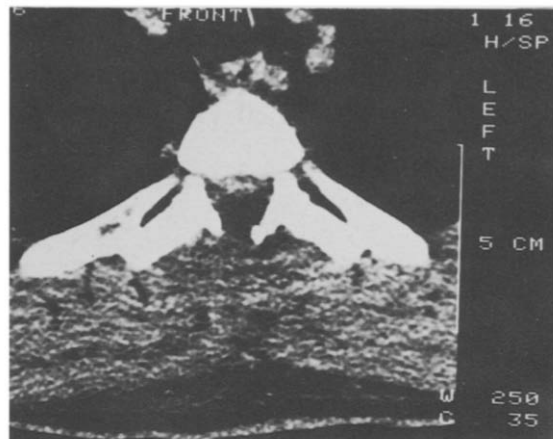


Fig. 1.
Case 1. Computerized Tomogram suggesting a ventral epidural hematoma.

thia of the left lower limb. Knee reflex and ankle reflex were bilaterally symmetrical. Babinski reflex had plantar response. Micturition and defecation were normal.

Cerebrospinal fluid analysis showed an elevated protein level (440 mg/100 ml). Electromyography showed diffuse peripheral neurogenic changes, considered then as characteristic of a Guillain-Barré syndrome. The paresis of the lower limb being progressive, he was treated with methyl-prednisolone (40 mg 2 times a day) and with vitamins. The patient was admitted to our department one month later.

Neurological examination revealed paresis of both lower limbs. The right lower limb was more paretic than the left one. Exaggerated knee and ankle reflexes were present bilaterally. Ankle and patellar clonus was present. The Babinski reflex on the right side was positive. The Babinski on the left side was indifferent.

Sensory examination revealed decreased epicritic, protopathic sensation at T5-T6 dermatome level. There was also decreased vibration sensibility over the lower limbs. The position sense was normal. In the upper limb the power, tone and reflexes were bilaterally symmetrical and normal. Micturition and defecation were normal.

Blood analysis ruled out bleeding diathesis. No fractures or other abnormalities were seen on spinal radiograms. Myelography revealed a complete stop at the level of T3 with compression of the spinal cord by an extradural space

occupying lesion up to C7.

A SSEP done on 10.12.86 by stimulating the nervus fibularis and tibialis above the knee revealed absence of response on the dorsal medulla of the upper thoracic spinal cord.

A computerized tomography was suggestive of spinal epidural hematoma. On 11.12.86 a laminectomy from T1 to T4 was done. Dorsal to the dura there was a xanthochromatic fluid collection with organized membranes. Evacuation of the chronic epidural hematoma with the organized membranes was done. The dura was opened at the level of T4 and revealed a normal medulla. No traumatic lesions were seen. The histological examination of the organized membranes showed epidural fat, few dilated blood vessels; this was interpreted as fibrosis of the dura.

Post-operatively there was improvement in motor power of lower limbs with diminution of exaggerated knee and ankle reflexes. Babinski was positive on the right side. The sensory deficit remained the same.

A SSEP done 4 weeks after the operation – when motor recuperation was already seen – revealed answers over the right side of the dorsal medulla of the upper thoracic spinal cord but on the left side there was no response.

Ct-scan (19.12.86) showed a backward shift of the medulla from T1 to T4. An NMR scan done on 27.01.87 showed an extradural fluid collection with atrophy of the spinal cord at the level

of T1 to T4 (Fig. 2a and 2b). The patient received intensive physiotherapy. A new SSEP examination revealed reproducible responses over right and left side of the dorsal medulla of the upper thoracic spinal cord.

At that time (08.04.87) the neurological examination revealed normal motor power in both lower limbs. The knee and ankle reflexes bilaterally were brisk. The ankle clonus was positive bilaterally. The sensory examination revealed improved proprioception and vibration sense at T5-T6. The epicritic sensation remained the same as before.

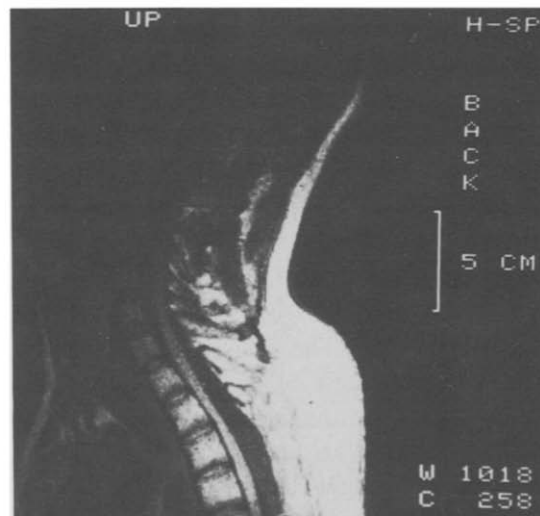
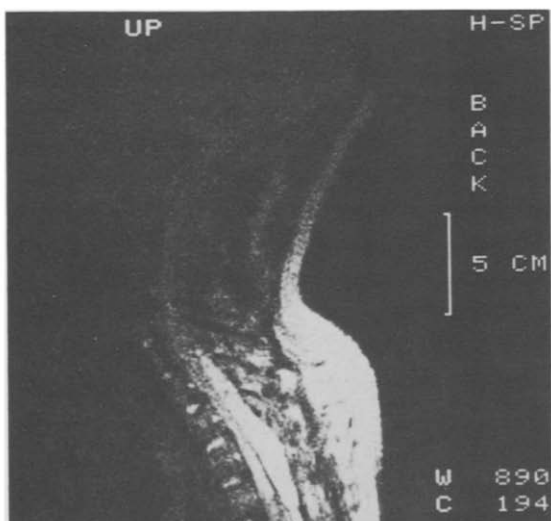
Case 3

A 39-year-old patient was admitted on 17.03.87 with a history of sudden onset of lower backache with weakness of lower limbs. He also complained of diffuse loss of sensation in both lower limbs. There was a history of urinary retention and constipation. The patient was known as having hemophilia (factor VIII A) at an earlier age.

There was history of occasional bleeding tendencies. He was admitted to our department on 19.03.87. Neurological examination revealed paraplegia with absence of knee and ankle reflexes. The plantar reflexes were flexor. There was loss of proprioceptive, epicritic, thermoanalgesic, vibration and position senses below the level of L2. There was loss of anal tone and anal reflex was absent. There was loss of cre-

Fig. 2a and b.

Case 2. NMR scan which shows (a) an extradural fluid collection and (b) an atrophy of the spinal cord.



masteric and bulbocavernosus reflexes.

No abnormalities were seen on spinal radiograms.

A myelogram revealed a total stop at the level of L4 with extradural compression of the cord up to T8. On 19.03.87 a laminectomy from T8 to L4 was done. Dorsal to the dura a large hematoma was evacuated. The antihemophilic factor was administered pre-, per- and post-operatively to stabilize factor 8.

14 days after the operation he was able to feel some sensation in both lower limbs and showed contraction in the right quadriceps. SSEP done on 31.03.87 showed reproducible responses over the dorsal medulla of the lower thoracic spinal cord in the left side but no responses on the right side. The patient received intensive physiotherapy.

On 03.04.87 motor system examination of the lower limbs showed normal tone, power grade II, knee and ankle reflexes bilaterally symmetrical exaggerated. Plantar reflexes were normal. There was improvement in epicritic, proprioceptive, thermo-analgesic, vibration and position sensation in both lower limbs. All modalities of sensation were absent at S1 to S5 dermatome level. Anal tone was lost and anal reflex absent, bulbocavernosus reflex absent, cremasteric reflex was positive on the right side and absent on the left side.

The last follow-up done on 15.05.87 shows normal tone in both lower limbs. The power is grade IV. Bilaterally symmetrical exaggerated knee and ankle reflexes. Sensory examination revealed further improvement in all modalities of sensation in both lower limbs. There is some epicritic and proprioceptive sensation in S1 to S5 region. Anal tone and anal reflexes absent. Bulbocavernosus and cremasteric reflexes present. Patient needs intermittent catheterization every 3 hours. During defecation he does not feel the sensation of the stools.

Case 4

A 63-year-old man experienced lower lumbar pain on 21.03.83. The following day he complained of weakness of the lower limbs with retention of urine; he was admitted to our department. Neurological examination revealed paralysis of the right lower limb and paresis of the left lower limb. The knee and ankle reflexes

were absent bilaterally. The plantar reflex had a flexor response bilaterally. Sensory examination revealed saddle anaesthesia and decrease of all modalities of sensation in both lower limbs. There was urinary retention. Blood analysis did not reveal any bleeding diathesis. Spinal radiograms were normal.

A myelogram on 29.03.83 revealed a stop at L1 due to compression by an epidural process (Fig. 3).

A laminectomy T12 to L3 was done and an epidural hematoma located dorsal to the dura was evacuated. Histological examination revealed epidural fat and hematoma; there was no evidence of abnormal vessels or neoplastic cells. Post-operatively there was motor improvement in both lower limbs. He was discharged from hospital on 28.04.83. At the time of discharge he had paresis of right foot due to involvement of tibialis anterior. There was diffuse hypoesthesia in both lower limbs. He was able to walk with the help of a stick. He received physiotherapy. A follow-up on 16.03.83 was done. Segmentary muscle testing did not show any deficit.

Knee reflex was bilaterally symmetrical. Ankle reflex on the right side was absent. The plantar reflex had a flexor response. Sensory examination revealed absence of all modalities of sensation in L5, S1 S2 of the right lower limb. There was good control of micturition and defecation. Patient is followed up at regular intervals.

Fig. 3.

Case 4. Myelogram with a stop at L1 due to compression by an epidural process.

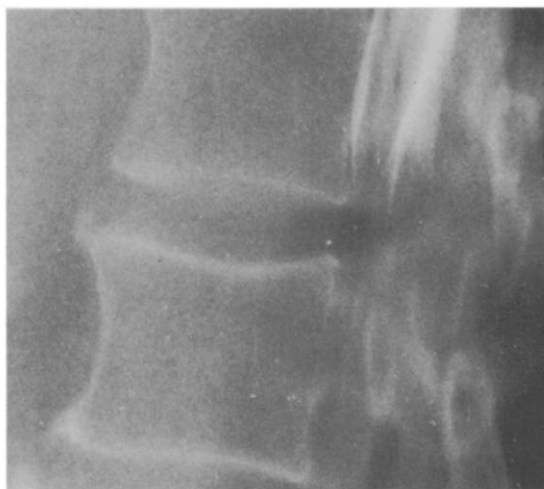

Table 1: Summary of the 4 cases

Case	Pre-operative neurological status	Level of laminectomy	Time between onset of symptoms and operation	Results of surgical treatment
1	Partial sensory deficit below T8	T4-T7	2 days	complete recovery
2	Incomplete sensory-motor deficit	T1-T4	10 days	motor recovery sensory deficit remains
3	Complete sensory-motor deficit Urinary retention	T8-L4	2 days	Improvement of motor and sensory function but deficit remains. No bladder control.
4	Paralysis right lower limb Paresis left lower limb Sensory deficit Urinary retention	T12-L3	2 days	motor recovery sensory improvement spontaneous micturation

Discussion

The cause of these hematomas is often unknown; therefore some of them are considered to be spontaneous. The term 'spontaneous' means without an identified etiology. According to this definition, only our case 4 can be called 'spontaneous'.

The other spinal epidural hemorrhages have been associated with coagulopathy, AVM or some iatrogenic causes (lumbar puncture, epidural anesthesia, surgical procedures).

The relationship to trauma is controversial except in cases with lesions on the spinal radiograms.

Some authors have included patients with minor trauma into the category of spontaneous hematomas³. As pointed out by Ghanem and Ivan it is difficult to draw the line between mild trauma and the activities of daily living⁴. The same can be said for hematomas occurring after lifting heavy weights¹, pulling a chair or in the course of whooping cough⁵; is that spontaneous, or is the increase of intrathoracic/intra-abdominal pressure associated to trauma? Whatever the etiology may be, the mechanism of the bleeding is also a mystery. Supporters of the venous origin argue that the epidural veins belong to a primitive venous system which has no venous valves. This valveless plexiform network is connected above with the cranial dural sinus, below with the pelvic veins and in the neck and

trunk with the azygos and caval systems. Hence an abrupt pressure change in the visceral cavities can be transmitted directly to pre-existing pathological epidural veins and provoke their rupture. It is very probable that such an epidural venous bleeding will be quickly tamponaded by the expanded dural sac as the intrathecal pressure is higher than the pressure in the veins. To explain a progression of the bleeding, leading to compression of the cord, a low pressure in the epidural space has to be supposed.

The venous origin is therefore problematic although the clinical course of our case 1 and 2, in which the clinical signs of cord compression started respectively 9 days and 3 months after a traumatic event, fall in favour of a venous origin of the bleeding.

Those who favour the hypothesis that the hemorrhage originates from an arterial source stress the rapidity with which some patients become paraplegic after the onset of pain, a phenomenon which does not occur in the cases we have outlined.

The arterial source has to be found in ascending and descending arteries running in the spinal dura. Those arteries are fed by arteries that run with the nerve sheath. According to Beatty and Winston³ some of these bridging-arteries – specially in the cervical region – have a free portion. Stretching of these arteries could result in hemorrhage. The above-mentioned authors bear out their hypothesis by the fact that epidural

spinal hematomas frequently originate in the cervical region and that, in the patients they have operated, the bleeding was predominantly lateral.

None of our 4 cases corresponds to these criteria. In addition it seems difficult to explain why nobody has seen bleeding arteries after removing a clot, especially after an early operation. It is unlikely that all these arteries have been thrombosed.

The origin of the hemorrhage remains a mystery, and the hypothesis of the 'cryptic vascular anomalies' of Robertson is pure hypothesis⁶; it has never been proved.

Concerning the prognosis, the results of our 4 cases can only accord with the conclusions made by Foo and Rossier¹.

- Operating quickly on an incomplete lesion means a very good chance of complete recovery (case 1 and 4).
- An incomplete lesion operated with delay can recover but with greater chance of deficit (case 2).

- Even a complete sensory-motor lesion should be operated on. The absence of sensorimotor functions before operation does not necessarily indicate a poor prognosis, since partial neurological return is noticed (case 3).

The SSEP seemed not to be of great value since their return was always preceded by clinical improvement.

References

- ¹ FOO DK, ROSSIER AB. Pre-operative Neurological Status in predicting surgical outcome of spinal epidural hematomas. *Surgical Neurology* 1981; 15:389-401.
- ² KLOSSEK VH, HÜLLER E. Zur Problematik der spontanen spinal epidurale Hämatome. *Zentralblatt für Neurochirurgie* 1984; 45:116-123.
- ³ BEATTY RM, WINSTON KR. Spontaneous cervical epidural hematoma. *J Neurosurg* 1984; 61:143-148.
- ⁴ GHANEM Q, IVAN LP. Spontaneous spinal epidural hematoma in an 8-year-old boy. *Neurology* 1978; 28:832-92.
- ⁵ JACKSON FE. Spontaneous spinal epidural hematoma coincident with whooping cough. *J. Neurosurg* 1963; 20:715-7.
- ⁶ ROBERTSON WC JR, LEE YN, EDMONSON MB. Spontaneous spinal epidural hematoma in the young. *Neurology* 1979; 29:120-2.