



# Treatment of a Scalp Arteriovenous Malformation by a Combination of Embolization and Surgical Removal

Atsushi Kuwano<sup>1,2</sup>, Isao Naitou<sup>3</sup>, Naoko Miyamoto<sup>3</sup>, Koji Arai<sup>1,2</sup>, Takakazu Kawamata<sup>2</sup>

## Key words

- Cerebral blood flow
- Onyx
- Scalp arteriovenous malformation

## Abbreviations and Acronyms

CT: Computed tomography

From the <sup>1</sup>Department of Neurosurgery, Iseaki-Sawa Medical Association Hospital, Iseaki, Gunma; <sup>2</sup>Department of Neurosurgery, Tokyo Women's Medical University, Shinjuku, Tokyo; and <sup>3</sup>Department of Neurosurgery, Geriatrics Research Institute and Hospital, Maebashi, Gunma, Japan

To whom correspondence should be addressed:

Atsushi Kuwano, M.D.

[E-mail: [kuwano.atsushi@twmu.ac.jp](mailto:kuwano.atsushi@twmu.ac.jp)]

Citation: *World Neurosurg.* (2020) 138:93-97.

<https://doi.org/10.1016/j.wneu.2020.02.138>

Journal homepage: [www.journals.elsevier.com/world-neurosurgery](http://www.journals.elsevier.com/world-neurosurgery)

Available online: [www.sciencedirect.com](http://www.sciencedirect.com)

1878-8750/\$ - see front matter © 2020 Elsevier Inc. All rights reserved.

## INTRODUCTION

Scalp arteriovenous malformation is a rare disease that can interfere with daily life.<sup>1,2</sup> The underlying cause could be trauma, congenital, or idiopathic.<sup>3,4</sup> Clinical symptoms include headache, local pain, bruits, tinnitus, and larger lesions that can result in skin necrosis.<sup>2,5,6</sup> In addition, epilepsy and cerebral ischemia may be caused by extracranial shunting of common carotid blood flow.<sup>7,8</sup> In terms of treatment, surgical removal is often effective and performed.<sup>5,6,9</sup> With the development of endovascular treatments, a combination of surgical removal and embolization is now often performed.

Here, we report a case of scalp arteriovenous malformation that was treated with a combination of embolization and surgical removal.

## CASE REPORT

A 44-year-old man presented with a mass in his left occipital region 6 months before visiting our department. The mass lesion

■ **BACKGROUND:** Scalp arteriovenous malformation is a rare disease. In terms of treatment, surgical removal is often effective and performed. With the development of endovascular treatments, a combination of surgical removal and embolization is now often performed.

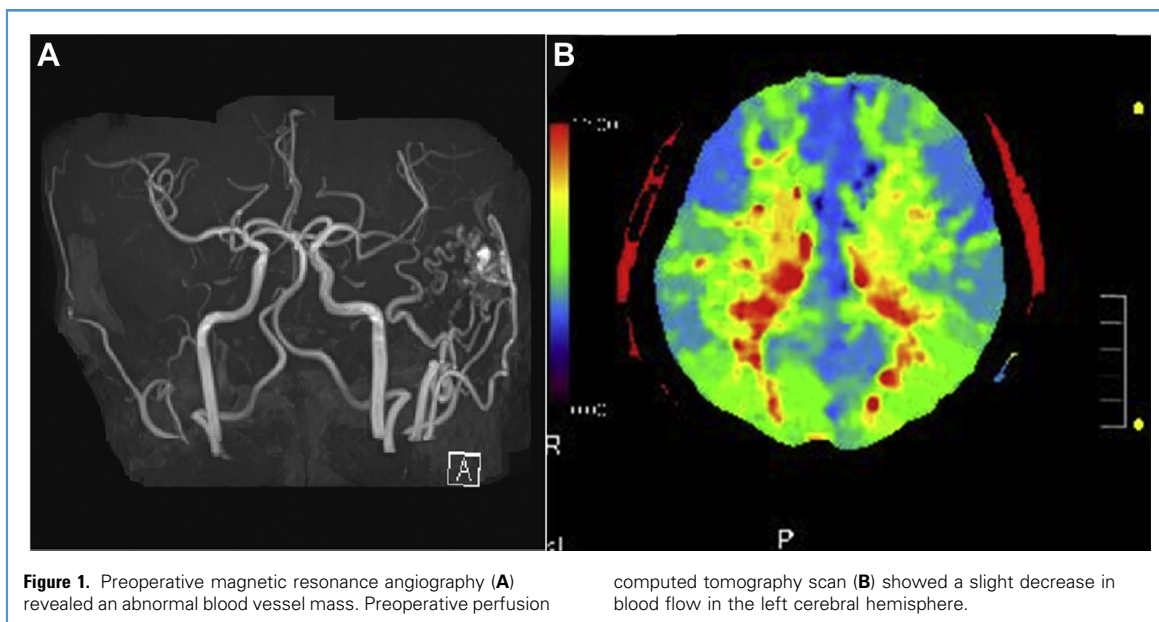
■ **CASE DESCRIPTION:** A 44-year-old man presented with a mass in his left occipital region. Cerebral angiography led to a diagnosis of scalp arteriovenous malformation. Although he had no neurologic deficits, perfusion computed tomography (CT) scan showed a slight decrease in blood flow in the left cerebral hemisphere, which was presumed to have been caused by the scalp arteriovenous malformation. He suffered from a sleep disorder caused by tinnitus, and a discomfort with the lesion itself; therefore, we decided to surgically remove the lesion. To suppress intraoperative bleeding and safely perform the surgery, preoperative embolization was also planned. After treatment, he had no neurologic deficits and the sleep disorder improved. Perfusion CT scan performed after the surgery showed an improvement in cerebral blood flow in the left cerebral hemisphere.

■ **CONCLUSIONS:** Because cerebral blood flow may decrease depending on the progression of the lesion, the cerebral blood flow should be evaluated. Considering the treatment modalities depending on the lesion can provide treatment with less recurrence and higher patient satisfaction.

gradually increased with pulsation. As the mass lesion grew, tinnitus began to appear. As the symptoms worsened, he suffered from a sleep disorder caused by tinnitus, and felt uncomfortable with the lesion when he was in the supine position, which prompted him to visit our department. During the visit, no neurologic deficits were observed, and a mass of approximately 30 mm was found in his left occipital region. Magnetic resonance angiography revealed an abnormal blood vessel mass consistent with the lesion (Figure 1). Cerebral angiography showed that the occipital and posterior auricular arteries were acting as feeders, whereas the superficial vein was acting as a drainer, which subsequently led to the formation of the abnormal blood vessel mass (Figure 2). These arteries and veins did not interact in the intracranial area, leading to a diagnosis of scalp arteriovenous malformation. Perfusion computed tomography (CT) scan was

performed to evaluate cerebral blood flow, therefore revealing a slight decrease in flow in the left cerebral hemisphere (Figure 1). Because the patient suffered from tinnitus and had trouble sleeping because of discomfort from the lesion, we decided to perform surgery to remove the lesion.

To reduce the amount of bleeding and safely remove the lesion, we decided to perform embolization in advance. During embolization, we injected Onyx through the occipital artery branch to embolize the nidus. Finally, the feeder, nidus, and drainer were embolized. Tinnitus disappeared immediately after embolization, but the discomfort caused by the lesion remained. Next, we removed the lesion. To preserve the blood flow in skin, a skin incision was performed from the cranial side to caudal side on the lesion such that the occipital and posterior auricular arteries were not cut (Figure 3). The nidus was subsequently submitted to pathology for analysis. The



**Figure 1.** Preoperative magnetic resonance angiography (A) revealed an abnormal blood vessel mass. Preoperative perfusion

computed tomography scan (B) showed a slight decrease in blood flow in the left cerebral hemisphere.

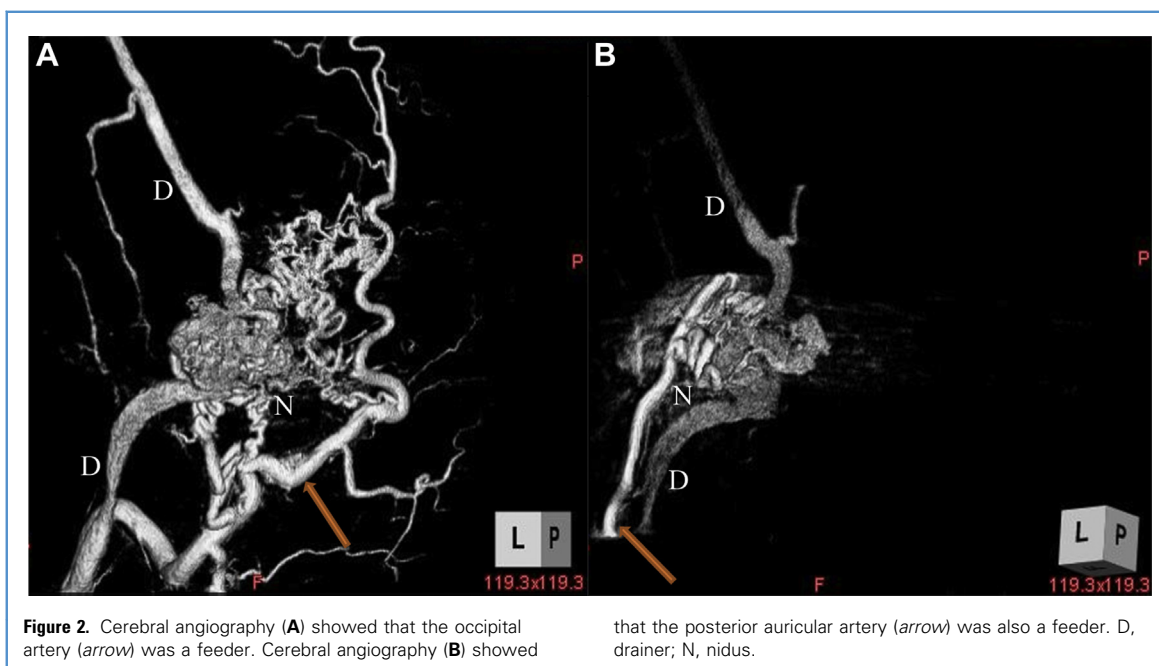
discomfort caused by the lesion disappeared after removal of the lesion. Postoperatively, the patient had no neurologic deficits, the nidus was no longer observed in the magnetic resonance angiography, and perfusion CT scan showed improved cerebral blood flow in the left cerebral hemisphere (Figure 4). The pathology results of the resected lesion revealed an abnormal blood vessel mass with mixed arteries and veins of various sizes, and the

findings were consistent with arteriovenous malformations. Furthermore, Onyx and thrombus were confirmed in the lumen of the blood vessels (Figure 5).

### DISCUSSION

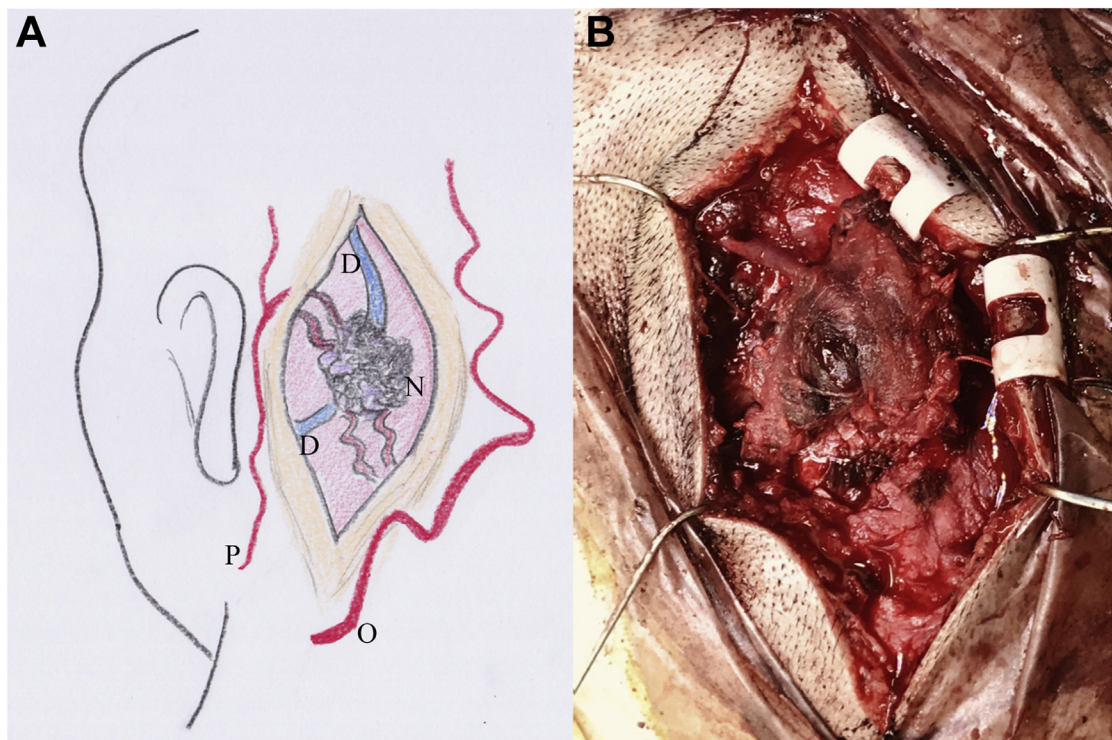
Scalp arteriovenous malformation is an abnormal blood vessel mass between the feeding arteries and draining veins, without an intervening capillary bed

within the subcutaneous layer.<sup>1,2</sup> Clinical symptoms include headache, local pain, bruits, tinnitus, and larger lesions that can result in skin necrosis.<sup>3,5,6</sup> Additionally, epilepsy and cerebral ischemia may be caused by extracranial shunting of common carotid blood flow.<sup>7,8</sup> In terms of treatment, surgical removal is effective and most widely performed.<sup>5,6,9</sup> With the development of endovascular treatments, a combination



**Figure 2.** Cerebral angiography (A) showed that the occipital artery (arrow) was a feeder. Cerebral angiography (B) showed

that the posterior auricular artery (arrow) was also a feeder. D, drainer; N, nidus.



**Figure 3.** Intraoperative images of nidus removal. To preserve the blood flow in skin, a skin incision was performed from the cranial side to caudal side on the lesion such that the occipital

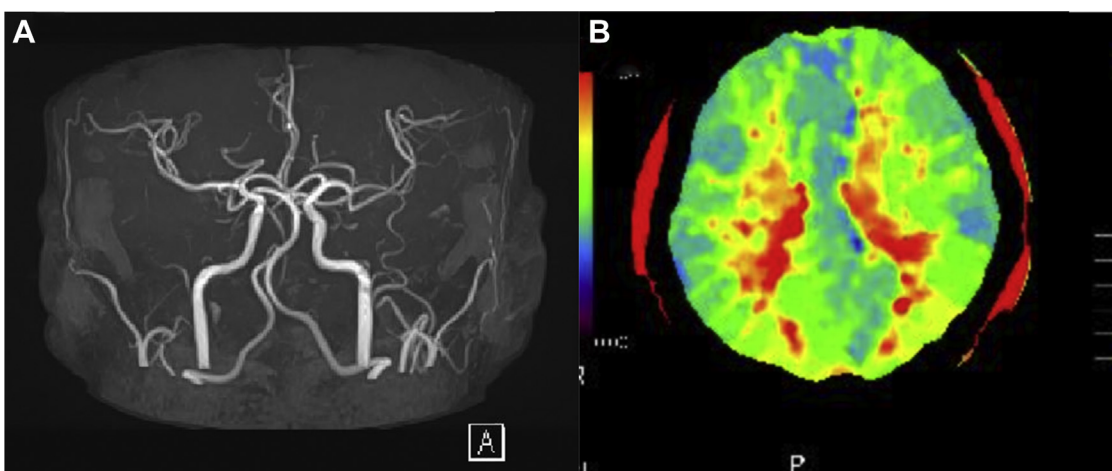
and posterior auricular arteries were not cut (A). The nidus was dyed black with Onyx (B). D, drainer; N, nidus; O, occipital artery; P, posterior auricular artery.

of surgical removal and embolization is now often performed.

In the presented case, the patient visited our department because of the lesion,

which caused sleep disturbance because of tinnitus and discomfort with the lesion itself. Furthermore, the patient was diagnosed with a scalp arteriovenous

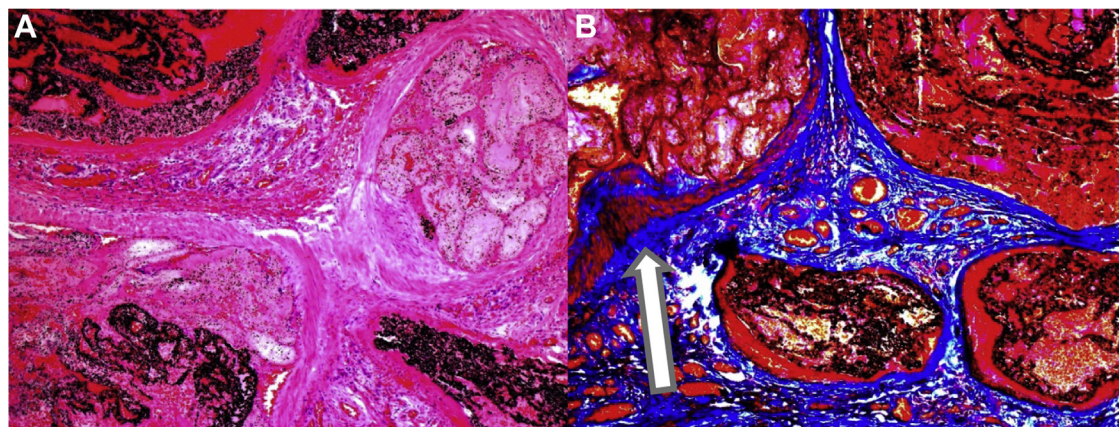
malformation via cerebral angiography. Therefore, surgical resection of the mass was recommended. Although he had no neurologic deficits, perfusion CT scan



**Figure 4.** There was no nidus in the postoperative magnetic resonance angiography (A). Perfusion computed tomography

scan performed after the surgery (B) showed an improvement in cerebral blood flow in the left cerebral hemisphere.





**Figure 5.** Pathologic images of nidus. (A) Hematoxylin and eosin stain (original magnification  $\times 50$ ) showed that Onyx and thrombus were confirmed in the lumen of the blood vessels. (B) Azan stain (original magnification  $\times 50$ ) showed discrimination

between arteries and veins. Arteries (arrow) had smooth muscles and thick walls. The pathologic findings were consistent with arteriovenous malformation, with mixed arteries and veins.

showed a slight decrease in blood flow in the left cerebral hemisphere, which was presumed to have been caused by the scalp arteriovenous malformation.

This case was diagnosed with scalp arteriovenous malformation, which is sometimes referred to scalp arteriovenous fistula.<sup>10</sup> Although these terms are used interchangeably, they should be distinguished from each other because both have different pathologies.<sup>10</sup> The characteristics of cerebral angiography for scalp arteriovenous malformation include the formation of an abnormal blood vessel mass, whereas scalp arteriovenous fistula results in directly anastomoses arteries and veins that do not go through an abnormal vessel mass.<sup>10,11</sup> Because this case presented with an abnormal blood vessel mass, a diagnosis of scalp arteriovenous malformation was made. In both cases, endovascular treatment and removal are typically recommended. Some complications of surgical removal include skin necrosis and intra- and postoperative massive bleeding from the scalp, whereas complications of embolization include neurologic deficits via dangerous anastomosis.<sup>5,9,12,13</sup> Moreover, we observed skin necrosis during the time at which Onyx was used as an embolic substance.<sup>14</sup> In cases of scalp arteriovenous malformation, the patient should be carefully monitored for postoperative recurrence. There have

been several studies comparing surgical removal, embolization, and a combination of both for postoperative recurrence.<sup>12,15</sup> These studies reported that embolization alone resulted in potential recurrence, but there was no recurrence with surgical removal or a combination of both.<sup>12,15</sup> We need to understand the characteristics of treatment modalities (Table 1). In cases of recurrence caused by endovascular treatment alone, it has been reported that large lesions or complicated vascular structures are the causes.<sup>2,15,16</sup> If the lesion is large, or the vascular architecture is complex, endovascular treatment alone may be inadequate; therefore, we should make plans that include surgical removal. Understanding the anatomic features of the lesion and considering treatment modalities can provide treatment with less recurrence and higher patient satisfaction.<sup>17</sup>

In this patient, the occipital and posterior auricular arteries were observed as feeders, forming complex nidus, and the vascular architecture was complicated; therefore, endovascular treatment alone was considered to be a high risk of recurrence. In addition to that, a sleep disorder was caused by the discomfort with the lesion itself; therefore, we decided to surgically remove the lesion. Because of the anatomic features of the lesion and sleep disorder caused by it, we decided to treat by a combination of endovascular treatment and surgical removal. To suppress intraoperative bleeding and safely perform the surgery, preoperative embolization was planned. The surgical goal was achieved by embolizing the proximal region of the feeder, but if the entire occipital artery is embolized, skin perfusion of the occipital region would decrease, which was a concern because the patient was judged to have a

**Table 1.** Advantages and Disadvantages of Treatment Modalities

Treatment Modality	Advantages	Disadvantages
Embolization	Small scar	Neurologic deficits via dangerous anastomosis/recurrence/skin necrosis
Surgical removal	Less recurrence	Intra- and postoperative hemorrhage
Combined treatment	Less recurrence/less hemorrhage	Neurologic deficits via dangerous anastomosis/skin necrosis

risk of skin necrosis after the operation. In this case, to preserve the main trunk of the occipital artery, we decided to perform the embolization starting from the branch of the occipital artery feeder. We were careful not to disrupt the anastomosis between the occipital and vertebral arteries at the cervical vertebrae C1 and C2; therefore, the vertebral artery was imaged from the occipital artery.<sup>18</sup> Because embolization was performed from the distal part of the anastomosis, we were able to perform the embolization safely. Subsequently, embolization was performed from the branch of the occipital artery using Onyx such that the nidus and drainer could be embolized, before finally embolizing the feeder, nidus, and drainer. The patient had no neurologic deficits after the embolization. Thereafter, the lesion was surgically removed. To preserve skin perfusion, the incision was designed with a straight incision just above the lesion such that the occipital and posterior auricular arteries were not damaged. The nidus was hardened by Onyx and turned black, and the amount of intraoperative bleeding was minimal.

Perfusion CT scan performed after the surgery showed an improvement in cerebral blood flow in the left cerebral hemisphere. Some studies have reported epilepsy and ischemic symptoms because of extracranial shunting of common carotid blood flow of the scalp arteriovenous malformation.<sup>7,8</sup> In the presented case, although the patient had no neurologic deficits, the cerebral blood flow was decreased in the left cerebral hemisphere before the surgery, and improved after the surgery. To our knowledge, this is the first case where cerebral blood flow was evaluated for scalp arteriovenous malformation both pre- and postsurgery. In this case, as the lesion increased, there was a risk of symptoms occurring because of extracranial shunting of common carotid blood flow. Therefore, an evaluation of the cerebral blood flow should be performed for cases of scalp arteriovenous malformation.

The pathologic diagnosis was scalp arteriovenous malformation. Onyx and thrombus were confirmed in the lumen of the blood vessels, and the abnormal blood vessel mass had mixed arteries and veins. There was no contradiction between the clinical and pathologic diagnoses.

## CONCLUSIONS

We experienced a rare case of scalp arteriovenous malformation treated with a combination of embolization and surgical removal. Because cerebral blood flow may decrease depending on the progression of the lesion, the cerebral blood flow should be evaluated. Considering the treatment modalities depending on the lesion can provide treatment with less recurrence and higher patient satisfaction.

## REFERENCES

1. Fard MO, Yousofnejad O, Heydari M. Traumatic arteriovenous malformation of the superficial temporal artery. *Adv Biomed Res.* 2017;6:82.
2. Hasturk AE, Erten F, Ayata T. Giant non-traumatic arteriovenous malformation of the scalp. *Asian J Neurosurg.* 2012;7:39.
3. Kannath SK, Rajan JE. Percutaneous embolization of scalp arteriovenous malformation using new liquid embolic agent, SQUID: a technical report. *J Clin Interv Radiol.* 2017;1:171-174.
4. Oishi H, Yoshida K, Tange Y, Tsuji O, Sonobe M. Treatment of a scalp arteriovenous malformation by a combination of embolization and surgical removal. *Interv Neuroradiol.* 2002;8:293-297.
5. Worm PV, Ruschel LG, Roxo MR, Camelo R. Giant scalp arteriovenous malformation. *Rev Assoc Med Bras (1992).* 2016;62:828-830.
6. Nishijima I, Ikemura R, Gushiken M, Miyagi K, Iha K. Nonsurgical treatment of scalp arteriovenous malformation using a combination of ultrasound-guided thrombin injection and trans-arterial coil embolization. *J Vasc Surg.* 2012;55:833-836.
7. Mohanty S, Rao C. A large cirroid aneurysm of the scalp associated with epilepsy. *J Neurol Neurosurg Psychiatry.* 1976;39:835-836.
8. Ohno K, Tone O, Inaba Y, Terasaki T. [Coexistent congenital arteriovenous malformation aneurysms of the scalp (author's transl)]. *No Shinkei Geka.* 1981;9:1187-1191 (in Japanese).
9. Sugiu K, Hishikawa T, Hiramatsu M, et al. Endovascular treatment for craniofacial arteriovenous fistula/malformation. *J Neuroendovasc Ther.* 2019;13:206-215.
10. Komatsu Y, Narushima K, Kobayashi E, Nose T, Maki Y. Congenital arteriovenous malformation of the scalp—case report. *Neurol Med Chir (Tokyo).* 1989;29:230-234.
11. Matsumaru Y. Endovascular treatment for brain arteriovenous malformation and dural arteriovenous fistula. *Jpn J Neurosurg.* 2013;22:911-916.
12. Xue B, Yi L, Chao Y. Surgical resection of a complex multiple scalp AVF without preoperative embolization: a case report. *Turk Neurosurg.* 2015;25:638-642.
13. Kuwajima A, Chokyu K, Kashimura Y, et al. Two cases of arteriovenous fistula of the scalp in which the pressure cooker technique was useful. *J Neuroendovasc Ther.* 2018;12:416-422.
14. Singla A, Fargen KM, Hoh B. Onyx extrusion through the scalp after embolization of dural arteriovenous fistula. *BMJ Case Rep.* 2015;2015.bcr2015011879.
15. Zheng J, Guo Z, Zhang X, Sun X. Intravascular embolization versus surgical resection for patients with scalp arteriovenous fistula. *Chin Neurosurg J.* 2019;5:3.
16. Corr PD. Cirroid aneurysm of the scalp. *Singapore Med J.* 2007;48:e268-e269.
17. Hage ZA, Few JW, Surdell DL, Adel JG, Batjer HH, Bendok BR. Modern endovascular and aesthetic surgery techniques to treat arteriovenous malformations of the scalp: case illustration. *Surg Neurol.* 2008;70:198-203 [discussion: 203].
18. Komiya M. Essential anatomical knowledge for neurointervention: functional neurovascular anatomy. *Jpn J Neurosurg (Tokyo).* 2004;13:116-125.

*Conflict of interest statement:* The authors declare that the article content was composed in the absence of any commercial or financial relationships that could be construed as a potential conflict of interest.

Received 5 February 2020; accepted 23 February 2020

Citation: *World Neurosurg.* (2020) 138:93-97.  
<https://doi.org/10.1016/j.wneu.2020.02.138>

Journal homepage: [www.journals.elsevier.com/world-neurosurgery](http://www.journals.elsevier.com/world-neurosurgery)

Available online: [www.sciencedirect.com](http://www.sciencedirect.com)

1878-8750/\$ - see front matter © 2020 Elsevier Inc. All rights reserved.