


NEURO-IMAGES



Another Pitfall in Brain Death Diagnosis: Return of Cerebral Function After Determination of Brain Death by Both Clinical and Radionuclide Cerebral Perfusion Imaging

Julius Gene S. Latorre^{1*} , Elena B. Schmidt¹ and David M. Greer²

© 2020 Springer Science+Business Media, LLC, part of Springer Nature and Neurocritical Care Society

Introduction

Brain single-photon emission computed tomography (SPECT) is a noninvasive ancillary test used in selected patients in the determination of brain death (BD) with reported 100% specificity [1]. We report a case of false-positive brain SPECT imaging in a patient who fulfilled clinical criteria (minus apnea testing) for BD but who subsequently regained some cerebral function.

Case Report

A 59-year-old man suffered catastrophic brain injury due to a spontaneous intracerebral hemorrhage likely secondary to uncontrolled hypertension (See Fig. 1). CT angiography revealed no aneurysm or vascular malformation. Repeat head CT the next day (See Fig. 2) showed worsening cerebral edema, herniation and mass effect. The patient remained unresponsive off all sedation except for right lower extremity withdrawal to stimulation. The next day, this movement was no longer observed.

Clinical Neurological Examination

Clinical BD testing was performed based on our institutional protocol (See Appendix 1), adapted from the 2010 American Academy of Neurology guidelines [2].

A board certified neurointensivist performed the neurologic examination. Otoloscopic examination showed normal tympanic membranes bilaterally. Cranial nerve examination showed fixed dilated pupils at 6 mm bilaterally using bright LED light, absent corneal reflexes using a sterile cotton swab, absent oculocephalic and oculovestibular reflexes, absent cough and gag reflexes, absent spontaneous respirations, absent grimace to supraorbital pressure, absent motor response to central and peripheral noxious stimulation. Apnea testing was deemed unsafe due to hemodynamic instability requiring multiple vasopressors (norepinephrine and vasopressin). Therefore, a brain SPECT was obtained within 1 h of completing the clinical examination, with no alterations in his management in that intervening time.

Nuclear Medicine Procedure

Radiopharmaceutical preparation The Tc-99mBicisate (Neurolite, Du Pont Merck Pharmaceutical Company, Billerica, MA, USA) was prepared and stabilized according to manufacturer specification, and 1.1038 Gbq (27.4 mCi) of Tc-99m Bicisate was used.

Study acquisition Scintigraphy was performed according to the Practice Parameters and Technical Stand-

*Correspondence: latorrej@upstate.edu

¹ Department of Neurology and Neurosurgery (UH-7134), SUNY Upstate Medical University, 750 East Adams Street, Syracuse, NY 13210, USA
Full list of author information is available at the end of the article

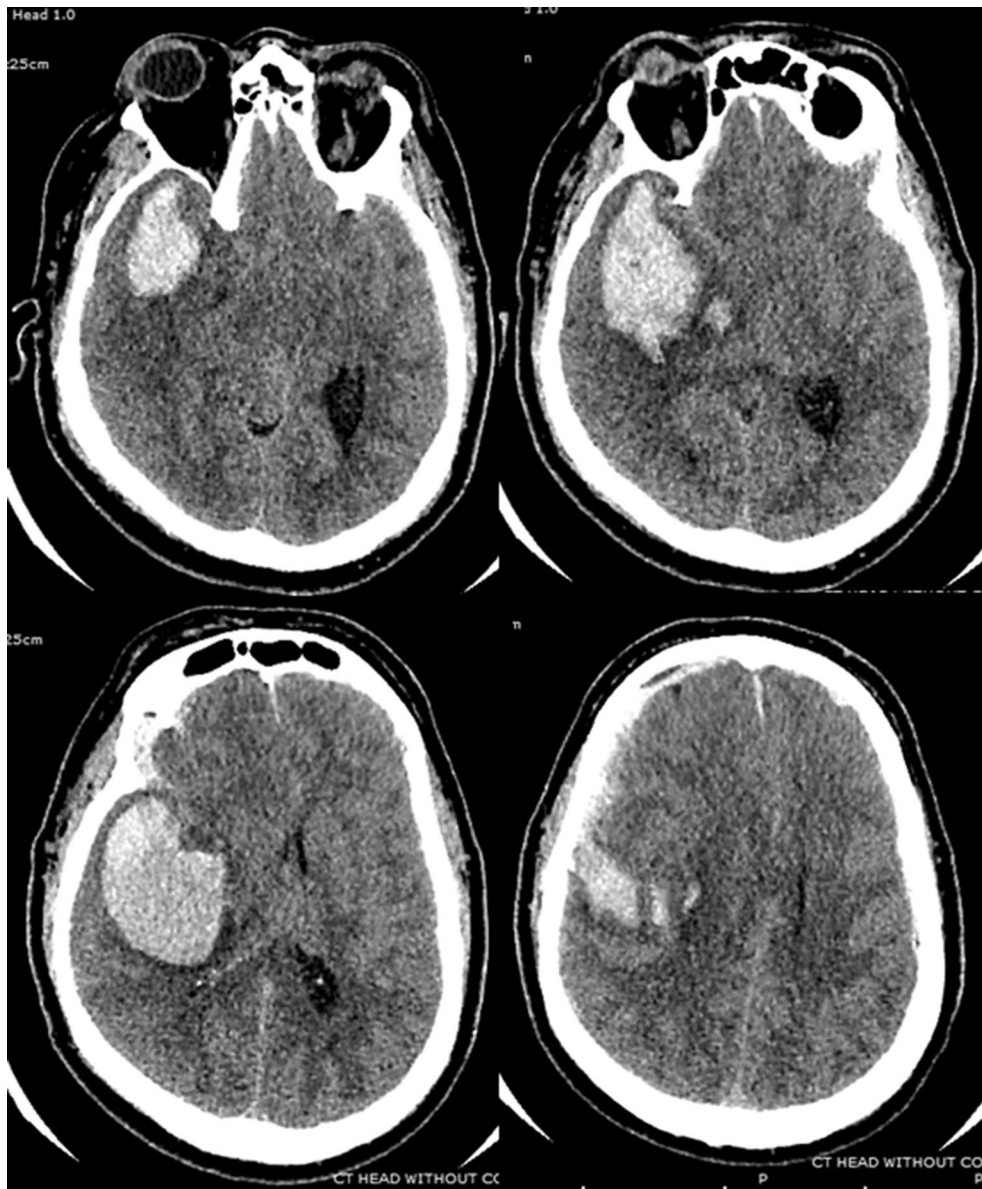


Fig. 1 CT scan on admission (2 h after event) A noncontrast CT brain obtained 2 h from last known well showing a large intraparenchymal hematoma measuring 6.4 × 4.5 cm centered in the right basal ganglia extending into the right temporal lobe into the middle cranial fossa. There was a separate focus of intraparenchymal hemorrhage just medial to this large hematoma measuring 9.3 × 1.1 cm. There were bilateral subdural hematomas, right greater than left, with the right measuring 5 mm in greatest thickness and the left measuring 2 mm in greatest thickness. Scattered areas of subarachnoid hemorrhage were identified overlying the right cerebral hemisphere. There was significant mass effect on the adjacent brain parenchyma in the right lateral ventricle, which was partially effaced. There was approximately 1.1 cm midline shift to the left of the level of the lateral ventricles. Right uncal herniation was noted

ards for the performance of SPECT imaging as recommended by the American College of Radiology (ACR) [3], 51 h from symptom onset with the patient supine, including the head and neck in the gamma camera's

field of view. For additional details of the study acquisition, please refer to "Appendix 2".

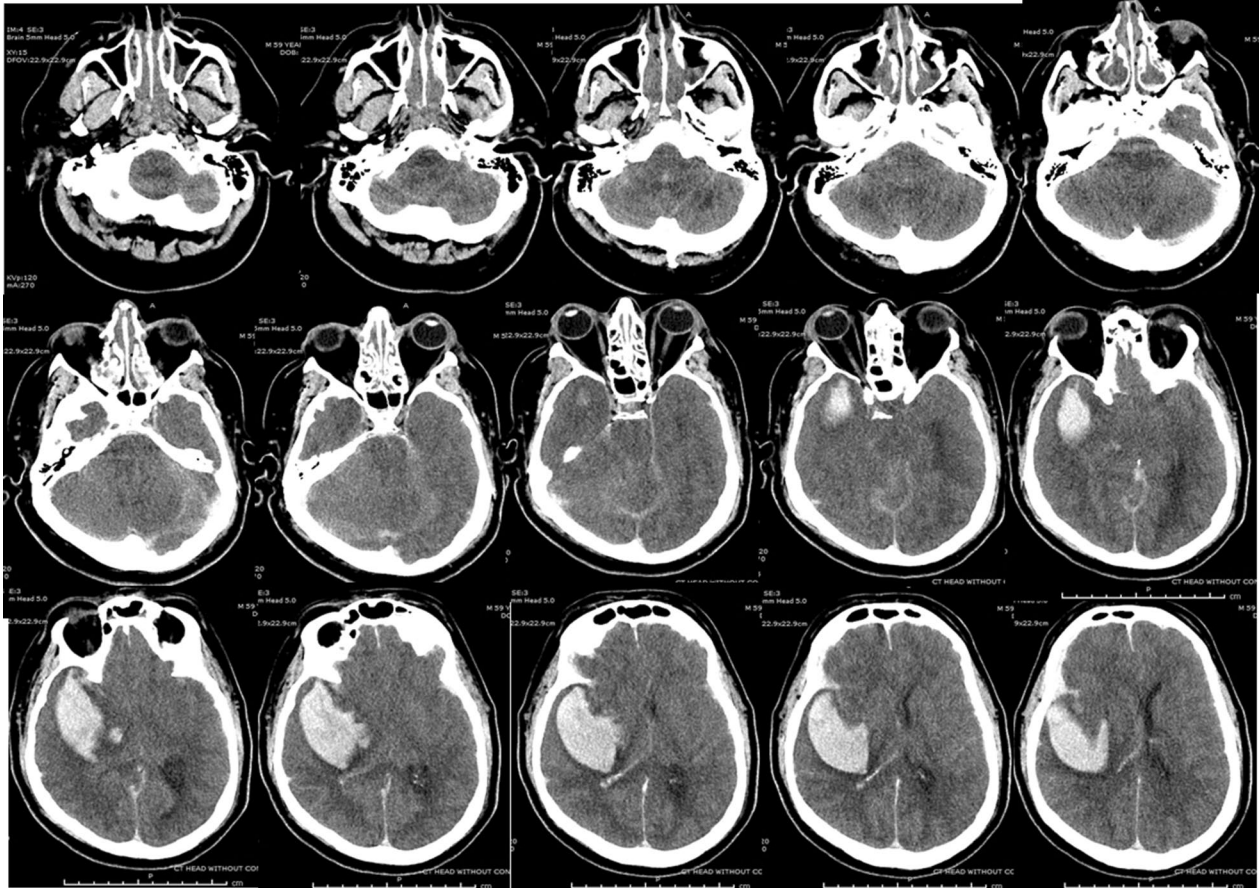


Fig. 2 Follow-up CT scan (17 h after event) A noncontrast CT brain obtained 17 h from last known well showing the large intraparenchymal hematoma along the right temporal and insular region, with compression of the lateral ventricle, midline shift causing leftward subfalcine herniation. Both transtentorial and tonsillar herniations were present



Fig. 3 Cerebral perfusion scintigraphy performed 51 h after event (A-coronal, B-axial, C-sagittal view). The absence of Tc-99m Bicisate uptake in the cerebral hemispheres and posterior fossa on static images was interpreted as consistent with BD. A nuclear medicine attending physician evaluated and interpreted the study. The images were reviewed independently and in a blinded fashion in a separate academic institution by attending nuclear medicine physicians

BD Determination and Hospital Course

The patient was declared dead after the brain SPECT result was finalized documenting the absence of

radionuclide uptake intracranially (See Fig. 3), and the family subsequently consented to organ donation. The following morning, the nurse reported a cough response.

Repeat assessment confirmed the presence of cough, intermittent spontaneous respirations and extensor posturing of the right arm and leg to noxious stimulation. The family was informed of the new findings, but before any further decisions could be made, the patient developed a generalized seizure followed by ventricular tachycardia and cardiac arrest. No autopsy was performed.

Discussion

This is the first report of a false-positive brain SPECT in a BD patient who subsequently exhibited indisputable brainstem function (cough reflex, spontaneous respirations, extensor motor response). Although the reported generalized seizure could have represented cortical activity, convulsive-like movement due to brainstem irritation was another possibility.

Until now, there have been no reports of false-positive brain SPECT using diffusible radiopharmaceutical tracers [4] in a patient who did meet the clinical criteria for BD when strict procedural parameters for radionuclide scanning as recommended by ACR were performed. Appropriate quality measures in the preparation of the radiopharmaceutical agent were an issue with Tc-99m-HMPAO [5], but not with the more stable Tc99m Bicisate. Five cases of false positive radionuclide blood flow studies using nondiffusible radiopharmaceutical tracers were reported [6], and another was retracted due to inappropriate interpretation [7]. Several erroneous reports of false-positive brain SPECT using diffusible radiopharmaceutical tracers were likely due to the absence of a lateral view to examine the posterior fossa and brainstem [4, 8], or due to misinterpretation of a spinal reflex [9].

It is unclear what mechanism was in our patient to explain the return of brainstem function. The patient was examined for BD approximately 10 h after the last remaining brainstem reflex disappeared. Arrest of cerebral blood flow occurs when the intracranial pressure rises to or above the mean arterial pressure. This process likely follows a continuum with progressive rostrocaudal brain herniation. Although unlikely, the intracranial pressure in our patient may have decreased with continued management for organ donation purposes, allowing return of intracranial flow and regaining of brainstem function. Alternatively, the cerebral perfusion scan may not have detected residual brainstem viability. We performed our radionuclide scan following the ACR recommendations using diffusible tracers and obtained both planar and SPECT images to better view the brainstem. Another potential confounder was the

possibility of nonconvulsive status epilepticus masking clinically observable brain function. Our patient did not have any electroencephalogram. However, ictal foci would generally appear hypervascular on brain SPECT imaging [10]. The possibility of residual sedative effect seems unlikely as well since the patient had small doses of sedating drugs during the initial management on the field (2 mg lorazepam, 2 mg IV midazolam, 30 mg etomidate, 100 mcg fentanyl, and 200 mg succinylcholine for intubation, and infusion of propofol at rate of 25 mcg/kg/min for 60 min), with no additional doses from admission to the time of BD testing, an interval of 50 h. Unfortunately, the BD testing done on this patient was limited by the absence of apnea testing due to the persistent hemodynamic instability and requirement for multiple vasopressors.

In conclusion, we reaffirm that BD should remain a clinical diagnosis performed by experienced providers. We also reaffirm the importance of performing the apnea test if the patient can be hemodynamically stabilized using vasopressors and/or fluids. However, when the clinical assessment for BD cannot be completed due to inability to perform an apnea test or other key aspects of the clinical examination, an additional waiting period from the time of loss of brainstem function to the initiation of BD testing may be warranted prior to doing ancillary testing, unless demonstration of intracranial pressure greater than or equal to mean arterial pressure for an extended period of time can be done. Moreover, if using nuclear imaging, SPECT imaging in addition to planar imaging is recommended.

Author details

¹ Department of Neurology and Neurosurgery (UH-7134), SUNY Upstate Medical University, 750 East Adams Street, Syracuse, NY 13210, USA. ² Department of Neurology, BU School of Medicine, Boston, MA, USA.

Author Contributions

JGSL, EBS, and DMG were involved in conception and design of the study. JGSL and EBS were involved in acquisition and analysis of data. JGSL, EBS, and DMG were involved in drafting a significant portion of the manuscript and figures. JGSL, EBS, and DMG were involved in revising the manuscript for important intellectual content.

Source of Support

No financial support was obtained for this manuscript.

Compliance with Ethical Standards

Conflict of interest

The authors do not have any conflict of interest to disclose.

Ethical approval

This article does not contain any studies with human participants performed by any of the authors.

Appendix 1: SUNY Upstate Brain Death Checklist



DEATH CERTIFICATION BY NEUROLOGIC CRITERIA FOR ADULT PATIENTS

Patient Name: _____ MR#: _____

Account #: _____ DOB: _____ Date: _____

Adapted from New York State DOH Guideline for Determining Brain Death Dec 2011, pursuant to 10 NYCRR § 400.16 and NY Public Health § 4306.2. Please refer to University Hospital Administrative Policy Manual CM D-12 for further instructions and for Death Certification by Neurologic Criteria in patients 18 years and younger. Additional documentation may be made in patient's medical record if necessary.

Prerequisites for Brain Death Evaluation

Criteria (All items MUST be YES before initiating brain death examination)	YES	NO
1. Patient in coma or unresponsive and cause known: Cause:		
2. An appropriate period of time has passed since the onset of brain insult to exclude possibility of recovery		
3. Clinical or neuroimaging evidence of acute neurologic catastrophe compatible with coma		
4. CNS depressant drug effect absent (Option: waiting period equivalent to 5-half-lives)		
5. Absence of neuromuscular blockade (option: 4/4 twitch on Train of Four monitoring)		
6. Absence of severe acid-base, electrolyte or endocrine abnormality		
7. Core body temperature > 36 degrees C and systolic BP ≥ 100 mmHg (Option: MAP > 65 mmHg)		
8. No spontaneous respiration		

Physician's Signature: _____ Printed Name/Title: _____ Date/Time: _____

A. Brain Death Examination by Attending Physician

Components (If any NO answer, STOP. Patient does NOT meet criteria for brain death)	YES	NO
1. Pupils fixed, nonreactive to light and in midsize or dilated position		
2. Ocular movement by oculoccephalic reflex (DOLL's eye maneuver) testing absent.		
3. Ocular movement by oculovestibular reflex (COLD CALORIC) testing absent **		
4. Corneal reflex absent bilaterally		
5. Pharyngeal (GAG) reflex absent		
6. Tracheal (COUGH) reflex absent with bronchial suctioning		
7. Absent motor response to painful stimuli in all 4 extremities (spinally-mediated reflexes permissible)*		

* if with significant cervical spine injury, consider ancillary testing ** tympanic membrane must be intact

Physician's Signature: _____ Printed Name/Title: _____ Date/Time: _____

B. Apnea Testing

Prerequisites (All items MUST be YES before initiating Apnea Testing)	YES	NO
1. Core temperature ≥ 36 degrees C		
2. Systolic BP ≥ 100 mmHg (treat with vasopressors if low)		
3. Euvolemic (Option: positive fluid balance in previous 6 hours, give fluid boluses or vasopressin)		
4. Normal PO2 (Option: preoxygenate with 100% O2 x 10 min to obtain arterial PO2 ≥ 200mmHg)		
5. Normal PCO2 (Option: arterial PCO2 = 40 ± 5 mmHg, adjust ventilation as necessary) If with severe COPD or morbid obesity, consider confirmatory testing		
6. Absent significant cervical spine injury at or above the level of C5. If with cervical spine injury, consider ancillary testing.		

Physician's Signature: _____ Printed Name/Title: _____ Date/Time: _____

Appendix 2: SPECT Technical Detail

Patient's Name: _____ Account #: _____ MR#: _____

Apnea testing process:

- Deliver 100% O₂ via ventilator for 10 minutes prior to starting the test.
- Draw a baseline arterial blood gas. (Stop the test if baseline PCO₂ ≥ 60mmHg and proceed to confirmatory testing)
- Connect a pulse oximeter and disconnect the ventilator from the patient.
- Deliver 100% oxygen into the trachea via cannula in the ET tube at 6-10LPM.
- Leave the patient off the ventilator for at least 8-10 minutes and observe for respiratory movements.
- **ABORT THE APNEA TESTING** by connecting the patient back to the ventilator in the event that any of the following event occurs: (ABG sample should be sent as soon as the patient is connected back to the ventilator. If PCO₂ <60 mmHg AND the PCO₂ increase was < 20 mmHg from baseline, proceed to confirmatory testing, as the apnea test is INCONCLUSIVE)
 - Hypotension (SBP < 90 mmHg or MAP < 60 mmHg)
 - Malignant cardiac arrhythmia such as ventricular fibrillation or wide complex tachycardias
 - Hypoxemia with Oxygen Saturation < 85% for > 30 seconds
- Draw arterial blood gas after 8-10 minutes and reconnect patient from the ventilator.
- If there is no visible respiratory movement AND if the final PCO₂ ≥ 60mmHg (Option: PCO₂ increase from normal baseline was at least 20 mmHg), then the test is **POSITIVE** and supports the diagnosis of brain death.

Apnea Test Documentation:

Baseline ABG: pH= _____ PO₂= _____ PCO₂= _____ Date: _____ Time: _____

Apnea Test Start Time: _____ Apnea Test End Time: _____

PostTest ABG: pH= _____ PO₂= _____ PCO₂= _____ Date: _____ Time: _____

Respiratory movement observed: YES NO Note: _____

Apnea test: Completed Aborted and confirms does not confirm brain death

Physician's Signature: _____ Printed Name/Title: _____ Date/Time: _____

C. Ancillary Testing (not required unless severe facial/head/neck trauma obscuring clinical exam, chronic retention of CO₂ or other instability makes clinical exam not possible)

Indications for Ancillary testing (Must check at least one indication)	YES	NO
1. Inability to complete ALL Brainstem examination due to cervical or facial injuries.		
2. There is uncertainty with the result of the neurologic examination		
3. Inability to confirm whether the medication effect may be present or not.		
4. Inability to perform or complete APNEA testing due hemodynamic instability or hypoxemia		
5. Inability to perform APNEA Test due to known or suspected cervical spine injuries.		
6. Inability to perform APNEA Testing due to chronic CO ₂ retention (e.g. severe COPD)		

Ancillary Testing Documentation: Test: EEG Cerebral Angiogram Nuclear Brain Scan

Date/Time of Confirmatory test: _____ Name of Attending MD Interpreting test: _____

Interpretation: _____

Physician's Signature: _____ Printed Name/Title: _____ Date/Time: _____

D. Declaration of Death

Attending Physician Certification of Death:

I certify that my neurological examination of the patient and ancillary test report confirms irreversible cessation of function of the brain and brainstem and is consistent with the diagnosis of brain death. Date and Time of Death: _____

Physician's Signature 1: _____ Printed Name/Title: _____ Date/Time: _____

Second Attending Physician Certification of Death (Required for potential Organ Donors):

Certification of Brain Death Evaluation Checklist by the Second Attending Physician (All YES required for certification)	YES	NO
1. Certification of unresponsiveness: I certify that I have reviewed and affirm that ALL the prerequisites for brain death evaluation as outlined in this form were met prior to brain death examination and that the patient was unresponsive.		
2. Certification of absence of brain stem reflexes: I certify that ALL components of brain death examination that can be done as outlined in Part A of this form were done and supports the diagnosis of brain death.		
3. Certification of apnea - Select one: <input type="checkbox"/> I certify that ALL the prerequisites for Apnea Testing as outlined in Part B of this form were met prior to the Apnea Testing and that the results of Apnea testing supports the diagnosis of brain death. <input type="checkbox"/> I affirm that Apnea testing can not be done safely due to the patient's condition		
4. Certification of need for Ancillary Testing - Select one: <input type="checkbox"/> I certify that ancillary testing is not indicated and not necessary for declaration of death <input type="checkbox"/> I certify that ancillary testing is indicated and the result supports the diagnosis of brain death		

Physician's Signature 2: _____ Printed Name/Title: _____ Date/Time: _____

The data were acquired using a triple head gamma camera (Trionix, Triad XLT) equipped with low-energy high-resolution parallel beam collimators in a 128×128 detector element matrix over 360 degree orbits, with 120 views obtained at 3-degree intervals for 30 s per view following a circular orbit with a radius of 218 mm. The photopeak energy setting was at 140 keV with an 18% window. Transaxial images were reconstructed in a 128×128 matrix with attenuation correction and collimator modeling and 3.2-mm cubic voxels using the OSEM algorithm in ten iterations, OS=30, a Butterworth post-filter (order=5, cutoff=1.0 cycle/cm). The reconstructed system resolution was approximately 12 mm full width at half maximum (FWHM). The images were viewed in the usual three orthogonal planes (coronal, sagittal, and transaxial) and as maximum intensity projection objects. Special care was taken to obtain good visualization of the posterior fossa and brainstem.

Publisher's Note

Springer Nature remains neutral with regard to jurisdictional claims in published maps and institutional affiliations.

Published online: 10 March 2020

References

1. Wijdicks EF. Brain death worldwide: accepted fact but no global consensus in diagnostic criteria. *Neurology*. 2002;58(1):20–5.
2. Wijdicks EF, Varelas PN, Gronseth GS, et al. Evidence-based guideline update: determining brain death in adults: report of the quality standards subcommittee of the American academy of neurology. *Neurology*. 2010;74(23):1911–8.
3. American College of Radiology Committee on Practice Parameters and Technical Standards. ACR-SPR practice parameter for the performance of single photon emission computed tomography (SPECT) brain perfusion imaging, including brain death examinations. <https://www.acr.org/-/media/ACR/Files/Practice-Parameters/BrainPerf-SPECT.pdf?la=en> (2016). Accessed 7 Aug 2019.
4. Joffe AR, Lequier L, Cave D. Specificity of radionuclide brain blood flow testing in brain death: case report and review. *J Intensive Care Med*. 2010;25(1):53–64.
5. Brandau W, Schober O, Knapp WH. Determination of brain death with technetium-99m-HMPAO. *J Nucl Med Off Publ Soc Nucl Med*. 1990;31(12):2075–6.
6. Flowers WM Jr, Patel BR. Radionuclide angiography as a confirmatory test for brain death: a review of 229 studies in 219 patients. *South Med J*. 1997;90(11):1091–6.
7. Case Reports in Critical C. Retracted: clinical brain death with false positive radionuclide cerebral perfusion scans. *Case Rep Crit Care*. 2016;2016:2057806.
8. Kramer AH. Ancillary testing in brain death. *Semin Neurol*. 2015;35(2):125–38.
9. Adelstein W. Confirmation of brain death using 99m Tc HM-PAO. *J Neurosci Nurs J Am Assoc Neurosci Nurses*. 1994;26(2):118–20.
10. Grunwald F, Menzel C, Pavics L, et al. Ictal and interictal brain SPECT imaging in epilepsy using technetium-99m-ECD. *J Nucl Med Off Publ Soc Nucl Med*. 1994;35(12):1896–901.