



Contents lists available at ScienceDirect

Journal of Clinical Neuroscience

journal homepage: [www.elsevier.com/locate/jocn](http://www.elsevier.com/locate/jocn)

Review article

## New-onset tic disorder following circumscribed brain injury

Aaron de Souza

Department of Medicine, Launceston General Hospital, 274-280 Charles Street, Launceston, TAS 7250, Australia

### ARTICLE INFO

#### Article history:

Received 13 December 2019

Accepted 8 March 2020

Available online xxxx

#### Keywords:

Tic disorder

Traumatic brain injury

Tourette syndrome

### ABSTRACT

Adult-onset tics represent either a secondary tic disorder (“tourettism”) or a late presentation of childhood tics, which may have been previously unrecognised. Head trauma has been recognised as an infrequent cause of adult-onset tic disorder, which exhibits variable temporal relationship to the inciting injury and response to therapy. We present a patient who presented with late-onset tics seven years after a circumscribed brain injury, responding well to antidopaminergic treatment. A review of all the previously reported cases of post-traumatic tic disorder is provided. Our patient is unusual in that the injury presumed to be responsible for the development of tics was of a very focal nature, akin to previously described tic disorder following vascular insults. We discuss the rare occurrence of tourettism after such focal brain lesions and analyse the insights this provides into the anatomical substrates underlying tic disorders.

© 2020 Published by Elsevier Ltd.

### 1. Introduction

Tics are involuntary non-rhythmic, stereotyped repetitive movements with a premonitory sensation of an extreme tension discomfort or other sensory phenomena. The person can suppress the movements temporarily, but this leads to an escalating urge to execute the tic. Contractions of isolated muscles produce motor tics, most often in the face and head with blinking, grimacing, arching of eye brows, sniffing or shrugging. Involvement of the respiratory and pharyngeal muscles produces grunts, called vocal or phonic tics. Tics differ from habits and mannerisms in their pervasiveness and the degree of psychic tension. Gilles de la Tourette syndrome is a neuropsychiatric disorder with motor and phonic tics along with significant behavioural comorbidities such as attention deficit hyperactivity disorder (ADHD) and obsessive-compulsive disorder (OCD) that has an onset typically in middle to late childhood. Tics starting in adult life are infrequent and are either a recurrence of childhood tics [1,2] or secondary to neurological disorders (usually affecting the basal ganglia) like Huntington's disease, neuroacanthocytosis, stroke, encephalitis, withdrawal of drugs (specifically neuroleptics), cerebral tumour, or TBI [3–9]. Such adult-onset Tourette-like disorders have been referred to as *tourettism* or *secondary tics* [5,9].

Traumatic brain injury (TBI) is not uncommonly complicated by movement disorders, either transient or persistent, and as many as 22.6% of patient with severe TBI can manifest a movement disorder, attributed to various factors including direct damage to the

basal ganglia and their connections, delayed effects of haemosiderin deposits, and aberrant neuronal plasticity [3,10–12]. While dystonia, tremor and chorea are well-recognised sequelae to craniocerebral trauma, there are only a few case reports of tic disorder attributed to TBI. Considerably fewer than 1% of head injury survivors develop tics [12,13]. We present a patient who suffered a circumscribed injury to the left parietal region with a nail gun at age 28 years and presented with a new-onset tic disorder seven years later. The previously reported cases of post-traumatic secondary tic disorder are reviewed and possible pathogenetic mechanisms and therapeutic options are discussed.

### 2. Case report

A 28-year old carpenter suffered a head injury from a nail gun, with a nail penetrating his skull and lodging in the paramedian left parietal lobe. Following surgical extraction, he was left with numbness of the right lower limb and trunk to the axilla. Seven years later, he presented with episodic head turning to the right. These movements were felt to be epileptic and he was prescribed sodium valproate, with no observed benefit. Six years after onset repetitive involuntary vocalisation of the words “me” and “boo”, in addition to obscenities, began to be associated with these head movements. This could occur nearly continuously for hours on end. He could “feel it coming on”, and while the vocalisation was partially suppressible, he noticed a build-up of the urge to vocalise after attempting to stop it. A standard EEG captured typical multiple events, with head turning to the right and vocalisations. Aside from motion artefact during head turn and EMG artefact when

E-mail address: [aaron.de.souza@ths.tas.gov.au](mailto:aaron.de.souza@ths.tas.gov.au)<https://doi.org/10.1016/j.jocn.2020.03.009>

0967-5868/© 2020 Published by Elsevier Ltd.

vocalising, no abnormal activity was observed (Fig. 1, A). An MRI of the brain showed left parietal encephalomalacia, in addition to subcortical white matter lesions attributed to small vessel cerebrovascular disease (Fig. 1, B). No family history of tics or behavioural abnormalities was present, and the patient denied any involuntary movements or behavioural symptoms in the past. Tics responded well to risperidone 0.5 mg BD, but this medication unfortunately led to significant weight gain.

### 3. Discussion

In contrast to childhood- or adolescent-onset tics, tics presenting in adulthood are rare and are usually in the context of touretism or secondary tic disorders [1]. True *de novo* late-onset tics must be differentiated from a pre-existing unrecognized tic disorder beginning in childhood [9]. Post-traumatic tics starting within weeks after injury, occur after mild TBI and could be due to aggravation of pre-existing mild or undiagnosed tics [1,3]. In adults presenting with a tic disorder, it is often assumed that the patients

cannot remember having experienced childhood tics, and establishing that an adult patient with apparent new onset tics did not have tics during childhood can rarely be done with certainty because some patients are unaware of their tics, and reliable observers who knew the patient as a child may not be available [1,14]. A diagnosis of *de novo* post-traumatic tics would require documented trauma to the head associated with brain damage reflected by loss of consciousness, dizziness, confusion, posttraumatic amnesia or other neurologic deficits with a temporal relationship to tic onset; absence of tics prior to TBI; and presence of other sequelae of trauma. Age at onset, lack of fluctuation in tic phenomenology and location, and the absence of a family history of tics argue against Tourette syndrome underlying the tic disorder [10,15].

The Table 1 lists cases of post-traumatic tic disorder reported to date. Patients ranged in age from 3 to 47 years at the time of head trauma, with a mean of 23.4 years. TBI ranged from mild (no loss of consciousness or only brief unresponsiveness) to severe (loss of consciousness >30 min). Trauma involved deceleration injuries in nearly all cases. Coprolalia was seen in only two patients, and three

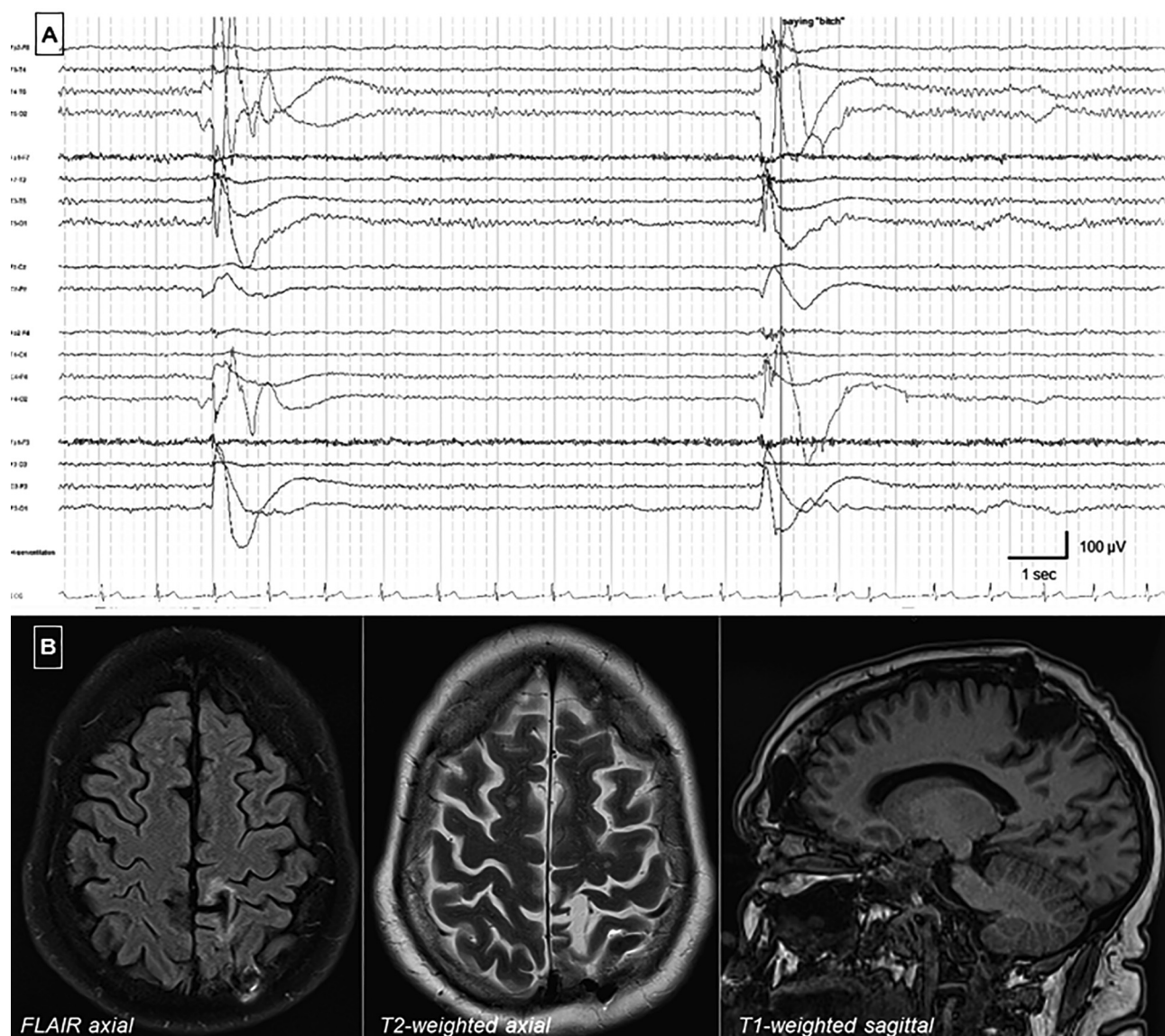


Fig. 1. (A) EEG during motor and vocal tic, showing motion artefact with no epileptiform activity. (B) MRI of the brain performed at onset of tic disorder, seven years after head injury, showing focal encephalomalacia in the left parietal lobe.

**Table 1**

Previously reported cases of post-traumatic tic disorder. MVA: motor vehicular accident, LoC: loss of consciousness.

No	Ref	Year	Age at injury (y)/sex	Injury	Latency to tic onset	Clinical observations	Previous tic/OCD	Family history	Imaging/relevant investigations	Treatment	Outcome
1	16	1969	3/M	MVA, depressed right temporal fracture	“shortly thereafter”	Eye tics, rapid twitching in face and shoulders, worse when tired, irritated, tense. At age 12: anxiety, worsening motor movements with opisthotonos, cheek or tongue bites, involuntary vocalisation	–	Two paternal uncles with facial tics	EEG “non-specific, sporadic activity of suspiciously paroxysmal nature”, mainly left temporal	Phenytoin, diazepam, barbiturates	Attacks disappeared
2	38	1982	18/M	Struck by steel girder, head strike, LoC few minutes, confused for 2 weeks	“Couple of months”	Variable face, eyelid, neck, limb twitching, grunting, sniffing, throat clearing, snorting, whistling. Partially suppressible with rebound exacerbation post-suppression	None	–	–	Haloperidol, clonazepam	Improved, benefit limited by adverse effects
3	17	1989	25/M	MVA, fractured right femur, numerous lacerations, cerebral concussion with LoC 45 min	2–3 weeks	Involuntary, brief, multiple, repetitive, stereotyped movements in periocular muscles, face, head, neck, right shoulder. Neck rotation to right, forward head thrusting, anterior rotation right shoulder exacerbated by anxiety and ameliorated by relaxation and concentration	–	–	CT brain, EEG negative	Lorazepam, haloperidol, clonidine	No benefit
4	18	1990	33/M	Fall from third storey, hit shoulder and head, no LoC. Neck, left shoulder, knee pain	2 weeks	Brief, small-moderate amplitude head and neck movements. Could transiently suppress	Mild chin twitching in high school	–	CT brain negative	Haloperidol pimozide	Good
5	39	1994	35/M	MVA, injury to head, neck, back, no LoC. Pain in head, neck, low back	2 weeks	Moderate-large amplitude, rapid, irregular twitching of platysma, worse when anxious, partially suppressible	–	–	–	Clonidine, diazepam	Partial benefit, sedation limited treatment
6	9	1997	21/M	MVA, LoC for a few minutes, no injuries. Dull neck and back pain	5 months	Back arching, shoulder shrugging, eye twitching, quick jerk-like neck turning/tilting providing relief of local tension. Distractible, suppressible with build-up of neck tension and post-suppression exacerbation of movements	Hyperactive, distractible, poor attention in school. Compulsive/ritualistic behaviours	–	CT brain, MRI spine normal	Clonazepam clonidine	Poor benefit. Sedation
7	10	1997	47/M	MVA, brief LoC, headache, neck and left-sided facial and limb pain, paraesthesia and numbness	4 days	Left facial/neck twitching, eye blinking, head bobbing worse when tired, ameliorated by relaxation and concentration; grunting, sniffing; distractible, irritable, poor impulse control. Transiently suppressible. Nystagmus on right lateral gaze, gait ataxia, dysarthria, hypoaesthesia left side. Startle response to noise	Sniffing	–	CT brain after injury normal. EEG, MRI brain unremarkable	oxycodone, codeine, acetaminophen, diazepam, flurazepam, promethazine, meperidine, clonazepam	No benefit
8	10	1997	23/M	MVA, no LoC, dizzy, right neck and shoulder pain	1 day	Head jerking/rotation to right, facial grimacing, contraction of platysma and anterior neck muscles, lip smacking worse with fatigue. Transiently suppressible with post-suppression exacerbation of movements	–	–	CT brain cavum septum pellucidum. MRI brain and cervical spine unremarkable	baclofen, cyclobenzaprine, carbamazepine, haloperidol, buspirone, trihexyphenidyl clonazepam. Tetrabenazine, botulinum toxin	Better with tetrabenazine and botulinum toxin. Sedation noted with tetrabenazine. No benefit with other meds

(continued on next page)

Table 1 (continued)

No	Ref	Year	Age at injury (y)/sex	Injury	Latency to tic onset	Clinical observations	Previous tic/OCD	Family history	Imaging/relevant investigations	Treatment	Outcome
9	10	1997	21 y (first accident); 26 y (second accident)/M	MVA, LoC for 3 weeks. MVA, LoC for 2 weeks	Months after second MVA	Picking nose, rubbing nose/eyes, sniffing, leg twitching, hand wringing. Obsessive and ritualistic behaviours. Memory and attentional deficits, ataxic gait	-	Brother: poor impulse control. Son: distractible	MRI cerebral atrophy with panventricular dilatation and widened convexity sulci and cerebellar fissures, bilateral subcortical and periventricular leukoencephalopathy	Fluoxetine	Depression better
10	4	2002	7½/F	MVA, LoC 7 days, residual right hemiparesis, visual dysfunction, dysarthria, cognitive and behavioural disturbances	15 months	Blinking, jerking shoulders and arms, flexing trunk, grunting, tongue clicks, coprolalia, echolalia, echopraxia; worse with anxiety or fatigue, remitted in sleep; partially suppressible			CT brain 6 h after injury haemorrhages within the left lateral ventricle and left internal capsule, diffuse cerebral oedema. EEG left frontotemporal slow wave activity without spiking. MRI infarct left putamen, globus pallidus, caudate head and internal capsule, left frontoparietal cortex thinned	Haloperidol	Good. Cognitive and behavioural sequelae due to head injury
11	3	2011	19/M	MVA, lung contusions, pelvic and multiple rib fractures, ruptured bladder and spleen. LoC > 1 week. Seizures. Residual cognitive deficits, ataxia, impulsivity, left hemiparesis	1 year	Stereotypical eyelid closure, facial grimacing, sniffing, clenching fists, grunting, throat clearing worse with fatigue, stress and anxiety. Distractible and transiently suppressible with build-up of an urge and anxiety			CT brain after injury: haemorrhages in corpus callosum and right internal capsule, petechial haemorrhage over both frontal and temporal lobes. MRI: brain atrophy, right basal ganglia show foci of increased T2 signal. Multiple low-signal foci on gradient echo in corpus callosum, right putamen, cerebral convexities	None	Spontaneous reduction in frequency and severity over 12 months
12	15	2013	?/M	MVA, multiple long bone and pelvic fractures, LoC for 1 month	2 months	Premonitory discomfort followed by repetitive, stereotypical right shoulder flexion, right elbow and wrist extension, rotatory shoulder movements, truncal isometric contractions, platysma contractions, anterior neck flexion, left torticollis, blepharospasm, sniffing, clearing throat. Partially suppressible with rebound post-suppression exacerbation			CT brain unremarkable	haloperidol, pimozone, trazodone, clonidine, sertraline, levodopa baclofen, tetrabenazine	moderate improvement with tetrabenazine
13		2019	28/M	Nail penetrated skull. Residual right lower limb/trunk numbness	7 years	Episodic involuntary head turning to right, repetitive involuntary vocalisations, coprolalia. Premonitory sensation, build-up of urge when attempting suppression	-		EEG: normal. Clinical events did not show EEG correlate. MRI brain small area of encephalomalacia left cerebral vertex, moderate small vessel ischaemic changes in white matter	Valproate, risperidone	No benefit with valproate. Tics responded to risperidone, weight gain noted



patients had behavioural abnormalities. The first patient reported in the English literature, was described by Eriksson and Persson in 1969 as having hyperkinetic motor movements with opisthotonos, cheek or tongue bites, and involuntary vocalisation with an abnormal EEG showing left temporal paroxysmal activity. These movements subsided after treatment with a combination of phenytoin, barbiturates and diazepam [16]. Whether seizures can be confidently excluded remains questionable. Moreover, a causal relationship between the TBI and subsequent development of tics is difficult to establish because of the young age at onset of the motor tics [10]. Subsequent reports are more convincing and may be broadly classified into two categories. Patients with mild TBI manifested tics beginning one day to five months after head trauma. These patients often have a history of subtle tics or behavioural features of Tourette syndrome (or a positive family history of these symptoms), and in general responded well to medical therapy. In contrast, tics beginning after severe TBI, with abnormal brain imaging or delayed onset of tics (months after trauma) did not respond well to treatment.

TBI may precipitate tics in a genetically predisposed individual with clinical features ranging from only simple motor tics to the concomitant behavioural features of Tourette's syndrome including OCD. This syndrome occurs 2 weeks to 3 months after mild to moderate TBI, is associated with normal brain imaging, and is likely related to altered neuronal receptor sensitivity following trauma, which leads to decompensation of a precariously balanced system in a person with a genetic or behavioural predisposition to tics. Given the mild nature of the inducing trauma in some cases, even subtle exogenously induced neurophysiologic or neuroanatomic alterations may suffice to precipitate a tic disorder in a person with a pre-existing nonpenetrant propensity for Tourette's syndrome [3,9,15,17,18]. Indeed, tics have been reported to be precipitated by peripheral trauma, as in the case reported by Erer and Jankovic [19] where motor tics began a fortnight after trauma to the left shoulder, initially localised to this area and later spreading to involve neck and hand. A marked increase in anxiety following TBI has also been proposed to exacerbate pre-existing tics [18]. However, as both Tourette syndrome and TBI are relatively common conditions, if brain injury was merely the impetus for developing tourettism in genetically predisposed persons, one would expect this combination to be a lot more common than a few case reports by virtue of chance alone [10].

On the other hand, tics with onset delayed by several months after TBI is seen in patients with severe TBI [3]. Analogous to other movement disorders that manifest months or years after TBI, these delayed tics can be attributed to aberrant neuronal regeneration or to a delayed effect of TBI on neural circuits connecting the frontal cortex, basal ganglia and thalamus [3,11]. As in the case of post-traumatic epilepsy in which the seizures may not develop for many months or years after the head injury, late development of neuronal or synaptic rewiring or aberrant neuronal pathways could also explain the delayed appearance of tics following TBI. The infrequent occurrence of apparent spontaneous remission or improvement could possibly be explained as a "reset" of any initial impairment of neurotransmitter function or "balance" [4].

Our patient, however, differs from previously reported patients with post-traumatic tic disorders in that he sustained a very circumscribed head injury, targeting the left parietal lobe with almost surgical precision. As one would expect, this resulted in contralateral crural and truncal hypoaesthesia immediately after extraction of the offending object. The later development of a tic disorder may be due to damage to a specific tract in this location, rather than a generic, non-specific, fronto-striatal circuit impairment as posited in other post traumatic tic disorders [15]. The semiology of his motor tic, with relatively stereotypical contralateral head turning, prompted consideration of focal left frontal lobe dysfunction, but

the EEG unequivocally excluded seizures as a cause of this. The typical phenomenology with an abrupt, jerk-like component and vocalisation, the premonitory sensation, and suppressibility all argue in favour of this movement representing a tic. This is akin to the rare cases of tic disorder following focal cerebral infarction or haemorrhage [20,21]. A 71-year old man developed a simple phonic tic three weeks after sustaining an infarct in the tail of the left caudate nucleus, partially suppressible with post-suppression rebound and worsening with stress. Single photon emission computed tomography (SPECT) highlighted abnormal patterns of blood flow and metabolism in the left basal ganglia, and in the motor cortex of the left frontal lobe. The tic proved poorly responsive to treatment with pimozide [20]. Yochelson and David reported the case of a 16-year old boy who developed complex motor and vocal tics (repeated head turning to the left, briefly uttering "yeah" particularly when stressed, with a premonitory urge and partial suppressibility) following haemorrhage into a left frontal arteriovenous malformation. Over six months, the tics responded by 80% to clonidine therapy [21]. Kwak and Jankovic [8] had previously reported two boys who sustained right hemispheric strokes, both at eight years of age, with subsequent development of tics, hemi-dystonia and behavioural symptoms reminiscent of Tourette's syndrome.

These patients provide interesting insights into the possible biological and anatomical substrate underlying tic disorders. Tics are thought to be related to basal ganglia dysfunction, based on histopathologic and immunological data as well as biochemical studies involving dopamine uptake and dynorphin immunoreactivity [22–27]. Mejia and Jankovic [5] reported basal ganglia lesions in 9% of subjects with secondary tics. MRI of subjects with Tourette syndrome had shown abnormalities in the basal ganglia, corpus callosum and frontal white matter, including a reduction in the volumes of the striatum, specifically the caudate nuclei, or of the left basal ganglia, and loss of the normal asymmetry of the basal ganglia [3,28–32]. In fact, reduced caudate nucleus volumes might be a good candidate marker for a trait abnormality in the structure of the basal ganglia in people with Tourette syndrome compared with healthy subjects. It has also been shown that caudate volume in children with Tourette syndrome can predict symptom severity of tic and obsessive-compulsive symptoms in early adulthood [30,33].

However, many of the patients listed in the Table 1 had no imaging evidence of basal ganglia dysfunction, and rather than direct lesions of these nuclei, abnormalities in the corticostriatal-thalamocortical and limbic-striatothalamic neural circuits connecting the frontal lobes to the deep grey matter have been implicated in the pathogenesis of tics and associated behavioural abnormalities [3,21,24–29,31,34,35]. These circuits are also vulnerable to secondary complications of trauma, including cerebral infection, global or focal hypoperfusion, inflammation, and drug side effects. The process of recovery from TBI may lead to this network developing abnormal connections, causing delayed development of aberrant movements [7]. SPECT in patients with Tourette's syndrome has revealed hypoperfusion in the right or left basal ganglia, including within the caudate nucleus, cingulate gyrus, and dorsolateral prefrontal cortex [34,36]. Positron emission tomography (PET) has variably demonstrated increased metabolism within the orbitofrontal and premotor cortices, post-rolandic sensory association areas and the putamen during periods of active cognitive and behavioural Tourette symptoms, with decreased metabolic activity in orbital, frontal, and superior insular cortices, mesial temporal regions, and the striatum [37]. The relatively posterior location of the causative lesion in our patient, although consistent with previously reported abnormalities in the sensory association cortex, expands the list of potential anatomic localisations for tic disorders.

In conclusion, TBI may mechanically disrupt deep motor nuclei including the basal ganglia and thalamus, or the white matter tracts associated with these structures. Tics may reflect the release of cortical-subcortical circuits involving the frontal cortex and anterior striatum, but abnormalities in multiple other brain locations have been reported in patients with tics. Our patient, and other similar patients reported previously, demonstrate that circumscribed brain lesions – in the parietal lobes, frontal lobes or basal ganglia – can produce delayed *de novo* tic disorders, likely through disruption of relevant neural circuitry. Further studies, possibly using tractography, could shed more light on specific patterns of disconnection that may trigger the development of post-traumatic tics.

### Conflict of interest

There is no objection to the above details being published. The authors affirm that they have no conflicts of interest. No funding sources or financial disclosures apply.

No person who had contributed substantially to the production of this manuscript had been excluded from authorship. Persons who have contributed partially have been acknowledged in the manuscript. The author affirms that there is no conflict of interest to declare.

### Appendix A. Supplementary data

Supplementary data to this article can be found online at <https://doi.org/10.1016/j.jocn.2020.03.009>.

### References

- [1] Chouinard S, Ford B. Adult onset tic disorders. *J Neurol Neurosurg Psychiatry* 2000;68:738–43.
- [2] Goetz CG, Tanner CM, Stebbins GT, et al. Adult tics in Gilles de la Tourette's syndrome: description and risk factors. *Neurol* 1992;42:784–8.
- [3] Ranjan N, Nair KPS, Romanoski C, Singh R, Venketeswara G. Tics after traumatic brain injury. *Brain Inj* 2011;25(6):629–33.
- [4] Majumdar A, Appleton RE. Delayed and severe but transient Tourette syndrome after head injury. *Pediatr Neurol* 2002;27:314–7.
- [5] Mejia NI, Jankovic J. Secondary tics and tourettism. *Revista Brasileira de Psiquiatria* 2005;27:11–7.
- [6] Jankovic J. Tourette's syndrome. *N Engl J Med* 2001;345:1184–92.
- [7] O'Suilleabhain P, Dewey RB. Movement disorders after head injury: diagnosis and management. *J Head Trauma Rehabil* 2004;19(4):305–13.
- [8] Kwak CH, Jankovic J. Tourettism and dystonia after subcortical stroke. *Mov Disord* 2002;17(4):821–5.
- [9] Kumar R, Lang AE. Secondary tic disorders. *Neurol Clin N Am* 1997;15(2):309–31.
- [10] Krauss JK, Jankovic J. Tics secondary to craniocerebral trauma. *Mov Disord* 1997;12:776–82.
- [11] Krauss JK, Jankovic J. Head injury and posttraumatic movement disorders. *Neurosurgery* 2002;50:927–40.
- [12] Krauss JK, Trankle R, Kopp KH. Post-traumatic movement disorders in survivors of severe head injury. *Neurology* 1996;47(6):1488–92.
- [13] Krauss JK, Trankle R, Kopp KH. Posttraumatic movement disorders after moderate or mild head injury. *Mov Disord* 1997;12(3):428–31.
- [14] Jankovic J. Phenomenology and classification of tics. *Neurol Clin* 1997;15:267–75.
- [15] Pouloupoulos M, Hajjar M. Post-traumatic tics and tetrabenazine treatment: a blinded video assessment. *BMJ Case Rep* 2013. <https://doi.org/10.1136/bcr-2013-201676>.
- [16] Eriksson B, Persson T. Gilles de la Tourette's syndrome: two cases with an organic brain injury. *Br J Psychiatry* 1969;115:351–3.
- [17] Singer C, Sanchez-Ramos J, Weiner WJ. A case of post-traumatic tic disorder. *Mov Disord* 1989;4(4):342–4.
- [18] Siemers E, Pascuzzi R. Posttraumatic Tic disorder. *Mov Disord* 1990;5(2):183.
- [19] Erer S, Jankovic J. Adult onset tics after peripheral injury. *Parkinsonism Relat Dis* 2008;14:75–6.
- [20] Gomis M, Puente V, Pont-Sunyer C, Oliveras C, Roquer J. Adult onset simple phonic tic after caudate stroke. *Mov Disord* 2008;23(5):765–6.
- [21] Yochelson MR, David RG. New-onset tic disorder following acute haemorrhage of an arteriovenous malformation. *J Child Neurol* 2000;15(11):769–71.
- [22] Jankovic J. Tourette's syndrome: phenomenology, pathophysiology, genetics, epidemiology, and treatment. *Curr Neurol* 1993;13:209–27.
- [23] Singer HS, Hahn IH, Moran TH. Abnormal dopamine uptake sites in postmortem striatum from patients with Tourette syndrome. *Ann Neurol* 1991;30:558–62.
- [24] Baumgardner TL, Singer HS, Denckla MB, et al. Corpus callosum morphology in children with Tourette syndrome and attention deficit hyperactivity disorder. *Neurology* 1996;47:477–82.
- [25] Haber SN, Kowall NW, Vonsattel JP, Bird Edward D, Richardson EP. Gilles de la Tourette syndrome. A post mortem neuropathological and immunohistochemical study. *J Neurol Sci* 1986;75:225–41.
- [26] Weeks RA, Turjanski N, Brooks DJ. Tourette syndrome: a disorder of cingulate and orbito-frontal function?. *Q J Med* 1996;89:401–8.
- [27] Singer H. Neurobiology of Tourette syndrome. *Neurol Clin N Am* 1997;15:357–79.
- [28] Berardelli A, Curra A, Fabbrini G, Gilio F, Manfredi M. Pathophysiology of tics and Tourette syndrome. *J Neurol* 2003;250:781–7.
- [29] Albin RL, Mink JW. Recent advances in Tourette syndrome research. *Trends Neurosci* 2006;29:175–82.
- [30] Bloch MH, Leckman JF, Zhu H, Peterson BS. Caudate volumes in childhood predict symptom severity in adults with Tourette syndrome. *Neurology* 2005;65:1253–8.
- [31] Peterson BS. Neuroimaging studies of Tourette syndrome: a decade of progress. In: Cohen DJ, Jankovich J, Goetz CG, editors. *Tourette syndrome*. Vol. 85. *Advances in neurology*. Philadelphia: Lippincott Williams & Wilkins; 2001. p. 179–96.
- [32] Leckman JF, Bradley SP, Pauls DL, Cohen DJ. Tic disorders. *Psychiatr Clin North Am* 1997;20:839–61.
- [33] Peterson BS, Thomas P, Kane MJ, et al. Basal Ganglia volumes in patients with Gilles de la Tourette syndrome. *Arch Gen Psychiatry* 2003;60:415–24.
- [34] Eidelberg D, Moeller JR, Antonini A, et al. The metabolic anatomy of Tourette's syndrome. *Neurology* 1997;48:927–34.
- [35] Stern E, Silbersweig DA, Chee KY, et al. A functional neuroanatomy of tics in Tourette syndrome. *Arch Gen Psychiatry* 2000;57:741–8.
- [36] Moriarty J, Costa DC, Schmitz B, Trimble MR, Ell PJ, Robertson MM. Brain perfusion abnormalities in Gilles de la Tourette syndrome. *Br J Psychiatry* 1995;167:249–54.
- [37] Kurlan RM. Tourette's syndrome. In: Watts RL, Koller WC, editors. *Movement disorders: neurologic principles and practice*. New York: McGraw-Hill; 1997. p. 569–75.
- [38] Fahn S. A case of post-traumatic tic syndrome. In: Friedhoff AJ, Chase TN, editors. *Gilles de la Tourette syndrome*. New York: Raven Press; 1982. p. 349–50.
- [39] Gaul JJ. Posttraumatic tic disorder. *Mov Disord* 1994;9(1):121.