

Short communication

Vaccination management in an asymptomatic child with a novel *SCN1A* variant and family history of status epilepticus following vaccination: A case report on a potential new direction in personalised medicine



Lucy Deng^{a,b,*}, Alan Ma^{b,c}, Nicholas Wood^{a,b}, Simone Ardern-Holmes^{b,d}

^a National Centre for Immunisation Research and Surveillance, Children's Hospital at Westmead, Sydney, Australia

^b The University of Sydney Children's Hospital Westmead Clinical School, Sydney, Australia

^c Department of Clinical Genetics, Children's Hospital Westmead, Sydney, Australia

^d Department of Neurology and Neurosurgery, Children's Hospital Westmead, Sydney, Australia

ARTICLE INFO

Keywords:

SCN1A
Clinical epilepsy
Status epilepticus
Vaccination
Case report

ABSTRACT

Purpose: *SCN1A* variants cause a spectrum of epilepsy syndromes from Dravet Syndrome, a severe epileptic encephalopathy of early infancy to the milder disorder of genetic epilepsy with febrile seizures plus (GEFS+). These genetic epilepsies are associated with increased risk of poor outcome including complications of status epilepticus and early mortality. Individualised management of young children known to be at increased risk should be considered, such as around vaccination management.

Methods: We describe two siblings with a novel pathogenic *SCN1A* variant, their management and clinical outcomes following routine childhood vaccinations.

Results: The index case who had a family history of epilepsy of unknown genetic aetiology, died from hypoxic ischemic encephalopathy following his 12-month vaccinations, in the context of status epilepticus and enterovirus 71 infection. The sibling of the index case with the same *SCN1A* variant was subsequently managed with prophylactic regular sodium valproate and additional clobazam post vaccination to reduce the risk of seizure. She has successfully completed the childhood immunisations to 18 months with no seizures and normal neurodevelopmental progress.

Conclusion: As the aetiology of genetic epilepsies is increasingly known in early childhood, opportunities to personalise care, minimise risks and optimise outcomes are changing. Further research is needed on the risks and benefits of symptomatic and preventative management of seizures around vaccinations in young children with genetic epilepsies.

1. Introduction

Pathogenic variants in *SCN1A*, a sodium channel alpha-1 subunit gene, cause a range of epilepsy syndromes from generalised epilepsy with febrile seizures plus (GEFS+) to the more severe developmental and epileptic encephalopathy, Dravet Syndrome. [1] Approximately 80% of children with Dravet syndrome have a *SCN1A* variant, of which 95

% are de novo variants. [2] Those with familial variants often have the milder phenotype of GEFS+ and generally follow an autosomal dominant inheritance pattern with some showing reduced penetrance [3].

Vaccinations have been implicated in triggering an earlier onset of seizures in children with underlying genetic epilepsy, including *SCN1A*-related Dravet syndrome. [4] Here, we report of two siblings with a

Abbreviations: *SCN1A*, sodium channel alpha-1 subunit gene; GEFS+, generalised epilepsy with febrile seizures plus; FS, febrile seizure; DTPa-Hib-HepB-IPV, diphtheria, tetanus, acellular pertussis, Haemophilus influenzae type b, hepatitis B and inactivated polio combination vaccine; PCV13, 13-valent pneumococcal conjugate vaccine; Hib-MenC, Haemophilus influenzae type b and meningococcal C conjugate vaccine; MMR, measles-mumps-rubella vaccine; CSF, cerebrospinal fluid; CT, computer tomography; EEG, electroencephalography; MRI, magnetic resonance imaging; MRA, magnetic resonance angiogram; SUDEP, sudden unexpected death in epilepsy; 4vMenCV, quadrivalent (A, C, W, Y) meningococcal conjugate vaccine; DTPa, diphtheria, tetanus and acellular pertussis combination vaccine; Hib, Haemophilus influenzae type b vaccine; VZV, varicella zoster virus vaccine; CNS, central nervous system

* Corresponding author at: National Centre for Immunisation Research and Surveillance The Children's Hospital at Westmead, Locked Bag 4001, Westmead, NSW, 2145, Australia.

E-mail address: lucy.deng@health.nsw.gov.au (L. Deng).

<https://doi.org/10.1016/j.seizure.2020.03.005>

Received 10 December 2019; Received in revised form 24 February 2020; Accepted 10 March 2020

1059-1311/ Crown Copyright © 2020 Published by Elsevier Ltd on behalf of British Epilepsy Association. All rights reserved.

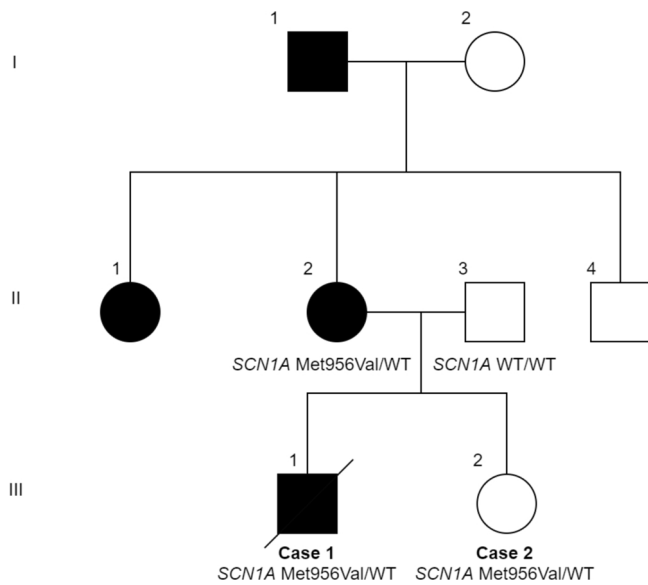


Fig. 1. Pedigree of family.

novel *SCN1A* variant, their clinical management and outcomes, with focus on their vaccinations.

2. Case 1

The first patient (index case, III:1 in Figure) was a 12-month-old boy, born at full-term via spontaneous vaginal delivery to non-consanguineous Caucasian parents (first pregnancy via in-vitro fertilisation).

His mother (II:2) had epilepsy from infancy, with her first febrile seizure (FS) before 12 months old. She progressed to have both febrile and afebrile bilateral tonic clonic seizures, but no focal seizures or status epilepticus. Her seizures were managed with sodium valproate only. Seizure frequency decreased from once every two months from infancy to puberty, to being seizure free for 4 years before ceasing medication for 5 years before the patient's birth. There was no significant neurodevelopmental impact from the seizures, and she completed high school studies with no assistance. There was a history of epilepsy in her older sister (II:1) and her father's family (I:1). No family members had prolonged seizures or developmental concerns. (Fig. 1).

The patient was a healthy infant with normal growth and development and no significant medical history aside from omphalitis as a neonate. He received his first three sets of infant vaccinations (DTPa-Hib-HepB-IPV, PCV13 and rotavirus vaccines at 6 weeks and 4 months and DTPa-Hib-HepB-IPV and PCV13 at 6 months) with no adverse events following immunisation.

At 12 months old, he had a mild febrile illness with rhinorrhoea lasting 1–2 weeks and had been afebrile for 3–4 days at the time of Hib-MenC and MMR vaccinations. Approximately 27 h later, his first seizure occurred. The child's mother saw him sitting up in bed on the baby video monitor, and went into the room to find him staring, unresponsive with lip smacking, followed by bilateral tonic clonic movements. Fever to 38.5 °C was recorded on arrival to emergency. Four doses of midazolam were given before status epilepticus terminated at approximately 40 min. He went into cardiopulmonary arrest during intubation and had 40 min of down time before return of spontaneous circulation on an adrenalin infusion. A loading dose of levetiracetam (30 mg/kg) was given and he was transferred to paediatric intensive care unit on morphine and adrenaline infusion. Antibiotics were commenced, CSF collection was deferred. CT brain showed severe global hypoxic ischemic brain injury with cerebral oedema. The admission was complicated by pulmonary oedema, secondary pneumonia,

diabetes insipidus, hyperglycaemia, hyperthermia and hypertension. EEG showed electrocerebral silence, and MRI re-demonstrated extensive changes with cerebellar tonsillar herniation and absence of flow in the intracranial arteries on MRA consistent with brain death; medical support was withdrawn, and he died.

Autopsy found severe cerebral oedema with diffuse hypoxic ischemic encephalopathy changes and cerebellar tonsillar herniation. There was also extensive bronchopneumonia. Enterovirus 71 was found on tracheal and rectal swab. There were no signs of meningitis or encephalitis on neuropathological exam of brain and spinal cord.

Genomic testing was not performed at the time of autopsy. Instead, the mother was referred for genetic review during her subsequent pregnancy (Case 2). Whole exome sequencing was arranged on a stored liver-derived DNA sample from Case 1, focussing on a panel of SUDEP (sudden unexpected death in epilepsy), long QT syndrome and hypoventilation-associated genes.

The detected heterozygous missense variant in *SCN1A* (NM_001165963.1: c.2866A > G;p.(Met956Val)) was novel and classified as likely pathogenic by American College of Medical Genetics guidelines (Class 4; PM2, PM5, PP2, PP3). [5] While this was a novel amino acid change, other pathogenic missense changes affecting the same residue, including p.Met956Thr, have been reported where in vitro studies demonstrate reduced cell surface *SCN1A* expression, highlighting the functional importance of this particular highly conserved methionine. [6,7] The absence of variants in this position in population databases including Genome Aggregation Database (gnomAD) [8] and in silico predictions support this missense variant as being likely pathogenic. This variant was also subsequently found in the mother.

3. Case 2

The second patient (III:2), is the younger sister of the index case, born 12 months after the index case's death. Given the history of vaccine-proximate status epilepticus in Case 1, though genetic results were unknown then, she was reviewed by an immunisation specialist and a neurologist prior to her vaccinations. She was admitted for 6-week and 4-month vaccinations (DTPa-Hib-IPV-HepB, PCV13 and rotavirus vaccine) and given prophylactic paracetamol. There were no adverse events.

She was also reviewed by clinical genetics soon after birth. The parents were counselled on predictive genetic testing for the *SCN1A* variant given her 50 % inheritance risk from her mother, identified when Case 2 was 5 months old, and genetic testing was performed with consent. She was found to also harbour the same variant. After careful consideration and consultation with neurology colleagues, she was commenced on prophylactic sodium valproate (20 mg/kg/day) to reduce the risk of seizures, with no side effects reported. In addition, prophylactic paracetamol and clobazam (0.3 mg/kg/day) was given following her 6-, 12- and 18-month vaccinations for the period where a fever post-vaccination was expected (2 days following inactivated vaccine; 14 days following live-attenuated vaccine). Inactivated vaccines (4vMenCV, PCV13 at 12 months and DTPa, HiB at 18 months) were given separate to live-attenuated vaccines (MMR and VZV respectively) to reduce any added risk of FS in concomitant vaccine administration. Currently, at 18 months' old, she has remained seizure free with normal development on prophylactic valproate, with weaning off medication planned from age 2 years.

4. Discussion

Knowledge of the genetic aetiology of epilepsy syndromes offers potential to inform risk stratification and personalised patient care in early childhood, including immunisation management. We report a novel missense *SCN1A* variant in a 12-month-old child who suffered a catastrophic outcome from status epilepticus with cardiac arrest

following vaccination, in the context of recent febrile illness likely associated with enterovirus 71. A subsequent asymptomatic sibling was identified with the same variant, raising the question of optimal management in this case.

Multiple factors may have contributed to the death of Case 1 including vaccination, status epilepticus, pathogenic *SCN1A* variant and enterovirus infection. Although it is not possible to predict an individual's phenotype based on their genotype alone, the pattern in this family is more consistent with GEFS + syndrome, and missense variants more commonly occur with the milder GEFS + phenotype. [1]

Post-vaccination seizures occur in a small number of individuals and are well documented in children with Dravet syndrome. [4] *SCN1A* variants predispose individuals, particularly those with Dravet syndrome, to status epilepticus and to an increased risk of SUDEP. [9] Optimal acute management of status epilepticus is essential, with emphasis on timely and appropriate emergent benzodiazepine treatment (2 adequate doses) followed promptly by second line medication, as per best practice guidelines [10].

Enterovirus 71 infection can cause FSs, aseptic meningitis, and encephalitis following a prodromal illness as in Case 1 and does not typically have evidence of cerebritis at autopsy. [11,12] The presence of CNS infection was unclear due to lack of CSF sampling in this acutely ill infant. In this case, where cardiac arrest followed status epilepticus, enterovirus 71 also predisposes to pulmonary oedema and myocarditis, with young children more severely affected [12]. This underscores the importance of deferring vaccination in children with an acute febrile illness.

Genetic testing in this case had important ethical and counselling implications. Pursuing extended genetic testing at autopsy would have provided the family timely information for reproductive planning, including pre-implantation genetic diagnosis with in-vitro fertilisation. As massively parallel sequencing and genetic diagnosis becomes more prevalent in childhood epilepsy, issues arise about predictive testing for asymptomatic siblings and parents, and optimal evidence-based management for asymptomatic individuals carrying pathogenic variants.

Pre-symptomatic treatment is not our standard management of FSs or risk of seizures in families with genetic epilepsy, as antiepileptic medications may be associated with side effects including on neurodevelopment and cognition. Risk of seizures and poor outcome in Case 2 was considered high given the significant family history, previous infant death, and familial *SCN1A* variant.

Valproic acid and clobazam are considered first line medications in Dravet syndrome with treatment aimed at avoidance of status epilepticus and its impact on neurodevelopment, and are rational choices for epilepsy management in GEFS+. [13] Given the tragic outcome of status epilepticus in the index case, the parents were terrified by the risk of any potential seizure triggers, including febrile illnesses, for Case 2. Therefore, prophylactic treatment with a single first line antiepileptic medication with close monitoring for potential side effects was recommended to reduce the risk of seizure and was provided safely.

Intermittent clobazam use has also been shown to be effective compared to placebo in preventing FSs in children, [14] and was therefore prescribed in addition in the period following vaccination where FS risk is highest. Strategies to reduce seizure triggers in children with Dravet syndrome, recommended by expert consensus panel, include the use of prophylactic antipyretics with vaccination and illness, and prophylactic benzodiazepines with febrile illnesses [13]. While avoidance of or selective immunisation is not recommended in children with epilepsy or epileptic encephalopathy, there are no guidelines on risk management around vaccination of these patients [13,15]. Important principles include deferring vaccination until febrile illness has fully resolved, considering administering vaccines separately, educating families about seizure appearances and first aid, ensuring optimal emergency seizure management, and considering the potential risks and benefits of prophylactic antiepileptic treatment in selected high risk cases.

These cases highlight the challenges of managing young children with genetic epilepsies, including asymptomatic infants with novel pathogenic variants. A conservative approach using antiepileptic medication (daily monotherapy with additional clobazam during a period where fever was likely following vaccination) and prophylactic antipyretics was associated with absence of seizures or significant complications in the second child. The extent to which pre-symptomatic management should be considered in other cases must be carefully assessed on an individual basis. There is not currently adequate evidence to recommend this approach for all children.

5. Conclusion

This is the first report of this novel pathogenic *SCN1A* variant associated with status epilepticus, viral infection and infant death following vaccination. We have described an approach to personalised management around vaccination of an asymptomatic younger sibling with the same variant. Establishing genetic aetiology as early as possible in familial epilepsies has the potential to change management and outcomes for affected children. In future, through cooperative international efforts using well-designed natural history and treatment trials, it should be possible to predict risks and benefits of pre-symptomatic treatment with greater certainty in similar cases, with a view to optimising personalised management of vaccination for children with genetic epilepsies.

Funding

This research did not receive any specific grant from funding agencies in the public, commercial, or not-for-profit sectors.

Declaration of Competing Interest

The authors have no conflict of interest to declare.

Acknowledgements

We thank the parents for their consent with the publication of these cases.

References

- [1] Zuberi SM, Brunklaus A, Birch R, Reavey E, Duncan J, Forbes GH. Genotype-phenotype associations in *SCN1A*-related epilepsies. *Neurology* 2011;76(7):594–600.
- [2] Claes L, Del-Favero J, Ceulemans B, Lagae L, Van Broeckhoven C, De Jonghe P. De novo mutations in the sodium-channel gene *SCN1A* cause severe myoclonic epilepsy of infancy. *Am J Hum Genet* 2001;68(6):1327–32.
- [3] Zhang YH, Burgess R, Malone JP, et al. Genetic epilepsy with febrile seizures plus: refining the spectrum. *Neurology* 2017;89(12):1210–9.
- [4] McIntosh AM, McMahon J, Dibbens LM, et al. Effects of vaccination on onset and outcome of Dravet syndrome: a retrospective study. *Lancet Neurol* 2010;9(6):592–8.
- [5] Richards S, Aziz N, Bale S, et al. Standards and guidelines for the interpretation of sequence variants: a joint consensus recommendation of the American College of Medical Genetics and Genomics and the Association for Molecular Pathology. *Genet Med* 2015;17(5):405–24.
- [6] Pippucci T, Licchetta L, Baldassari S, et al. Epilepsy with auditory features: a heterogeneous clinico-molecular disease. *Neurol Genet* 2015;1(1):e5.
- [7] Bechi G, Rusconi R, Cestele S, Striano P, Franceschetti S, Mantegazza M. Rescuable folding defective NaV1.1 (*SCN1A*) mutants in epilepsy: properties, occurrence, and novel rescuing strategy with peptides targeted to the endoplasmic reticulum. *Neurobiol Dis* 2015;75:100–14.
- [8] Lek M, Karczewski KJ, Minikel EV, et al. Analysis of protein-coding genetic variation in 60,706 humans. *Nature* 2016;536(7616):285–91.
- [9] Cooper MS, McIntosh A, Crompton DE, et al. Mortality in dravet syndrome. *Epilepsy Res* 2016;128:43–7.
- [10] Abend NS, Loddenkemper T. Management of pediatric status epilepticus. *Curr Treat Options Neurol* 2014;16(7):301.
- [11] McMinn P, Stratov I, Nagarajan L, Davis S. Neurological manifestations of enterovirus 71 infection in children during an outbreak of hand, foot, and mouth disease in Western Australia. *Clin Infect Dis* 2001;32(2):236–42.
- [12] Ooi MH, Wong SC, Lewthwaite P, Cardoso MJ, Solomon T. Clinical features, diagnosis, and management of enterovirus 71. *Lancet Neurol* 2010;9(11):1097–105.

- [13] Wirrell EC, Laux L, Donner E, et al. Optimizing the diagnosis and management of dravet syndrome: recommendations from a North American consensus panel. *Pediatr Neurol* 2017;68:18–34. e13.
- [14] Bajaj AS, Bajaj BK, Purib V, Tayal G. Intermittent clobazam in febrile seizures: an Indian experience. *J Pediatr Neurol* 2005;3:19–23.
- [15] Pruna D, Balestri P, Zamponi N, et al. Epilepsy and vaccinations: Italian guidelines. *Epilepsia* 2013;54(Suppl 7):13–22.