

## Late recovery of stereotactic radiosurgery induced perilesional edema of an arteriovenous malformation after bevacizumab treatment

Ece Uysal, Ozan Başkurt, İdris Avcı, Halil Olgun Peker & Suat Erol Çelik

To cite this article: Ece Uysal, Ozan Başkurt, İdris Avcı, Halil Olgun Peker & Suat Erol Çelik (2020): Late recovery of stereotactic radiosurgery induced perilesional edema of an arteriovenous malformation after bevacizumab treatment, British Journal of Neurosurgery, DOI: [10.1080/02688697.2020.1742294](https://doi.org/10.1080/02688697.2020.1742294)

To link to this article: <https://doi.org/10.1080/02688697.2020.1742294>



Published online: 27 Mar 2020.



Submit your article to this journal [↗](#)



Article views: 20




View related articles [↗](#)



View Crossmark data [↗](#)

## Late recovery of stereotactic radiosurgery induced perilesional edema of an arteriovenous malformation after bevacizumab treatment

Ece Uysal, Ozan Başkurt , İdris Avcı, Halil Olgun Peker and Suat Erol Çelik

Department of Neurological Surgery, Okmeydanı Research and Educational Hospital, University of Health Sciences, Istanbul, Turkey

### ABSTRACT

**Purpose:** Today, stereotactic surgery (SRS) is among the treatment options for many intracranial lesions including vascular pathologies. One of the most common late complications of SRS is perilesional edema which can be treated with steroids. In addition to steroids, some new medical therapies are being investigated and one of the promising one is Bevacizumab; a monoclonal antibody against vascular endothelial growth factor (VEGF). In the cases of steroid resistant perilesional edemas, however bevacizumab has a late term effect resolution of symptoms and radiological improvement can be seen as late as more than 1,5 years after its initiation.

**Materials and Methods:** We present a 41-year old male patient who was admitted to our clinic with epileptic seizures, headaches and hemiparesis 14 months after SRS treatment for a left fronto-parietal Spetzler-Martin Grade III arteriovenous malformation (AVM). On his first-year follow-up perilesional edema was observed for which the patient received steroid treatment, but the patient did not show any benefit from it. In the cases of steroid resistant perilesional edemas, bevacizumab can be used for reducing symptoms and even radiological perilesional edema as well.

**Results:** In our case, we have seen the effect of bevacizumab for symptomatic perilesional edema in a AVM patient after SRS treatment after radiological / neurological recovery. Our patient's headaches decreased rapidly after 2 days after treatment and was able to mobilize himself after 2 months but total resolution of symptoms and radiological findings observed after 1,5 years.

**Conclusions:** The duration and optimum dose of bevacizumab therapy needed to further investigation. Our study showed that bevacizumab was a long-term and effective treatment option for the cases with peritumoral edema resistant to glucocorticoid treatment, where the patient had conditions such as severe headache and neurological deficits.

### ARTICLE HISTORY

Received 3 December 2019  
Accepted 10 March 2020

### KEYWORDS

Stereotactic radiosurgery;  
Bevacizumab; arteriovenous  
malformation; perilesional edema

### Introduction

Today, stereotactic radiosurgery (SRS) is among the treatment options for many intracranial lesions including vascular pathologies such as arteriovenous malformations (AVM). Good candidates for SRS of AVMs include deep settled small Grade III – IV lesions with limited risk of bleeding which are not suitable for microsurgical resection.<sup>1</sup> Although considered to be relatively less invasive, SRS also has complications like hemorrhage till to the full closure of the lesion, damaging to neighboring structures, radio-necrosis and late-onset perilesional edema.<sup>2</sup>

Vascular endothelial growth factor (VEGF) has generally been known as a causative factor for perilesional edema and has been documented in *THE LITERATURE*.<sup>3</sup> Symptoms such as headache, neurological deficits and seizures may occur due to peritumoral changes.<sup>4,5</sup> Steroids are first choice as a medical treatment for perilesional edema and is a powerful and effective one. Dexamethasone is a potent steroid receptor agonist to decrease the expression of VEGF and has reliably been used for the treatment of vasogenic edema induced by tumors.<sup>6,7</sup> In addition to glucocorticoids, some new medical therapies are being investigated and one of the more promising ones is Bevacizumab; a monoclonal antibody against VEGF which is currently used in the treatment of recurrent glioblastoma.<sup>8</sup> Although there is not

definite dose or timing of the treatment yet, Bevacizumab is currently under investigation for treatment of radiotherapy-induced tissue necrosis and peritumoral edema.

In the cases of steroid resistant perilesional edemas, Bevacizumab can be used for reducing symptoms and even radiological perilesional edema as well. In our study, we investigated the effect of bevacizumab for symptomatic perilesional edema in a AVM patient after SRS treatment with late radiological/neurological recovery.

### Case report

A 41-year-old male patient was admitted to our department with headache and epileptic seizures. On his neurological examination he had right 4/5 hemiparesis. In the light of advanced survey imaging he had a left fronto-parietal Spetzler–Martin grade III AVM. Considering the location and size of the lesion he received SRS with Cyberknife to observe closure of the vascular structures as a result (Figure 1).

14 months after the SRS the patient presented to our department after having epileptic attack again. Right 3/5 hemiparesis was observed in his neurological examination. On his cranial computed tomography (CT) scan, severe perilesional edema on

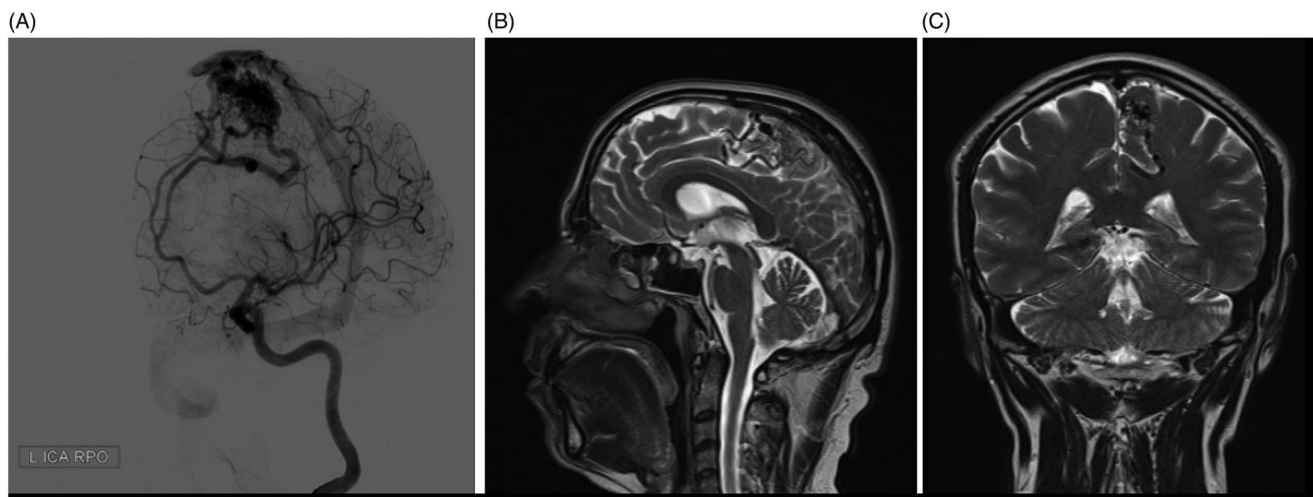


Figure 1. Digital subtraction angiography (DSA) (A) and cranial MRI (B, C) of the AVM in the left parietal lobe before the radiosurgery.

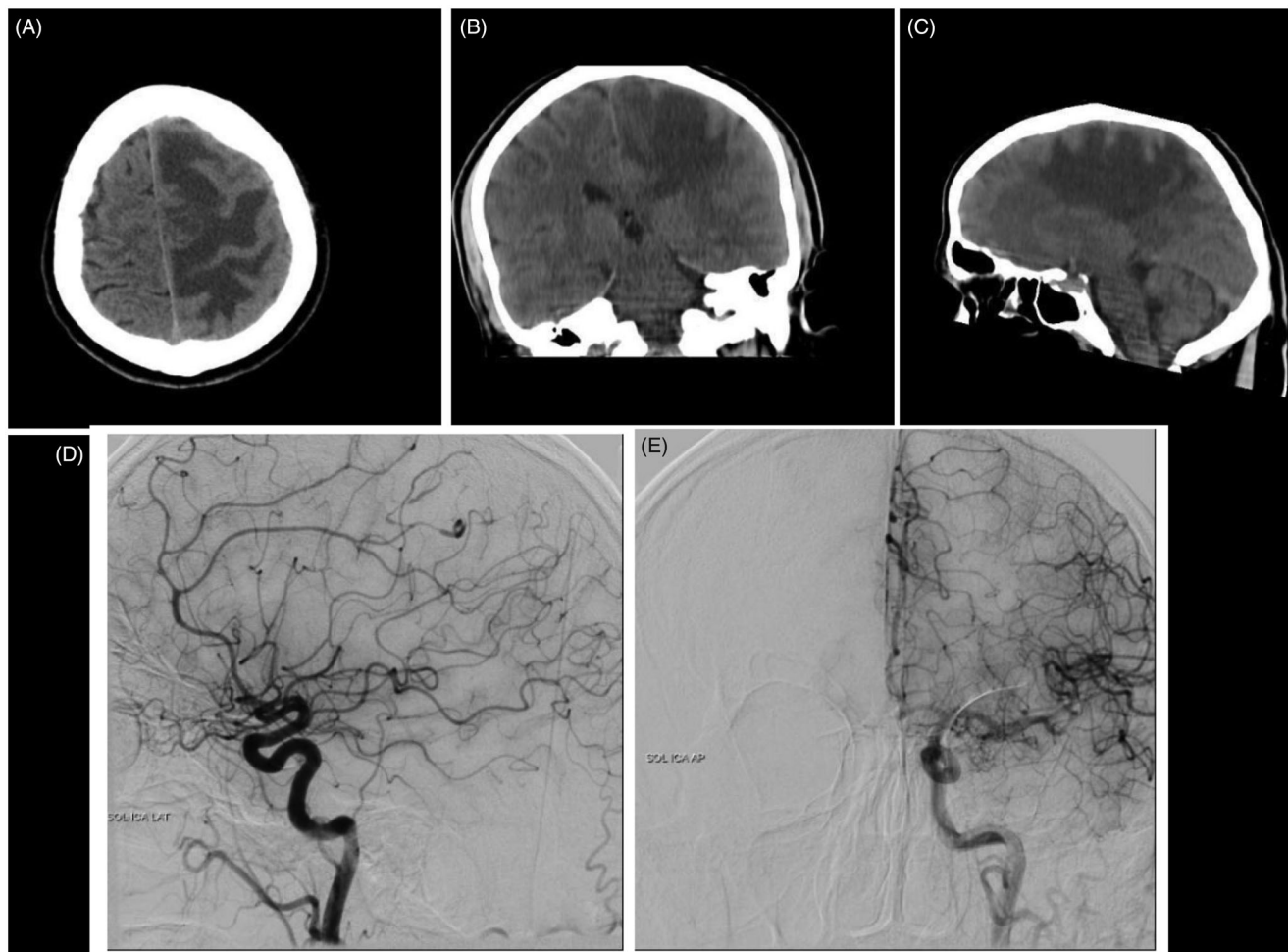


Figure 2. Cranial CT (A,B,C) and DSA (D,E) 12 months after radiosurgery; with significant reduction of the AVM size.

the left frontal and parietal lobes was observed (Figure 2(A–C)). A brain digital subtract angiography (DSA) was performed which showed that the AVM disappeared after SRS (Figure 2(D,E)).

The patient was initially placed on high-dose dexamethasone with increased antiepileptic medication. The frequency of his seizures decreased but hemiparesis, as well as the muscle jerks on the right side, remained the same within the following months. He was suffering terribly from severe headaches during this

period. After 4 months, the patient presented to our emergency department again severe headaches and 2/5 hemiparesis despite being on dexamethasone.

Bevacizumab which is a VEGF antibody which has been used for peritumoral edema of glioblastoma before<sup>8</sup> and the first time used for the treatment of severe, refractory perilesional edema due to an arteriovenous malformation treated with stereotactic radiosurgery by Williams *et al.*<sup>2</sup> Given the inadequate response

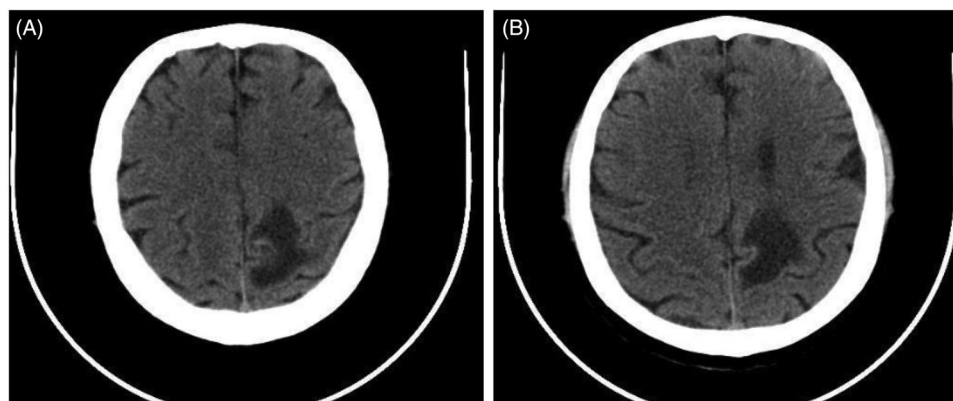


Figure 3. Cranial CT 20 months after Cyberknife radiosurgery and 3 months of bevacizumab treatment.

to corticosteroids and severe refractory symptoms, the option to treat perilesional edema with Bevacizumab was appropriate.

A treatment protocol was initiated in which Bevacizumab was administered at a low dose infusion rate of 2.5 mg/kg over 90 minutes, which was tolerated without any significant side effects. The patient was monitored closely by periodic clinical examinations. His headaches decreased rapidly after 2 days of the treatment but neurological and radiological findings still persisting. The patient was called to our clinic for further evaluation and treatment in two weeks after the first treatment. Since no side effects were observed following the initial dose, the treatment was continued at an infusion rate of 7.5 mg/kg. After the 7.5 mg/kg dose of the treatment, a rapid improvement in the patient's symptoms was seen in the 2nd week. The subsequent CT scan was admitted after one month of Bevacizumab therapy and it showed that the area of perilesional edema persisted. On the other hand, patient's hemiparesis improved to 4/5. He was able to walk with little assistance. No side effects were observed up until now and full blood tests were within normal limits. A systematic physical examination, blood pressure measurements, blood and urine analysis were performed each time the patient received the treatments.

We gave him 7.5 mg/kg bevacizumab infusion every 2 weeks as the maintenance treatment for 2 months. His symptoms continued to regress, and on the second month he was able to walk without assistance. Despite clinical improvement, control imaging did not show a decrease in the area of adequate edema. Since radiological healing was also targeted, follow-up was performed every 3 months as a control.

At his 1.5 year of follow-up the patient has not been experiencing any headaches or seizures anymore. He was able to go to work on his own. On radiological evaluation the perilesional edema was significantly resolved (Figure 3). Reduction in radiologically targeted perilesional edema area was achieved in late period.

In the light of this case, Bevacizumab is promising for the treatment of intracranial perilesional edema. Also we need to be emphasized that treatment needs to be continued because the edema is resolved completely in the late period.

## Discussion

Stereotactic radiosurgery (SRS) has been widely used as a treatment option for selected patients with intracranial lesions<sup>9</sup> and seems usually to be a safe treatment, but 5% to 40% of patients experience treatment-related complications like seizures,

increased headache, temporary or persistent muscle weakness or neurologic deficits and perilesional edema.<sup>10,11</sup>

As a complication of SRS treatment, new or worsening peritumoral edema has been reported in 14%–25% of patients.<sup>4,9,12,13</sup> Venous obstruction, pial supply, location, tumor volume, tumor grade with histological subtype, VEGF receptor expression and patient age were accused for peritumoral edema (PTE) in meningiomas.<sup>14–17</sup>

The risk of developing peritumoral edema is mostly associated with high dose radiation.<sup>18</sup> Conti *et al.*<sup>19</sup> reported 229 cases with meningioma that were treated with radiotherapy in which complications were as follows: 17 patients had epileptic seizures, 13 patients had focal deficits, 12 patients complained about headaches and symptomatic PTE was seen in 19 patients. Four variables were found to be associated with edema development, including tumor volume bigger than 4.5 ml, non-basal tumor location, tight brain/tumor interface and atypical histology. According to their results, a parasagittal location was associated with an increased risk of PTE.

In a report of 111 supratentorial meningioma cases, Patil *et al.*<sup>16</sup> found that patients with parasagittal meningiomas were at greater risk of peritumoral symptomatic edema after SRS.

In our case, the AVM had a large volume and had been draining to the superior sagittal sinus and it was located parasagittally. It has also been reported that lesions with drainage into the wide sinuses have an increased risk of perilesional edema after stereotactic radiosurgery.<sup>9</sup>

Perilesional edema is usually a late-onset complication of radiosurgery. In a study by Kondziolka *et al.*<sup>20</sup> the onset of edema typically occurred 6–8 months after SRS (range 1–23 months). Kan *et al.*<sup>13</sup> found that the mean time to development of the edema was 5.5 months after SRS and the mean duration was 16 months. Parallel to this information; the symptoms in our patient have begun approximately 14 months of stereotactic radiosurgery.

There are various medications and treatment methods used for PTE such as corticosteroids, vitamin E, pentoxifylline, anti-coagulation treatments, interstitial laser thermal therapy and hyperbaric oxygen.<sup>21,22</sup> In a study by Sheehan *et al.*<sup>18</sup> both the radiological and the clinical regression was observed in only 7 of the 16 patients that received glucocorticoids for PTE manifested by headache. In our case, low or high dose treatment with dexamethasone did not show its desired benefits. Severe hemiparesis and epileptic seizures persisted.

In vivo and in vitro data indicate that VEGF is a primary mediator of peritumoral edema.<sup>3,15,23</sup> Ischemic changes in the edematous brain parenchyma may lead to the expression of

VEGF and also VEGF receptors have been shown to exhibit a significantly positive relationship to edema volume.<sup>14,24</sup> Although some studies do not support this conclusion<sup>5,25</sup> VEGF has been accepted as a factor in the formation of PTE associated with meningiomas.<sup>26,27</sup> VEGF inhibitors such as Bevacizumab have been shown to reduce the peritumoral edema as well as the edema following radiosurgery and radiation therapy.<sup>28,29</sup>

Bevacizumab was first used for the side effects of fractionated radiotherapy in a study by Gonzalez *et al.*<sup>30</sup> 8 patients were treated at the dose of 5–7.5 mg/kg every 2–3 weeks. As a result, improvements in MRI imaging and clinical examination were correlated by the reduction of previously given steroid doses. In this study, post-treatment brain imaging performed an average of 8.1 weeks after the start of bevacizumab therapy.

Levin *et al.*<sup>28</sup> treated 14 patients with progressive neurologic symptoms via intravenous Bevacizumab at a dose of 7.5 mg/kg every 3 weeks for 12 weeks due to the central nervous system radiation necrosis secondary to irradiation for head-and-neck carcinoma, meningioma, or low- to mid-grade glioma. Based on this data, more clinical and radiological improvements were observed at 7.5 mg/kg doses compared to 5 mg/kg.

Williams *et al.*<sup>2</sup> used Bevacizumab first time to control symptomatic perilesional edema refractory to corticosteroid therapy after SRS for an intracranial AVM in 2012. Their patient presented to the emergency department with headache and hemiparesis 9 months after Gamma knife surgery. On not benefit from other treatment options for perilesional edema, they used Bevacizumab as the first dose of 2.5 mg/kg and the second dose of 7.5 mg/kg 1 week after. They demonstrated clinical improvement after the administration of bevacizumab therefore they did not continue the maintenance treatment.

Deibert *et al.*<sup>31</sup> evaluated the clinical benefits and radiological response of bevacizumab for refractory adverse radiation effects in 29 patients with brain tumors or vascular malformations. They compared initial diagnosis, SRS dose, bevacizumab treatment protocols, magnetic resonance imaging of edema volumes before and after bevacizumab administration. Patients who involved in this study, received an average dose of 7.4 mg/kg over a mean of 5.7 weeks at a median of 16 months following SRS. %90 with clinically symptomatic due to adverse radiation effects had neurological improvement after bevacizumab therapy. 26 patients had a decrease in edema volumes however 2 patients showed progression. Symptoms recurred in 11 of the 20 patients after discontinuing therapy. They emphasize the duration and optimum dose of bevacizumab therapy needed to further investigation. Similarly, our study showed that bevacizumab was a long-term and effective treatment option for the cases with peritumoral edema resistant to glucocorticoid treatment, where the patient had conditions such as severe headache and neurological deficits. Our patient received 7,5 mg/kg bevacizumab infusion every 2 weeks as the maintenance treatment for 2 months. It should be import once again that treatment needs to be continued for late recovery.

As some complications may develop, Bevacizumab treatment should be administered by an experienced clinic. We did not encounter any complications in our case. In a study of 2712 Japanese patients with colorectal cancer, 2696 patients were investigated in terms of safety analysis. Hypertension (13.1%), hemorrhage (10.5%) and proteinuria (4.5%) were the most common adverse drug reactions. The frequency of serious adverse drug reactions was low; gastrointestinal perforation occurred in 0.9% of patients, hemorrhage in 1.3%, arterial thromboembolic

events in 0.3%, venous thromboembolic events in 1.3% and wound-healing complications in 0.4%.<sup>32</sup>

## Conclusions

Despite its side effects, cost and availability, Bevacizumab may be a feasible option for the treatment of perilesional edema following stereotactic radiosurgery in patients who suffer from treatment-resistant neurological deficits, headache, intractable seizures that do not respond to high dose dexamethasone treatment but its recovery time may be as long as 1,5 years after its initiation. In future studies, the benefits, side effects and adequate treatment time of Bevacizumab may be investigated.

## Disclosure statement

No potential conflict of interest was reported by the author(s).

## ORCID

Ozan Başkurt  <http://orcid.org/0000-0003-1021-6529>

## References

1. Lawton MT, Rutledge WC, Kim H, *et al.* Brain arteriovenous malformations. *Nat Rev Dis Primers* 2015;1:15008.
2. Williams BJ, Park DM, Sheehan JP. Bevacizumab used for the treatment of severe, refractory perilesional edema due to an arteriovenous malformation treated with stereotactic radiosurgery. *J Neurosurgery* 2012;116:972–7.
3. Papavassiliou E, Gogate N, Proescholdt M, *et al.* Vascular endothelial growth factor expression in injured rat brain. *J Neuropathol Exp Neurol* 1999;58:613–27.
4. Chang JH, Chang JW, Choi JY, Park YG, Chung SS. Complications after gamma knife radiosurgery for benign meningiomas. *J Neurol Neurosurg Psychiatry* 2003;74:226–30.
5. Denizot Y, De Armas R, Caire F, *et al.* The Quantitative analysis of bFGF and VEGF by ELISA in human meningiomas. *Mediators Inflamm* 2006;2006:36376.
6. Heiss JD, Papavassiliou E, Merrill MJ, *et al.* Mechanism of dexamethasone suppression of brain tumor-associated vascular permeability in rats. Involvement of the glucocorticoid receptor and vascular permeability factor. *J Clin Invest* 1996;98:1400–8.
7. Kotsarini C, Griffiths PD, Wilkinson ID, Hoggard N. A systematic review of the literature on the effects of dexamethasone on the brain from in vivo human-based studies: implications for physiological brain imaging of patients with intracranial tumors. *Neurosurgery* 2010;67:1799–815.
8. Desjardins A, Reardon DA, Coan A, *et al.* Bevacizumab and daily temozolomide for recurrent glioblastoma. *Cancer* 2012;118:1302–12.
9. Cai R, Barnett GH, Novak E, Chao ST, Suh JH. Principal Risk of Peritumoral edema after stereotactic radiosurgery for intracranial meningioma is tumor-brain contact interface area. *Neurosurgery* 2010;66:513–22.
10. Singh VP, Kansal S, Vaishya S, Julka PK, Mehta VS. Early complications following gamma knife surgery for intracranial meningiomas. *J Neurosurg* 2000;93:57–61.
11. Stafford SL, Pollock BE, Foote RL, *et al.* Meningioma radiosurgery: tumor control, outcomes, and complications among 190 consecutive patients. *Neurosurgery* 2001;49:1029–38.
12. Kobayashi T, Kida Y, Mori Y. Long term results of stereotactic gamma radiosurgery of meningiomas. *Surg Neurol* 2001;55(6):325–31.
13. Kan P, Liu JK, Wendland MM, Shrieve D, Jensen RL. Peritumoral edema after stereotactic radiosurgery for intracranial meningiomas and molecular factors that predict its development. *J Neurooncol* 2007;83:33–8.
14. Otsuka S, Tamiya T, Ono Y, *et al.* The relationship between peritumoral brain edema and the expression of vascular endothelial growth factor and its receptors in intracranial meningiomas. *J Neurooncol* 2004;70:349–57.

15. Gurkanlar D, Er U, Sanli M, Ozkan M, Sekerci Z. Peritumoral brain edema in intracranial meningiomas. *J Clin Neurosci* 2005;12:750–3.
16. Patil CG, Hoang S, Borchers DJ, *et al*. Predictors of Peritumoral edema after stereotactic radiosurgery of supratentorial meningiomas. *Neurosurgery* 2008;63:435–42.
17. Osawa T, Tosaka M, Nagaishi M, Yoshimoto Y. Factors affecting peritumoral brain edema in meningioma: special histological subtypes with prominently extensive edema. *J Neurooncol* 2013;111:49–57.
18. Sheehan JP, Lee CC, Xu Z, Przybylowski CJ, Melmer PD, Schlesinger D. Edema following Gamma Knife radiosurgery for parasagittal and parasagittal meningiomas. *JNS* 2015;123:1287–93.
19. Conti A, Pontoriero A, Siddi F, *et al*. Post-treatment edema after meningioma radiosurgery is a predictable complication. *Cureus* 2016;8:e605.
20. Kondziolka D, Mathieu D, Lunsford LD, *et al*. Radiosurgery as definitive management of intracranial meningiomas. *Neurosurgery* 2008;62:53–60.
21. Giglio P, Gilbert MR. Cerebral radiation necrosis. *Neurologist* 2003;9:180–8.
22. Rahmathulla G, Recinos PF, Valerio JE, Chao S, Barnett GH. Laser interstitial thermal therapy for focal cerebral radiation necrosis: a case report and literature review. *Stereotact Funct Neurosurg* 2012;90:192–200.
23. Bruce JN, Criscuolo GR, Merrill MJ, Moquin RR, Blacklock JB, Oldfield EH. Vascular permeability induced by protein product of malignant brain tumors: inhibition by dexamethasone. *J Neurosurg* 1987;67:880–4.
24. Yoshioka H, Hama S, Taniguchi E, Sugiyama K, Arita K, Kurisu K. Peritumoral brain edema associated with meningioma: influence of vascular endothelial growth factor expression and vascular blood supply. *Cancer* 1999;85:936–44.
25. Lamszus K, Lengler U, Schmidt NO, Stavrou D, Ergün S, Westphal M. Vascular endothelial growth factor, hepatocyte growth factor/scatter factor, basic fibroblast growth factor, and placenta growth factor in human meningiomas and their relation to angiogenesis and malignancy. *Neurosurgery* 2000;46:938–47. discussion 947–8.
26. Ding YS, Wang HD, Tang K, Hu ZG, Jin W, Yan W. Expression of vascular endothelial growth factor in human meningiomas and peritumoral brain areas. *Ann Clin Lab Sci* 2008;38:344–51. PMID: 18988927
27. Sakuma T, Nakagawa T, Ido K, Takeuchi H, Sato K, Kubota T. Expression of vascular endothelial growth factor-A and mRNA stability factor HuR in human meningiomas. *J Neurooncol* 2008;88:143–55.
28. Levin VA, Bidaut L, Hou P, *et al*. Randomized double-blind placebo-controlled trial of bevacizumab therapy for radiation necrosis of the central nervous system. *Int Radiat Oncol Biol Phys* 2011;79:1487–95.
29. Lou E, Sumrall AL, Turner S, *et al*. Bevacizumab therapy for adults with recurrent/progressive meningioma: a retrospective series. *J Neurooncol* 2012;109:63–70.
30. Gonzalez J, Kumar A, Conrad C, Levin V. Effect of bevacizumab on radiation necrosis of the brain. *Int J Radiat Oncol Biol Phys* 2007;67:323–6.
31. Deibert CP, Ahluwalia MS, Sheehan JP, *et al*. Bevacizumab for refractory adverse radiation effects after stereotactic radiosurgery. *J Neurooncol* 2013;115:217–23.
32. Hatake K, Doi T, Uetake H, Takahashi Y, Ishihara Y, Shirao K. Bevacizumab safety in Japanese patients with colorectal cancer. *Jpn J Clin Oncol* 2016;46:234–40.