

A Case of Creutzfeldt-Jakob Disease with Stroke-Like Onset

Kosuke Okamoto, MD, Takato Abe, MD, PhD, and Yoshiaki Itoh, MD, PhD

Creutzfeldt-Jakob disease (CJD) is a prion disease characterized by rapidly progressive dementia that is often followed by behavioral disturbances, ataxia, myoclonus, and akinetic mutism. The initial symptoms of CJD reportedly vary, but the onset is usually gradual. Here, we report a case of CJD with a sudden, stroke-like onset of right hemiparesis to alert readers that CJD can mimic a stroke during its early stage.

Key Words: Creutzfeldt-Jakob disease (CJD)—stroke mimic—sudden onset—prion disease

© 2020 Elsevier Inc. All rights reserved.

Case Report

An 84-year-old female with no family history of neurological disease experienced weakness in her right arm upon awakening one morning. Three days later, she also developed weakness in her right leg. She was referred to our hospital and was admitted 21 days after the onset of her symptoms after her condition failed to improve. A neurological examination revealed agraphia, miscalculation, aphasia, right tactile extinction, and right hemiplegia.

An initial cranial magnetic resonance imaging (MRI) examination showed bilateral scattered cortical hyperintensities on fluid-attenuated inversion-recovery (FLAIR) and diffusion-weighted images (DWI) and apparent diffusion coefficients (ADC) hypointensity, with findings that were similar to those for multiple ischemic strokes (Fig 1, A-D). Cardiac ultrasonography did not reveal any embolic sources. We initially suspected a cardiac embolism and started the administration of an anticoagulant to prevent stroke. Over the following weeks, she became lethargic and globally aphasic and developed myoclonus almost 30 days after onset. On follow-up MRI scans performed on day 41, the cortical signal hyperintensities on DWI and the low

intensity on the ADC map were still persistent (Fig 1, E,F). Her electroencephalogram (EEG) on day 69 showed a periodic synchronous discharge (Fig 1, G).

Her condition continued to deteriorate, and she eventually developed akinetic mutism. A real-time quaking-induced conversion test of her cerebrospinal fluid was positive for 14-3-3 protein. No mutations in prion protein genes were found in a gene analysis. We diagnosed her as having Creutzfeldt-Jakob disease (CJD). She was transferred to another hospital on day 103 and died 112 days after the onset of her symptoms.

Discussion

As this patient presented with the sudden onset of hemiparesis and the MRI findings showed areas of high-intensity DWI with corresponding low ADC areas, a cerebrovascular event was initially suspected. The absence of basal ganglia hyperintense lesions are thought to be atypical for CJD at that stage of the clinical course (Fig 1, D), although some CJD patients do not show hyperintense lesions in the basal ganglia, especially during the early phase.¹

Only a few reports have described ADC map findings in CJD cases with a sudden, stroke-like onset.²⁻⁴ In 2 of these cases, ADC hypointensities correlated with DWI subcortical hyperintensities were shown.^{2,3} The reduced ADC increases over time and becomes normalized at 5-10 days after a cerebral infarction, eventually becoming elevated during the chronic state,⁵ while DWI hyperintensities sometimes take as long as 2 months to resolve.⁶ In the presently reported case, serial MRI scans showed a persistent abnormality in the ADC map, which was atypical for cerebral ischemia and led us to a correct diagnosis.

From the Department of Neurology, Osaka City University Graduate School of Medicine, Osaka City, Osaka, Japan.

Received November 25, 2019; revision received February 16, 2020; accepted February 24, 2020.

Address correspondence to Takato Abe, MD, PhD, Department of Neurology, Osaka City University Graduate School of Medicine, Asahimachi 1-4-3, Abenoku, Osaka City, Osaka, Japan. E-mail: tk-abe@umin.net.

1052-3057/\$ - see front matter

© 2020 Elsevier Inc. All rights reserved.

<https://doi.org/10.1016/j.jstrokecerebrovasdis.2020.104788>

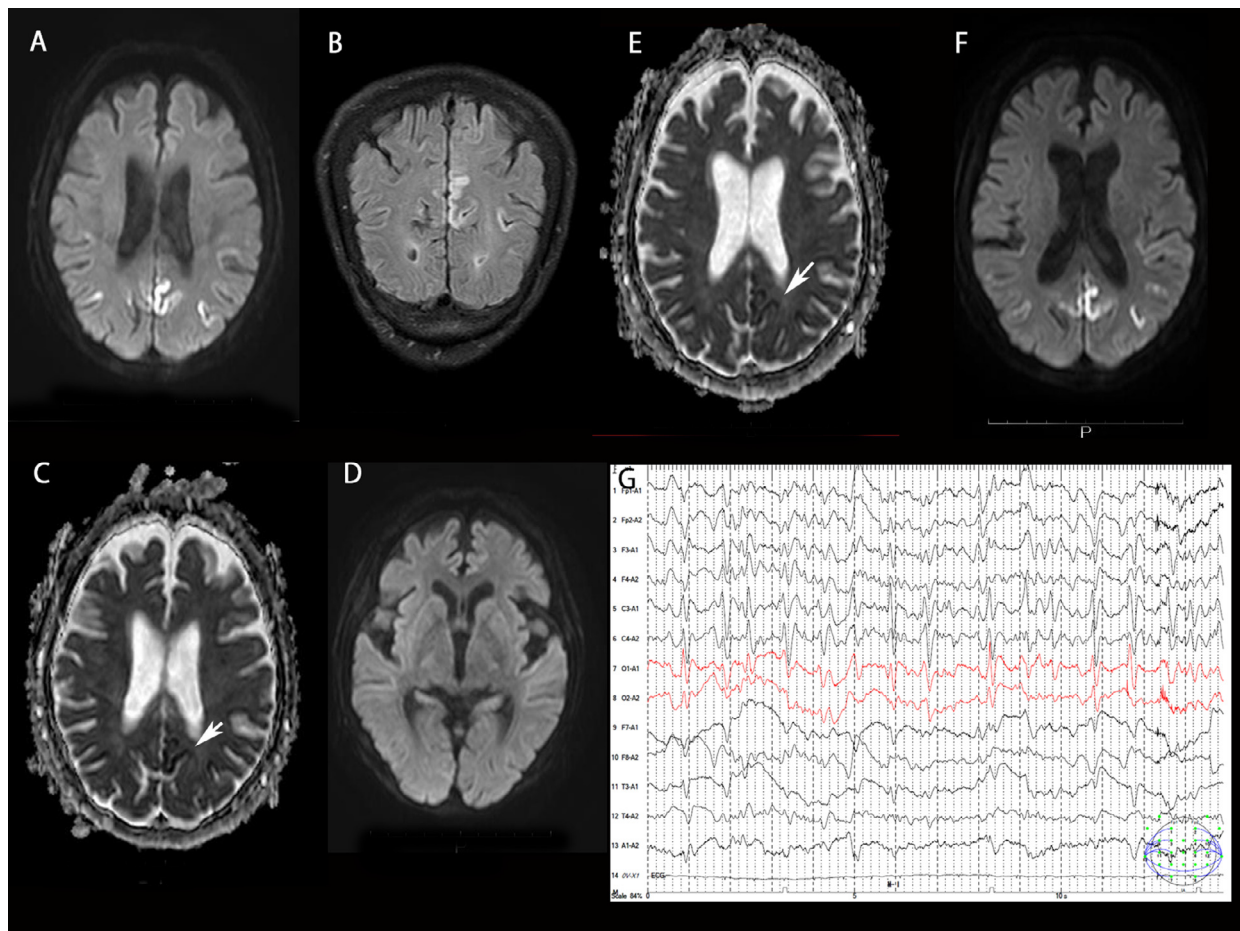


Figure 1. Cranial MRI and EEG. In the cranial MRI performed at the time of admission (A–D), diffusion-weighted imaging (DWI; A, D) and a coronal FLAIR image (B) showed bilateral scattered hyperintense areas. A low-intensity area that was correlated with a high-intensity DWI area is indicated by the white arrow on the ADC map (C). DWI hyperintensities were not detected in the basal ganglia (D). A follow-up MRI was performed on day 41 (E, F). The high-intensity DWI area (F) and the low-intensity ADC area (E) were still present. An electroencephalogram showed periodic synchronous discharges on the 69th day after disease onset (G). Abbreviations: ADC, apparent diffusion coefficients; MRI, magnetic resonance imaging.

The mechanism responsible for the reduced diffusion in CJD is thought to be associated with local compromises in energy metabolism, eg, acute strokes, after prolonged ictal activity; this mechanism in CJD is further supported by the impairment of mitochondrial function in dying neurons.^{2,7} Also, DWI hyperintensity might be due to the deposition of prion protein, which somehow restricts the free diffusion of water.^{8,9}

Serial neuroradiological and laboratory examinations to rule out CJD are recommended in stroke patients with atypical features, such as persistent low intensities on ADC maps.

Acknowledgments

The authors would like to thank Prof. Satoh (Nagasaki University Graduate School of Medicine) for analyzing the 14-3-3 protein and prion genes.

Conflict of Interest

All authors have no conflict of interest for this article.

References

1. Yi SH, Park KC, Yoon SS, et al. Relationship between clinical course and diffusion-weighted MRI findings in sporadic Creutzfeldt-Jakob Disease. *Neurol Sci* 2008;29: 251-255.
2. Szabo K, Achtnichts L, Grips E, et al. Stroke-like presentation in a case of Creutzfeldt-Jakob disease. *Cerebrovasc Dis* 2004;18:251-253.
3. Damato V, Cuccagna C, Costantini EM, et al. Creutzfeldt-Jakob disease manifesting as stroke mimic in a 78-year-old patient: pitfalls and tips in the diagnosis. *J Neurol Sci* 2014;346:343-344.
4. Hohler AD, Flynn FG. Onset of Creutzfeldt-Jakob disease mimicking an acute cerebrovascular event. *Neurology* 2006;67:538-539.
5. Warach S, Gaa J, Siewert B, et al. Acute human stroke studied by whole brain echo planar diffusion-weighted magnetic resonance imaging. *Ann Neurol* 1995;37: 231-241.
6. Rivers CS, Wardlaw JM, Armitage PA, et al. Persistent infarct hyperintensity on diffusion-weighted imaging late after stroke indicates heterogeneous, delayed, infarct evolution. *Stroke* 2006;37:1418-1423.

7. Itoh Y, Takaoka R, Ohira M, et al. Reactive oxygen species generated by mitochondrial injury in human brain microvessel endothelial cells. *Clin Hemorheol Microcirc* 2006;34:163-168.
8. Fragoso DC, Goncalves Filho AL, Pacheco FT, et al. Imaging of Creutzfeldt-Jakob disease: imaging patterns and their differential diagnosis. *Radiographics* 2017;37:234-257.
9. Na DL, Suh CK, Choi SH, et al. Diffusion-weighted magnetic resonance imaging in probable Creutzfeldt-Jakob disease: a clinical-anatomic correlation. *Arch Neurol* 1999;56:951-957.