

Aphasic Status Epilepticus

Alberto Primavera, Gian-Paolo Bo, Simonetta Venturi

Clinica Neurologica dell'Università di Genova, Italia

Key Words. Status epilepticus · Complex partial status epilepticus · Aphasia

Abstract. We studied a case of focal status epilepticus with aphasia as the sole manifestation, lasting 21 days. A 77-year-old woman developed aphasic seizures followed by aphasic status epilepticus 10 months after a left temporo-occipital hemorrhage. The diagnosis was made only after EEG, and seizures were stopped by anticonvulsant medication. Aphasic status epilepticus may be only a reflection of cerebral irritability, suggesting the possibility of a functional etiology for prolonged language disorders also in adults.

Introduction

Cases of status epilepticus characterized by speech impairment, particularly in the form of aphasia, speech arrest or vocalization, have been pointed out for a considerable time [Penfield and Jasper, 1954; Critchley, 1960; Serafetinides and Falconer, 1963]. Nevertheless, reports with aphasia as the sole manifestation of status epilepticus are quite rare [De Pasquet et al., 1976; Hamilton and Matthews, 1979; Dinner et al., 1981; Marrosu et al., 1983; Rosenbaum et al., 1986; Knight and Cooper, 1986]. Here we present the clinical and EEG observation of a patient suffering from aphasic seizures which gave way to a prolonged aphasic status epilepticus.

Case Report

A 77-year-old woman, right-handed, was hospitalized for language disorders, both expressive and receptive on June 15, 1986 (table I). Anamnestic data revealed previous hospitalization (10 months earlier) for 'left temporo-occipital intraparenchymal hemorrhage'; speech and motor disorders resulting from this lesion had, in any case, completely regressed. Nearly 15 days prior to the readmission, mixed speech disorders, initially intermittent, reappeared. Relatives reported that, for some minutes, the patient was unable both to understand what was being said to her and to adequately respond. In

Table I. Clinical course and 30-min EEG pattern of a 77-year-old woman with aphasic status epilepticus

Date (1986)	Clinical course	EEG pattern	Therapy
June 1	intermittent speech disorders	–	–
June 2–14	idem, more frequently	–	–
June 15	hospitalization, severe mixed aphasia	–	–
June 16	unchanged	3 seizures	PB, 100 mg
June 18	unchanged	4 seizures	PB, 100 mg
June 20	moderate improvement, mild aphasia	2 seizures	PB, 150 mg
June 26	normal	modest interictal abnormalities	PB, 150 mg

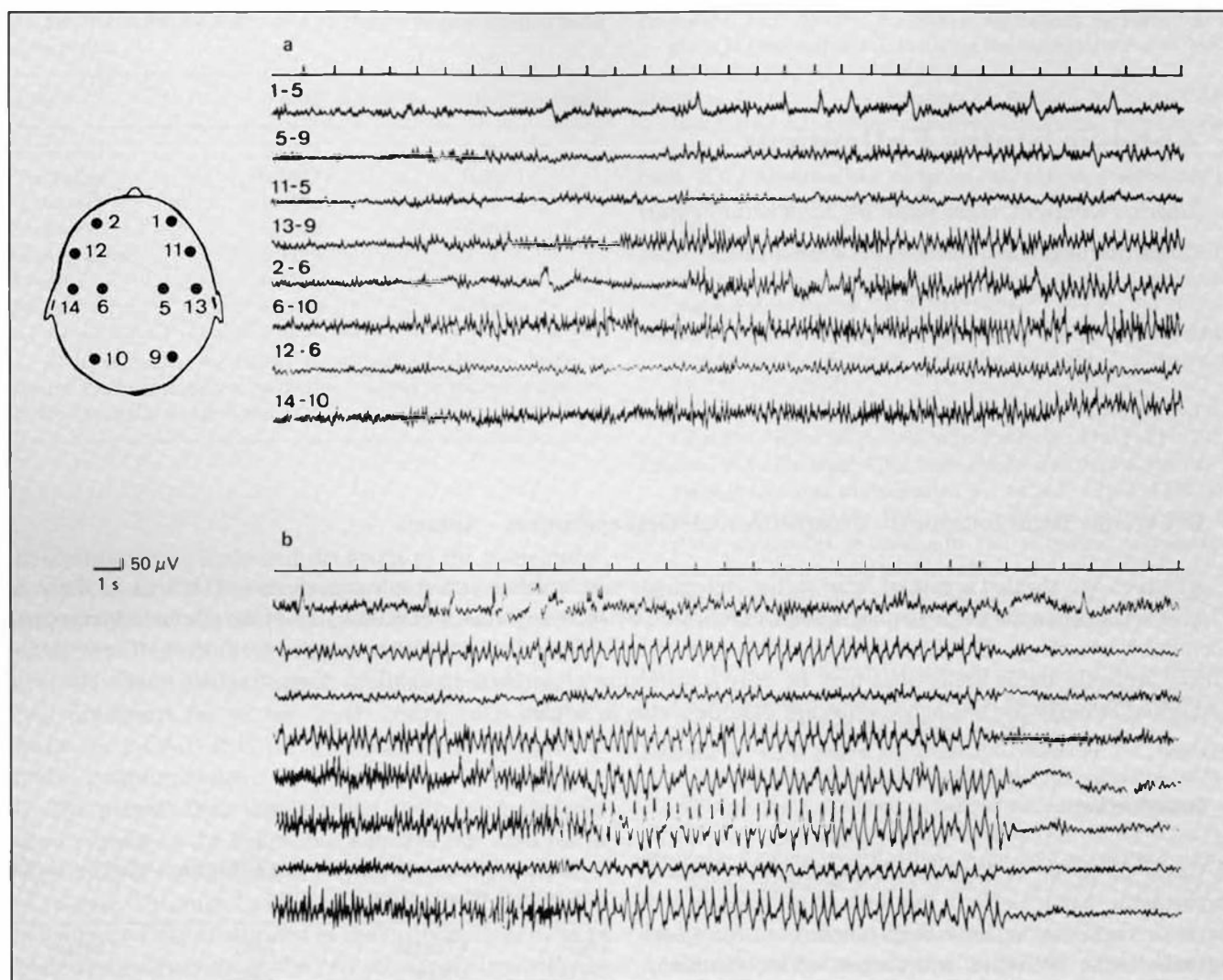


Fig. 1. The EEG, recorded during status epilepticus, showed epileptiform discharges starting with paroxysmal fast activity in the left temporal region (a) which became generalized and was then replaced by spikes and waves of elevated voltage (b).

the days that followed, such episodes became more frequent and language disorders showed no interruption; hospitalization was thus advised. On admission, serious aphasia was apparent as complete abolition of verbal comprehension and reduction of expressiveness to few stereotypes ('yes, yes', 'I don't know'). Neuropsychological examination showed spontaneous speech, repetition and naming markedly impaired, and comprehension totally abolished. The remainder of the neurological examination was normal, as were principal laboratory examinations (complete blood count, urinalysis, glucose, creatinine, electrolytes). Computed tomography scan and nuclear magnetic resonance findings indicated a vast cystic area in the left temporal lobe, resulting from the old hemorrhagic lesion. During the first EEG, performed on June 16, three electrical seizures were recorded in 30 min, the patient remaining seriously and globally aphasic. Seizures lasted about 2 min each, beginning in the left temporal region, then spreading to the full left hemisphere and partially

to the right; they were characterized at first by rapid low-voltage activity, then by spike waves of elevated voltage and finally by slow waves (50–200 μV), intermingled with spike waves (fig. 1). Interictal activity was normal. Treatment with oral phenobarbital (PB) was instituted (100 mg daily). In a second EEG, on June 18, four electrical seizures were seen in 30 min; clinically, the patient was unchanged. After 2 days, a slight global improvement of aphasic symptomatology was observed; the patient began to follow simple orders and express short sentences. Nevertheless, a third EEG still indicated two focal seizures during a 30-min registration; PB therapy was then increased to 150 mg daily. Improvement continued in successive days with progressive remission of aphasic symptoms. The last EEG, taken on June 26, showed only modest interictal abnormalities (slow waves at medium voltage) in the left temporal region. The patient was discharged on PB therapy (150 mg daily, plasma level 25.2 μg/ml). After 12 months no seizures have been seen.

Discussion

According to Mayeux and Lueders [1978] and Dinner et al. [1981], we can define complex partial status epilepticus as 'an electroclinical syndrome of prolonged or repetitive complex partial seizures, with persistence of some or all of the complex symptoms in the interictal period'. The EEG seizure patterns may be either focal (frequently temporal lobe), or secondarily generalized from a focal lesion; seizures may be continuous or recurrent, as apparent in our subject [Lugaresi et al., 1971; Wieser, 1980; Ballenger et al., 1983]. In the last case, the persistence of the symptoms in the interictal period is obviously essential to the diagnosis of 'status epilepticus', independently from the nature of the seizures [Gastaut, 1970]. Our patient presented status epilepticus in which ictal and interictal symptomatology was manifested only by a mixed type of aphasia. We hold that the posthemorrhagic cyst of the temporal lobe caused a focal epileptogenic lesion in the left hemisphere, but it cannot be responsible for the persistence of aphasia in the interictal period. In fact, speech and motor disorders consequent to the hemorrhagic lesion had completely regressed; the reappearance of speech impairment occurred successively, culminating in status epilepticus; serious aphasia lasted as long as recurrent seizures existed, but disappeared simultaneously with the control of seizures; more than 12 months after dismissal, the patient is neurologically normal. In conclusion, this case of aphasic status epilepticus with a clear clinical-EEG correlation shows that, also in adults, prolonged language disorders may be only a reflection of cerebral irritation. Although prolonged aphasia is usually seen in association with acute brain damage or tumors, since the treatments are strikingly different, focal status epilepticus should be considered in the differential diagnosis, when a known etiology is not clearly demonstrated.

References

- Ballenger, C.E.; King, D.W.; Gallagher, B.B.: Partial complex status epilepticus. *Neurology* 33: 1545-1552 (1983).
- Critchley, M.: Troubles de la parole dans les cas d'épilepsie. *Encéphale* 49: 134-137 (1960).
- De Pasquet, E.D.; Gaudin, E.S.; Bianchi, A.; De Mendilaharsu, S.: Prolonged and monosymptomatic dysphasic status epilepticus. *Neurology* 26: 244-247 (1976).
- Dinner, D.S.; Lueders, H.; Lederman, R.; Gretter, T.E.: Aphasic status epilepticus: a case report. *Neurology* 31: 888-890 (1981).
- Gastaut, H.: Clinical and electroencephalographic classification of epileptic seizures. *Epilepsia* 11: 102-113 (1970).
- Hamilton, N.G.; Matthews, M.D.: Aphasia: the sole manifestation of focal status epilepticus. *Neurology* 29: 745-748 (1979).
- Knight, R.T.; Cooper, J.: Status epilepticus manifesting as reversible Wernicke's aphasia. *Epilepsia* 27: 301-304 (1986).
- Lugaresi, E.; Pazzaglia, P.; Tassinari, C.A.: Differentiation of 'absence status' and 'temporal lobe status'. *Epilepsia* 12: 77-87 (1971).
- Marrosu, F.; Brundu, A.; Rachele, M.G.; Marrosu, G.: Epileptic aphasia as dynamic disturbance: a case report. *Acta neurol.* 5: 43-46 (1983).
- Mayeux, R.; Lueders, H.: Complex partial status epilepticus: case report and proposal for diagnostic criteria. *Neurology* 28: 957-961 (1978).
- Penfield, W.; Jasper, H.: *Epilepsy and the functional anatomy of the human brain* (Little, Brown, Boston 1954).
- Rosenbaum, D.H.; Siegel, M.; Barr, M.A.; Rowan, A.J.: Epileptic aphasia. *Neurology* 36: 822-825 (1986).
- Serafetinides, E.A.; Falconer, M.A.: Speech disturbance in temporal lobe seizures. *Brain* 86: 333-346 (1963).
- Wieser, H.G.: Temporal lobe or psychomotor status epilepticus: a case report. *Electroenceph. clin. Neurophysiol.* 48: 558-572 (1980).

Received: July 21, 1987

Accepted: October 26, 1987

Dr. Alberto Primavera
 Clinica Neurologica dell'Università
 Via De Toni, 5
 16132 Genova (Italy)