



Contents lists available at ScienceDirect

## Pediatric Neurology

journal homepage: [www.elsevier.com/locate/pnu](http://www.elsevier.com/locate/pnu)

## Clinical Letter

## A Stroke Mimic: Anti-MOG Antibody-Associated Disorder Presenting as Acute Hemiparesis

Michelle S. Tutmaher, DO <sup>a</sup>, Denise F. Chen, MD <sup>b</sup>, Jamika Hallman-Cooper, MD <sup>c</sup>, Philip J. Holt, MD <sup>a</sup>, Bryan Philbrook, MD <sup>c</sup>, Grace Y. Gombolay, MD <sup>c,\*</sup><sup>a</sup> Department of Pediatrics and Neurology, Emory University School of Medicine, Atlanta, Georgia<sup>b</sup> Department of Neurology, Emory University School of Medicine, Atlanta, Georgia<sup>c</sup> Division of Neurology, Department of Pediatrics, Pediatric Institute: Emory University/Children's Healthcare of Atlanta, Atlanta, Georgia

## ARTICLE INFO

## Article history:

Received 6 December 2019

Accepted 29 February 2020

Available online xxx

## Background

Demyelinating, inflammatory, and autoimmune conditions have been implicated as pediatric stroke mimics.<sup>1</sup> Anti-myelin oligodendrocyte glycoprotein-associated disorder (MOG-AD) has not yet been identified as a pediatric stroke mimic. MOG-AD is a distinct entity with varying clinical demyelinating diseases due to anti-MOG antibodies (MOG-ab).<sup>2,3</sup> Here we describe a patient who presented with acute-onset hemiparesis and respiratory failure with positive MOG-ab.

## Patient Presentation

This 11-year-old previously healthy girl presented within one hour of developing sudden worsening of headache, acute-onset dysarthria, right central facial palsy, and right hemiparesis, concerning for an acute stroke. These acute symptoms were preceded by two days of intermittent headache and dizziness without fevers. On presentation, Glasgow Coma Scale score was 7, prompting intubation, and NIH Stroke Scale score was 31 for an intubated patient with flaccid weakness of the right arm and leg with minimal nonpurposeful movement of the left arm and leg.

Funding sources: This research did not receive any specific grant from funding agencies in the public, commercial, or not-for-profit sectors.

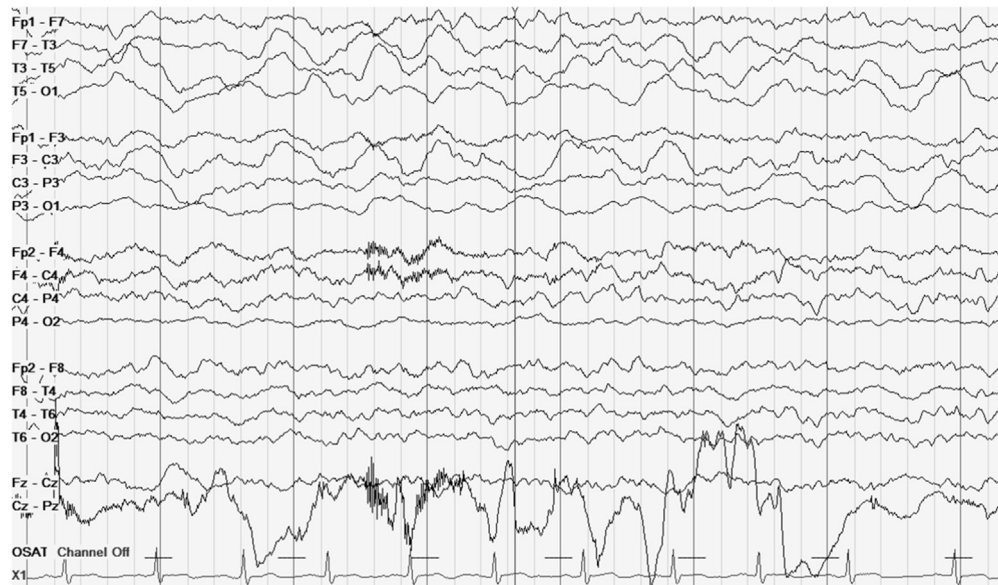
\* Communications should be addressed to: Dr. Gombolay; Division of Neurology; Department of Pediatrics; Pediatric Institute: Emory University/Children's Healthcare of Atlanta; 1400 Tullie Road NE; Atlanta, GA 30329.

E-mail address: [ggombol@emory.edu](mailto:ggombol@emory.edu) (G.Y. Gombolay).

Urgent noncontrast head computed tomography and computed tomographic angiography were negative. Limited magnetic resonance imaging (MRI) of the brain showed normal diffusion-weighted imaging and normal magnetic resonance angiography. Complete blood count, chemistries, and toxicology screening were negative. She was admitted to the pediatric intensive care unit and placed on continuous video electroencephalography, which demonstrated focal slowing over the left hemisphere without epileptiform activity (Fig 1). MRI of the brain with contrast on hospital day (HD) one demonstrated leptomeningeal enhancement in the left frontal and parietal regions with associated mild cortical edema without diffusion restriction, optic neuritis, or other demyelinating lesions (Fig 2). Cerebrospinal fluid (CSF) studies revealed 8 white blood cells/μL (56% neutrophils), 1 red blood cell/μL, glucose 68 mg/dL, and protein 28 mg/dL. Negative CSF studies included cultures, herpes simplex virus polymerase chain reaction (PCR), varicella zoster virus PCR, enterovirus PCR, an arbovirus panel, *Mycoplasma*, *Bartonella*, cytomegalovirus, and Epstein-Barr virus antibodies, and human immunodeficiency virus antigen/antibodies. Serum and CSF autoimmune encephalopathy panels (at Mayo Clinic) were unreremarkable. Serum studies including antinuclear antibodies and anti-double-stranded DNA antibodies, angiotensin-converting enzyme, C3, C4, anti-thyroid peroxidase, thyroglobulin antibody, von Willebrand factor, anti-cardiolipin antibodies, and coagulation profile were also negative. However, serum MOG-ab was positive at 1:40.

Her strength recovered within 24 hours of presentation without immunotherapy or steroids. She remained encephalopathic with confusion and mild anomia and intermittently febrile for the next eight days. Consequently, on HD six she was empirically

<https://doi.org/10.1016/j.pediatrneurol.2020.02.009>  
0887-8994/© 2020 Elsevier Inc. All rights reserved.



**FIGURE 1.** Electroencephalography demonstrates continuous, diffuse, delta slowing of the background with focal slowing over the left hemisphere.

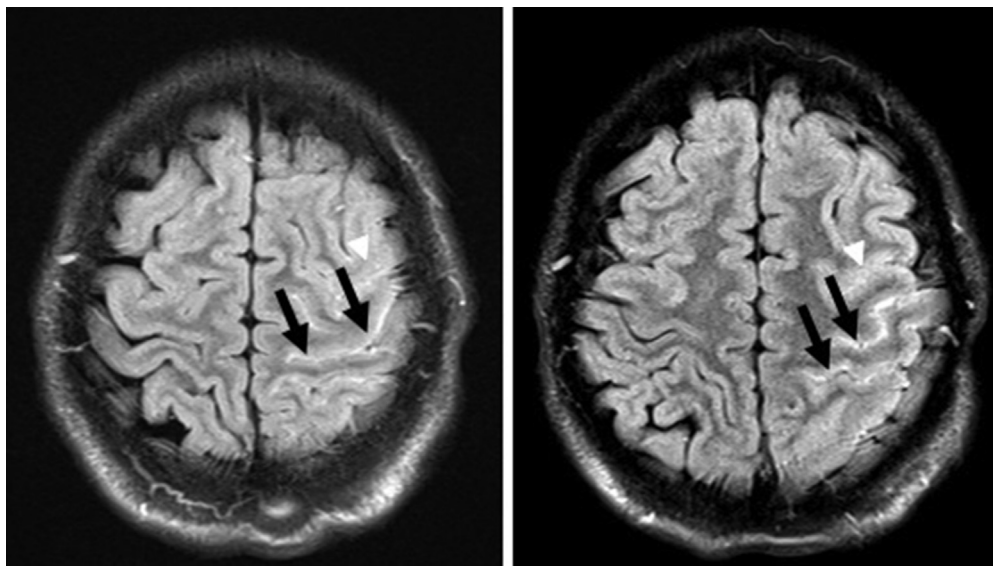
treated with intravenous immunoglobulin (IVIG) 2 g/kg divided over two days with return to her neurological baseline by HD 10. Steroids were not given due to initial concerns for infection. Three months later, follow-up MRI with contrast showed improvement with mild residual enhancement, and repeat serum MOG remained positive (1:40). She has not experienced a clinical relapse in the last seven months.

## Discussion

MOG-AD is identified by MOG-ab seropositivity. MOG-AD has a heterogeneous clinical presentation of demyelinating diseases including acute disseminated encephalomyelitis, optic neuritis, neuromyelitis optica spectrum disorders, transverse myelitis, and multiple sclerosis.<sup>2,3</sup> Our case report highlights another possible clinical presentation of MOG-AD causing stroke-like symptoms due

to focal neuronal inflammation and dysfunction as demonstrated by our patient's clinical examination, neuroimaging, and focal electroencephalography slowing. MOG-ab could be pathologic but difficult to determine currently unless the patient relapses. Other more unusual presentations of MOG-AD include central nervous system vasculitis,<sup>4</sup> aseptic meningitis,<sup>5</sup> and pseudotumor-like symptoms.<sup>5</sup> Her symptoms of fever and encephalopathy were persistent without spontaneous improvement, but rapidly responded to treatment with IVIG. Treatments in MOG-AD include steroids, IVIG, rituximab, and mycophenolate mofetil.<sup>6</sup>

In conclusion, we suggest consideration of MOG-AD in a patient with stroke-like symptoms without evidence of ischemia, especially if leptomeningeal enhancement is present, even in the absence of demyelinating lesions. This child's findings expand the heterogeneous clinical presentation of MOG-ab encephalitis.



**FIGURE 2.** T2 fluid-attenuated inversion recovery postcontrast images reveal abnormal leptomeningeal enhancement (black arrows) predominately in the frontal and parietal regions of the left cerebral hemisphere with associated mild cortical edema (white arrowheads).

## References

1. DeLaroche AM, Sivaswamy L, Farooqi A, Kannikeswaran N. Pediatric stroke and its mimics: limitations of a pediatric stroke clinical Pathway. *Pediatr Neurol.* 2018;80:35–41.
2. Reindl M, Waters P. Myelin oligodendrocyte glycoprotein antibodies in neurological disease. *Nat Rev Neurol.* 2019;15:89–102.
3. Chen Q, Zhao G, Huang Y, et al. Clinical characteristics of pediatric optic neuritis with myelin oligodendrocyte glycoprotein seropositive: a cohort study. *Pediatr Neurol.* 2018;83:42–49.
4. Patterson K, Iglesias E, Nasrallah M, et al. Anti-MOG encephalitis mimicking small vessel CNS vasculitis. *Neurol Neuroimmunol Neuroinflamm.* 2019;6:e538.
5. Narayan RN, Wang C, Greenberg BM. Acute disseminated encephalomyelitis (ADEM) and increased intracranial pressure associated with anti-myelin oligodendrocyte glycoprotein antibodies. *Pediatr Neurol.* 2019;99:64–68.
6. Hacohen Y, Wong YY, Lechner C, et al. Disease course and treatment responses in children with relapsing myelin oligodendrocyte glycoprotein antibody-associated disease. *JAMA Neurol.* 2018;75:478–487.