



A middle-aged man presenting with progressive ataxia and pendular nystagmus: a delayed onset post-stroke movement disorder

Byoung June Ahn¹ · Mina Lee² · Hyunjin Ju² · Kayeong Im² · Kyum-Yil Kwon²

Received: 13 January 2020 / Accepted: 6 April 2020
© Belgian Neurological Society 2020

Introduction

Hypertrophic olivary degeneration (HOD) is a rare neurological condition, which is defined as a secondary degenerative process associated with focal lesions to the Guillain–Mollaret triangle of the dentato-rubro-olivary pathway. The etiologies of HOD include hemorrhage, ischemia, tumors, and demyelination [1, 2]. Classically, patients with HOD show characteristic palatal tremors combined with a variable degree of other neurological signs. Herein, we describe a middle-aged man with HOD that developed 6 months after dorsal pontine hemorrhage, who presented with cerebellar ataxia and pendular nystagmus but not palatal tremor.

Case report

A 55-year-old man was admitted to our hospital for evaluation of progressive gait difficulty. Fourteen months previously, the patient suddenly developed severe postural instability due to hemorrhagic stroke in the pontine tegmentum (Fig. 1a). He had no history of any medical illness and hypertension was diagnosed at that time. Through comprehensive rehabilitation therapy for a half year, the patient nearly recovered from his postural instability and could walk independently. However, over the following 8 months, his

gait disturbance worsened slowly and he became wheelchair bound. The neurological examination revealed a moderate of limb ataxia, which was more prominent in the left extremities than in the right extremities. Sinusoidal oscillation in his eyes was observed but palatal tremor was not noted. Cognitive function tests, as well as motor and sensory examinations, were unremarkable. The patient's routine laboratory tests were normal. T2-weighted magnetic resonance imaging (MRI) revealed high signal intensity in the bilateral inferior olivary nucleus (ION), which was more predominant in the right side than in the left side (Fig. 1b). Video electronystagmography showed pendular nystagmus of 2.5 Hz frequency, which was mainly horizontally directed and more severe in the left eye than the right eye (Fig. 1c). Further evaluations, including a cerebrospinal fluid study and detailed tests for paraneoplastic syndrome, yielded unremarkable findings. The patient became bedridden after several months and we have followed him for one and a half years. The patient's pendular nystagmus and cerebellar ataxia were not improved in spite of many trials of medications including gabapentin, clonazepam, memantine, baclofen, pregabalin, trihexyphenidyl, buspirone, and amantadine.

Discussion

Initially, we did not confirm the diagnosis of HOD because (1) the patient did not exhibit a palatal tremor, which is regarded as a core finding of HOD [1–3], and (2) his main clinical features suggested adult-onset cerebellar ataxia. After excluding the possible etiologies including cerebellitis, neurodegenerative disorders such as multiple system atrophy, and paraneoplastic cerebellar ataxia, we finally concluded that the patient had HOD as a post-stroke movement disorder associated with the previous history of dorsal pontine hemorrhage, based on the patient's clinical history and the brain MRI findings. Consistent with the current case, some cases with HOD did not reveal palatal tremors [2, 4].

Electronic supplementary material The online version of this article (<https://doi.org/10.1007/s13760-020-01354-x>) contains supplementary material, which is available to authorized users.

✉ Kyum-Yil Kwon
denovo78@naver.com

- ¹ Department of Neurology, Soonchunhyang University Gumi Hospital, Soonchunhyang University College of Medicine, Gumi, Korea
- ² Department of Neurology, Soonchunhyang University Seoul Hospital, Soonchunhyang University College of Medicine, 59 Daesagwan-ro, Yongsan-gu, Seoul 04401, Republic of Korea

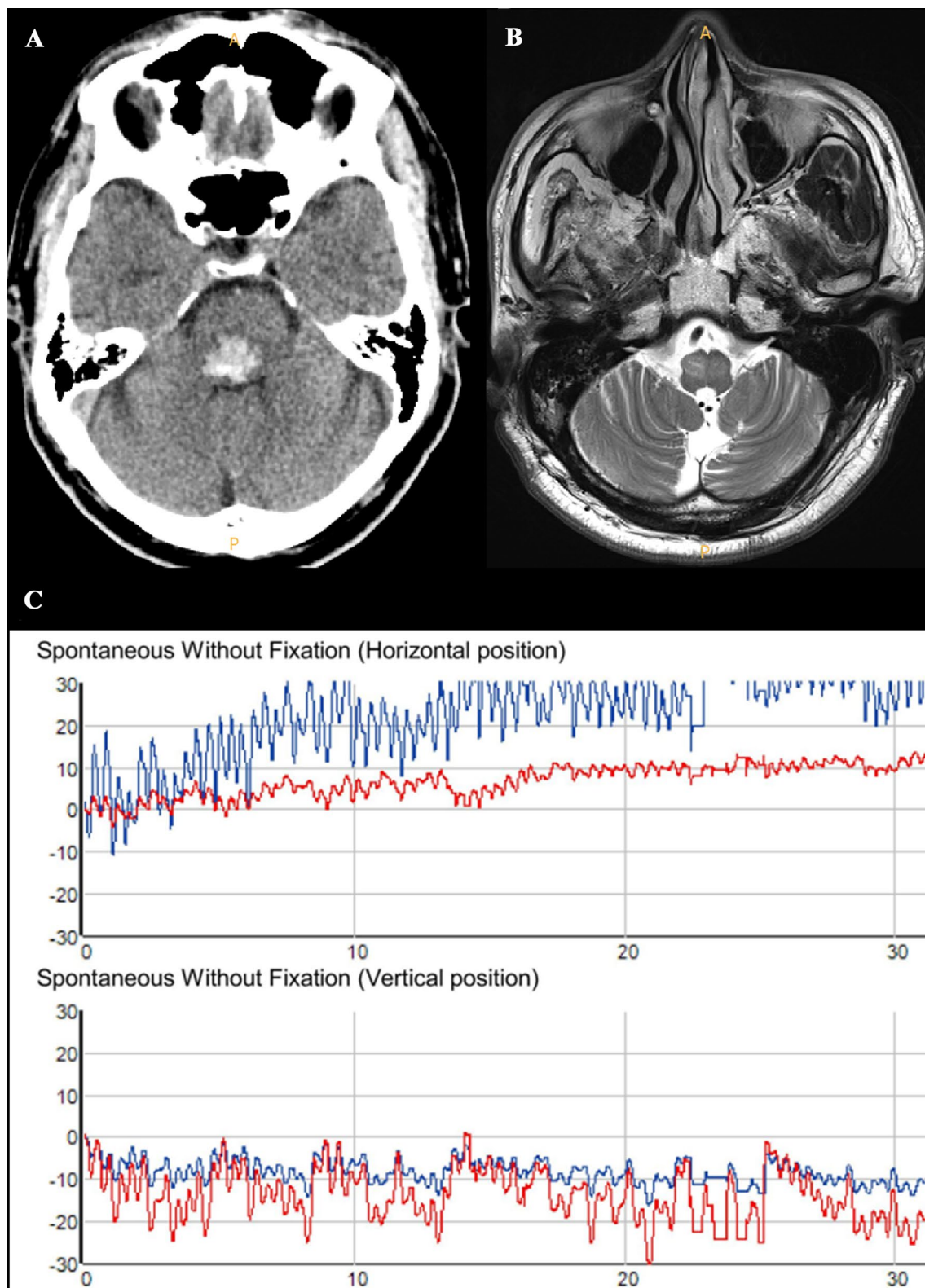


Fig. 1 Hypertrophic olivary degeneration after pontine hemorrhage. **a** A brain computed tomography scan shows dorsal pontine hemorrhage. **b** After 14 months of pontine hemorrhage, the T2-weighted image exhibits high signal intensity with hypertrophic change at the bilateral inferior olivary nucleus (ION), which is more prominent in

the right ION, compared to the left ION. **c** Video electronystagmography reveals mainly horizontally directed pendular nystagmus, which is more severe in the left eye (blue color), compared to the right eye (red color) (color figure online)

Hypertrophic changes of the ION are considered to be the result of trans-synaptic degeneration between the ION and the dentatorubral or central tegmental tracts (CTT) of the Guillain–Mollaret triangle. Ipsilateral HOD is related to injury of the red nucleus or CTT, while contralateral HOD is associated with damage to the dentate nucleus or dentatorubral fibers [1, 2]. In agreement with the literature, our patient showed a dorsal pontine hemorrhage, which was more prominent in the right CTT than the left CTT (Fig. 1a), resulting in more hypertrophic changes in the ipsilateral ION (Fig. 1b). Moreover, HOD is responsible for neurological symptoms or signs in the contralateral limb. Our patient revealed more severe pendular nystagmus and ataxia in the left side, compared to the right side (Fig. 1c). Taken together, we deduced that the patient’s asymmetric clinical and radiological findings were compatible with laterality associated with the Guillain–Mollaret triangle [1, 2]. On the other hand, the reason for the absence of palatal tremor in our patient was not clear. Different patients with HOD have shown different sizes as well as different locations. Kono and colleagues reported that the combination of presenting symptoms in patients with HOD could be variable [2]. Therefore, one possible explanation is that the secondary degenerative process of the Guillain–Mollaret triangle in patients with HOD might be a little bit differently affected by the primary brain lesion. To better understand the pathophysiology of HOD in detail, well-designed studies of the clinico-radiological features are required.

In conclusion, we suppose that this case could expand the clinical spectrum of HOD after stroke. Clinicians need to be aware of the possibility of delayed symptoms in patients with a previous history of stroke.

Acknowledgements This work was supported by the Soonchunhyang University Research Fund (the number is not applicable).

Compliance with ethical standards

Conflict of interest The authors declare that they have no conflict of interest.

Ethical approval This article does not contain any studies with human participants or animals performed by any of the authors.

Informed consent Written informed consent was obtained from the patient.

References

1. Tilikete C, Desestret V (2017) Hypertrophic olivary degeneration and palatal or oculopalatal tremor. *Front Neurol* 29:302. <https://doi.org/10.3389/fneur.2017.00302>
2. Konno T, Broderick DF, Tacik P, Caviness JN, Wszolek ZK (2016) Hypertrophic olivary degeneration: a clinico-radiologic study. *Parkinsonism Relat Disord* 28:36–40. <https://doi.org/10.1016/j.parkreldis.2016.04.008>
3. Jellinger K (1973) Hypertrophy of the inferior olives: report on 29 cases. *J Neurol* 205:153–174
4. Cosentino C, Velez M, Nuñez Y, Palomino H, Quispe D, Flores M, Torres L (2016) Bilateral hypertrophic olivary degeneration and holmes tremor without palatal tremor: an unusual association. *Tremor Other Hyperkinet Mov (N Y)* 14:400. <https://doi.org/10.7916/D87944SS>

Publisher’s Note Springer Nature remains neutral with regard to jurisdictional claims in published maps and institutional affiliations.