

CASE REPORT

doi: 10.5455/medarch.2020.74.58-60

MED ARCH. 2020 FEB; 74(1): 58-60

RECEIVED: JAN 02, 2020 | ACCEPTED: FEB 14, 2020

Department of Neurology, General Hospital
«Prim.dr. Abdulah Nakas», Sarajevo, Bosnia and
Herzegovina

Corresponding author: Amel Amidzic, MD.
Department of Neurology, General Hospital
«Prim. Dr. Abdulah Nakas», Sarajevo, Bosnia
and Herzegovina. E-mail: a_amidzic@yahoo.
com. Phone: +38761448-765. ORCID ID:
<https://orcid.org/0000-0002-9504-2427>.

Kinking of Bilateral Internal Carotid Arteries as Cause of Cognitive Dysfunction

Amel Amidzic¹, Naida Tiro¹

ABSTRACT

Introduction: Dolichoarteriopathies of the internal carotid artery (DICAs) is divided into three forms: tortuous, coiling and kinking. In case of kinking, internal carotid artery forms a sharp angle of <90 degrees, while in the background there is metaplasia of a tunica media with unknown etiology. The association with stroke is still questionable, but it is believed that it can be associated with cerebral ischemia and with clinical symptomatology that accompanies cerebral ischemia. **Aim:** Aim of article was to present diagnostic and therapeutic modality of patient with verified internal carotid artery kinking. **Case report:** The 55-year-old male patient was admitted to the Department of Neurology, General Hospital «Prim.dr. Abdulah Nakas», due to dizziness and instability while walking, forgetfulness, memory loss and low mood. He has previously been reported to be hypertensive and with diagnosis of diabetes mellitus and dyslipidemia. Doppler sonography also suspects on distal subocclusion of the internal carotid artery (low flow rates were observed). Diagnostic transcranial Doppler (TCD) of vertebrobasilar artery showed decreased blood flow velocities in both vertebral and basilar artery and indicated atherosclerotic altered blood vessels of the brain. CTA findings indicate bilateral kinking of internal carotid artery with right duplex Kinking. SPECT with 15 mCi 99mTc-hexamethylpropyleneamineoxime (99mTc-HMPAO) verified global cortex hypoperfusion, indicating chronic vascular failure. The patient was treated with acetylsalicylic acid, clopidogrel, atorvastatin, donepezil, memantine, escitalopram, bromazepam, along with antihypertensive and antidiabetic therapy (per os). **Conclusion:** A severe degree of kinking can cause neurological symptomatology, especially if it is bilateral. Symptoms of cerebrovascular disease are more pronounced when autoregulation of cerebral hemodynamics is impaired. Bilateral severe degree of kinking possibly can cause cognitive impairment. Diagnosis, analysis of the existence of possible risk factors for the onset, and the existence of genetic predisposition are a prerequisite for better understanding of the disease and optimal treatment.

Keywords. Cerebral Arteries, Cognitive Dysfunction, Cerebrovascular Disorders.

1. INTRODUCTION

Dolichoarteriopathies of the internal carotid artery (DICAs) is divided into three forms: tortuous, coiling and kinking (1). In case of kinking, internal carotid artery forms a sharp angle of <90 degrees, while in the background there is metaplasia of a tunica media with unknown etiology (2).

The association with stroke is still questionable, but it is believed that it can be associated with cerebral ischemia and with clinical symptomatology that accompanies cerebral ischemia. Carotid kinking occurs in 4–25% of patients with symptomatic ischemic cerebrovascular disease (3). Correlation of kinking with signs of ischemia, with consequent signs of dementia, mental function loss or neurological deficits is still unclear due to several factors that may influ-

ence the onset of these symptoms, but it should be noted that carotid kinking can also be found in asymptomatic patients (4–7).

There are two types of kink. First is congenital which is clinically significant in older age and is most common in late forties and early fifties and is more common in women. Second type is based on atherosclerotic changes and it is localized at the end of atherosclerotic plaque (8). Diagnosis is made based on anamnestic data, clinical presentation, Doppler ultrasonography, computed tomography angiography (CTA), magnetic resonance angiography (MRA), digital subtraction angiography (DSA) and single-photon emission computed tomography (SPECT) for evaluation of cerebrovascular hemodynamics caused by kinking (1–3).

© 2020 Amel Amidzic, Naida Tiro

This is an Open Access article distributed under the terms of the Creative Commons Attribution Non-Commercial License (<http://creativecommons.org/licenses/by-nc/4.0/>) which permits unrestricted non-commercial use, distribution, and reproduction in any medium, provided the original work is properly cited.

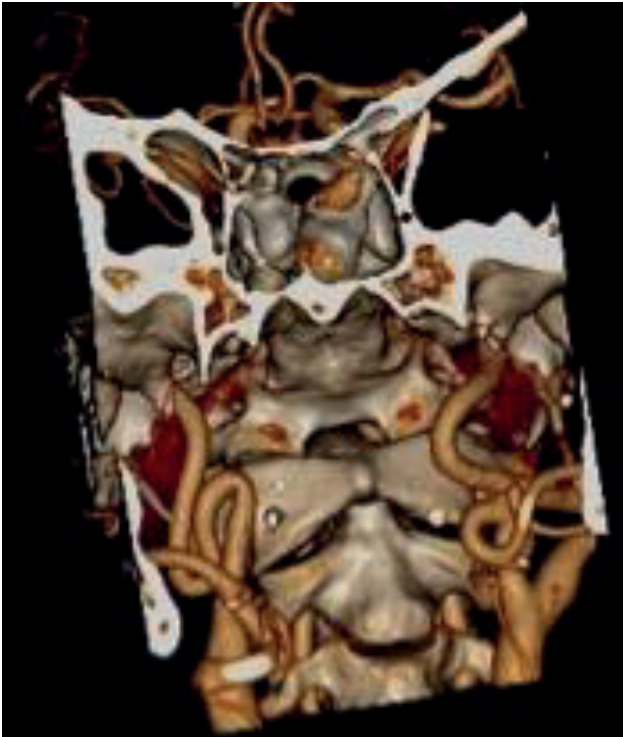

Figure 1. 3D Volume Rendering Technique (VRT)

2. AIM

Aim of article was to present diagnostic and therapeutic modality of patient with verified internal carotid artery kinking.

3. CASE REPORT

The 55-year-old male patient was admitted to the Department of Neurology, General Hospital «Prim.dr. Abdullah Nakas», due to dizziness and instability while walking (symptoms lasted for a year), forgetfulness, memory loss and low mood (symptoms more pronounced for two months). He has previously been reported to be hypertensive and with diagnosis of diabetes mellitus and dyslipidemia. At the age of 54, he had a stroke with discrete hemiparesis on the right extremities (brain CT showed micro-ischemic lesions with different time of occurrence and a stroke of lacunar size perimesencephalic left). Also 6 months ago he had a transitory ischemic attack with short-term speech impairment and transient weakness of his right arm. He has a metal foreign object in his body from being injured in the war. In neurological status he was conscious, oriented, communicative, without deficit on cranial nerves, with reduced cognitive function.

The Mini-Mental State Exam (MMSE) was 21. He had no motoric weakness on extremities, motor tendon reflexes were without deficit, Romberg was negative. Low

mood was observed without psychotic symptoms. Electroencephalogram (EEG), otoscopy and vestibulogram were within physiological limits. Echocardiography examination was within physiological parameters. Initial dilation of both carotid joint arteries with mutually low hemodynamic parameters in the right internal carotid artery was verified by Doppler sonography. Doppler sonography also suspects on distal subocclusion of the internal carotid artery (low flow rates were

observed). Diagnostic transcranial Doppler (TCD) of verteobasilar artery showed decreased blood flow velocities in both vertebral and basilar artery and indicated atherosclerotic altered blood vessels of the brain (Figure 1). CTA findings indicate bilateral kinking of internal carotid artery with right duplex Kinking (Figure 2). SPECT with 15 mCi ^{99m}Tc -hexamethylpropyleneamineoxime (^{99m}Tc -HMPAO) verified global cortex hypoperfusion, indicating chronic vascular failure (Figure 3). The patient was treated with acetylsalicylic acid, clopidogrel, atorvastatin, donepezil, memantine, escitalopram, bromazepam, along with antihypertensive and antidiabetic therapy (per os).

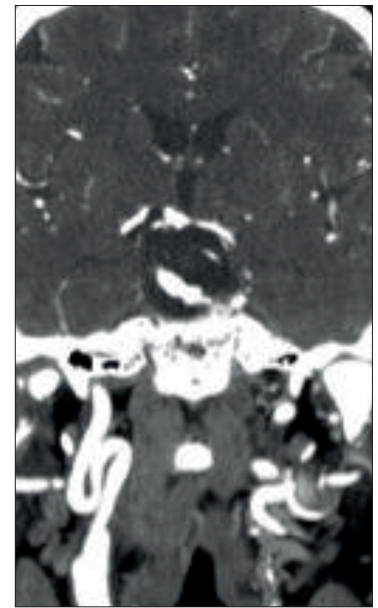

Figure 2. Maximum Intensity Projection–Bilateral Kinking ACI with right duplex Kinking verified

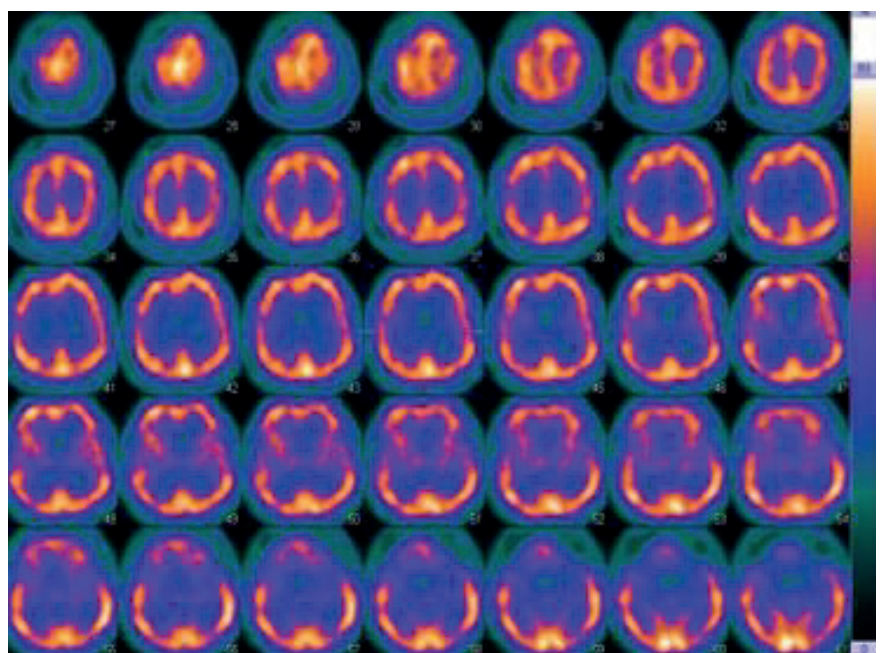


Figure 3. SPECT with 15 mCi ^{99m}Tc -hexamethylpropyleneamineoxime (^{99m}Tc -HMPAO)–global cortex hypoperfusion, indicating chronic vascular failure

4. DISCUSSION

Changing the geometry of internal carotids arteries can cause symptomatology that is associated with ischemic etiology, but direct relation to stroke is still questionable (9). Metz et al. divided kinking into three degrees. First degree is with an angle of 90°-60° between the two segments who form the kink, second degree is with angle of 60°-30°, while third indicates an angle less than 30° (10). Vollmar et al. stated that kinking symptoms may be decreased or increased by the position of the head (11). Kinking reduce blood supply to the brain through decreases in blood pressure, which often do not lead to cerebral ischemia due to compensation of the self-regulatory mechanism in the cerebral blood supply, transient hypotension, cerebrovascular insufficiency that produces dyscirculatory encephalopathy, vertigo, diplopia, transitory ischemic attacks or infarction, along with ocular vascular insufficiency and pulsatile tinnitus (1, 5, 7, 11). Depletion of synapses and neurotransmission, with chronic hypoperfusion, leads to cognitive impairment (1). Type 1 is associated with the A80807T polymorphism of the transcription factor Sp4, as well as with matrix metalloproteinase-2 (MMP-2) (1, 12, 13). It can also be associated with fibromuscular dysplasia and with Loeys-Dietz syndrome type IB (14). Type 2 is associated with all atherosclerotic risk factors, including hypertension, hypercholesterolemia, diabetes mellitus and smoking (1). Reduced blood flow caused by flexed carotid artery is comparable to carotid stenosis of 75% (15). Level III kinking with an angle of fewer than 30 degrees can cause cognitive impairment, and it is stated that the Montreal Cognitive Assessment (MoCA) is superior to Mini-Mental State Examination (MMSE) in recognizing mild cognitive impairment (16). The therapeutic modality is moving towards surgical treatment and optimized pharmacological therapy, which includes anti-aggregation therapy, anticoagulation therapy, antihypertensives, antilipidemic and cerebral vasodilatation therapy (1).

5. CONCLUSION

Kinking of internal carotid artery is a diagnostic and therapeutic challenge in the daily work of a neurologist. A severe degree of kinking can cause neurological symptomatology, especially if it is bilateral. Symptoms of cerebrovascular disease are more pronounced when autoregulation of cerebral hemodynamics is impaired. Bilateral severe degree of kinking possibly can cause cognitive impairment. Diagnosis, analysis of the existence of possible risk factors for the onset, and the existence of genetic predisposition are a prerequisite for better understanding of the disease and optimal treatment.

- **Declaration of patient consent:** The authors certify that they have obtained all appropriate patient consent forms. In the form, the patient has given her consent for her images and other clinical information to be reported in the journal.
- **Author's Contribution:** A.A. and N.T. gave substantial contribution to the conception or design of the work and in the acquisition, analysis and interpretation of data for the work. Both authors had role in drafting the work and revising it critically for important intellectual

content. Both authors gave final approval of the version to be published and they agree to be accountable for all aspects of the work in ensuring that questions related to the accuracy or integrity of any part of the work are appropriately investigated and resolved.

- **Conflict of interest:** There are no conflicts of interest.
- **Financial support and sponsorship:** Nil.

REFERENCES

1. Yu J, Qu L, Xu B, Wang S, Li C, Xu X, et al. Current Understanding of Dolichoarteriopathies of the Internal Carotid Artery: A Review. *Int J Med Sci*. 2017; 14(8): 772-784.
2. Weibel J, Fields WS. Tortuosity, coiling, and kinking of the internal carotid artery II. Relationship of morphological variation to cerebrovascular insufficiency. *Neurology*. 1965 May; 15: 462-468.
3. Leipzig TJ, Dohrmann GJ. The tortuous or kinked carotid artery: pathogenesis and clinical considerations. A historical review. *Surg Neurol*. 1986; 25(5): 478-486.
4. Vannix RS, Joergenson EJ, Carter R. Kinking of the internal carotid artery. Clinical significance and surgical management. *Am J Surg*. 1977 Jul; 134(1): 82-89.
5. Grego F, Lepidi S, Cognolato D, Frigatti P, Morelli I, Deriu GP. Rationale of the surgical treatment of carotid kinking. *J Cardiovasc Surg (Torino)*. 2003; 44(1): 79-85.
6. Begic E, Hadzidedic S, Kulagic A, Ramic-Brkic B, Begic Z, Causevic M. SOMAscan-based proteomic measurements of plasma brain natriuretic peptide are decreased in mild cognitive impairment and in Alzheimer's dementia patients. *PLoS ONE* 2019; 14(2): e0212261.
7. Mumoli N, Cei M. Asymptomatic Carotid Kinking. *Circ J* 2008; 72: 682 - 683
8. Benes V, Mohapl M. Alternative surgery for the kinked internal carotid artery. *Acta Neurochirurgica*. 2001; 143: 1267-1271.
9. Togay-Işikay C, Kim J, Betterman K, Andrews C, Meads D, Tesh P, et al. Carotid artery tortuosity, kinking, coiling: stroke risk factor, marker, or curiosity? *Acta Neurol Belg*. 2005; 105(2): 68-72.
10. Metz H, Murray-Leslie RM, Bannister RG, Bull JW, Marshall J. Kinking of the internal carotid artery. *Lancet*. 1961; 1: 424-426.
11. Vollmar J, Nadjafi AS, Stalker CG. Surgical treatment of kinked internal carotid arteries. *Br J Surg*. 1976; 63: 847-850
12. Arslan Y, Arslan IB, Pekcevik Y, Sener U, Kose S, Zorlu Y. Matrix Metalloproteinase Levels in Cervical and Intracranial Carotid Dolichoarteriopathies. *J Stroke Cerebrovasc Dis*. 2016; 25: 2153-2158.
13. Voevoda MI, Kulikov IV, Maksimov VN, Smirnova Iu V. Association of Sp4 gene polymorphism with pathological tortuosity of internal carotid arteries. *Kardiologija*. 2009; 49: 46-49.
14. Paltseva EM, Oskolkova SA, Polyakova VO, Krylova YU, Ivanova AG, Abramyan AV, et al. The structure of the internal carotid artery wall in pathological tortuosity. *Arkh Patol*. 2015; 77: 3-8.
15. Borioni R, Garofalo M, Actis Dato GM, Pierri MD, Caprara E, Albano P, et al. Kinking of internal carotid artery: is it a risk factor for cerebro-vascular damage in patients undergoing cardiac surgery? *J Cardiovasc Surg (Torino)*. 1994; 35(4): 325-326.
16. Chen L, Huang J, Wang S, Ran H, Wen L, Chen K, et al. Effect of Carotid Artery Morphological Variations on Cognitive Function, Behavioural Neurology, 2018; 2018: 7290431.