


## Case report

## Rare case of basilar artery aneurysm in a young child

Peter Mallett,<sup>1</sup> Sean Thomas O'Reilly ,<sup>2</sup> Ian Rennie,<sup>2</sup> Mano Shanmuganathan,<sup>3</sup> Andrew James Thompson<sup>1</sup>

<sup>1</sup>Department of Paediatrics, Royal Belfast Hospital for Sick Children, Belfast, UK

<sup>2</sup>Department of Radiology, Royal Victoria Hospital, Belfast, UK

<sup>3</sup>Department of Neurosurgery, Royal Victoria Hospital, Belfast, UK

**Correspondence to**

Dr Andrew James Thompson; andrew.thompson@belfasttrust.hscni.net

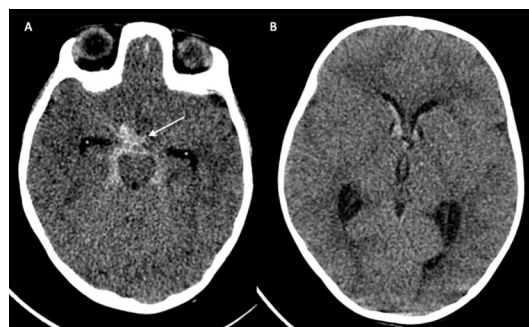
Accepted 19 March 2020

**SUMMARY**

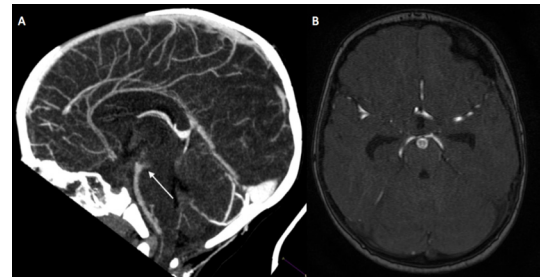
A previously well, 14-month-old girl presented with acute decreased level of consciousness. There was no history of trauma, systemic upset or significant family history. Blood pressure was within normal range and no focal neurological deficit was elicited on examination. Neuroimaging revealed a subarachnoid haemorrhage secondary to a basilar tip aneurysm. Patient underwent endovascular embolisation with good clinical outcome. Follow-up MRI revealed anterior circulation vasospasm, and although clinically asymptomatic, she was treated with a calcium channel antagonist. She was later discharged home with no neurological deficit. Follow-up MRI 3 months following presentation suggested recurrent formation of the aneurysmal sac. The patient then underwent elective endovascular repair 2 months later and was discharged home on antiplatelet therapy with planned close outpatient clinical and radiological surveillance.

**BACKGROUND**

Subarachnoid haemorrhage (SAH) secondary to paediatric aneurysm represents a separate pathophysiological entity compared with adults. Given the rarity of paediatric aneurysm and its potentially serious implications in children, this creates difficulty in setting up suitably powered randomised control trials to guide treatment options. For that reason, detailed case reports such as this may add to the body of evidence and assist in optimising treatment strategies in the future for this group of patients.



**Figure 1** (A) Axial unenhanced CT of the brain showing acute subarachnoid haemorrhage (arrow) with prominence of the temporal horns (\*) suggesting early hydrocephalus. (B) Further image from the same study showing intraventricular extension of blood into both lateral and third ventricles.



**Figure 2** (A) Sagittal reconstruction of enhanced CT angiogram showing irregularity at the posterior aspect of the distal basilar artery (arrow). (B) Three-dimensional time-of-flight Magnetic Resonance Angiography revealing 6 mm saccular basilar artery aneurysm, projecting posteriorly into the interpeduncular fossa.

**CASE PRESENTATION**

We present the case of a previously well, developmentally appropriate 14-month-old girl who attended the emergency department following an acute episode of decreased level of consciousness. Her Glasgow Coma Scale on presentation was 11 (eye opening 3, vocal response 4 and motor response 4).

There was no history of systemic upset, trauma or relevant medical, family or social history.

Physical examination revealed no focal neurological deficit. Blood pressure was within normal range and blood sugar was normal.

**INVESTIGATIONS**

Urgent unenhanced CT of the head (*figure 1A,B*) demonstrated acute SAH, with intraventricular extension and early signs of hydrocephalus, confirming Hunt and Hess grade 3 presentation of acute SAH, with modified Fisher grade 4 imaging appearances.<sup>1,2</sup>

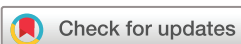Enhanced CT angiography (*figure 2A*) revealed irregularity of the distal basilar artery suggestive of an aneurysm, subsequently confirmed on MRI angiography (*figure 2B*), with a 6 mm aneurysm seen projecting posteriorly from the basilar tip.

Ultrasound scan of the renal tracts was normal, specifically no renal cysts.

Full blood count and clotting screen were also normal, autoantibody screen negative.

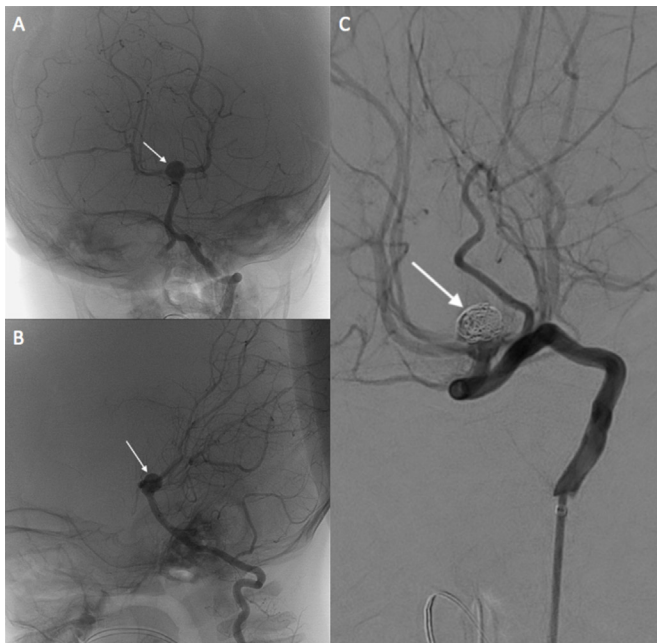
**DIFFERENTIAL DIAGNOSIS**

Differential diagnosis is of any cause of acute decrease in conscious level in children.<sup>3</sup> These include intracranial infection, toxins, metabolic conditions and trauma.



© BMJ Publishing Group Limited 2020. No commercial re-use. See rights and permissions. Published by BMJ.

**To cite:** Mallett P, O'Reilly ST, Rennie I, et al. *BMJ Case Rep* 2020;**13**:e233875. doi:10.1136/bcr-2019-233875

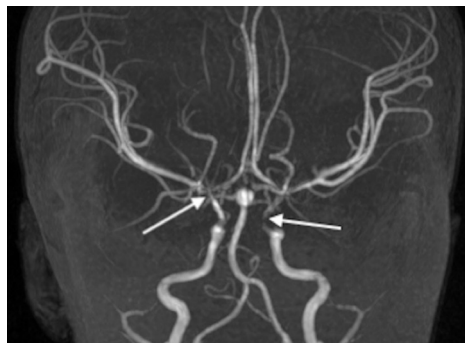


**Figure 3** (A,B) Anteroposterior and lateral unsubtracted digital angiographic images, performed with contrast injection via the left vertebral artery, demonstrating a saccular basilar artery aneurysm (arrows). (C) End of procedural digital subtraction angiographic image of the treated basilar aneurysm, with intrasaccular coils causing good flow stasis (arrow).

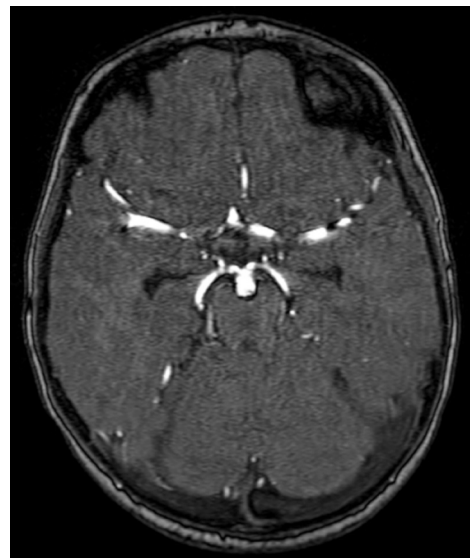
### TREATMENT

The patient underwent endovascular embolisation. A four-French groin sheath was inserted into the left common femoral artery using a micropuncture set under ultrasound guidance. Initial digital subtraction angiography (figure 3A,B) from the left vertebral artery showed the basilar tip aneurysm to have a smooth saccular morphology. Working projection was obtained requiring an extreme anteroposterior angulation. A headway duo microcatheter was placed in the aneurysm and it was coil occluded until flow stasis was achieved (figure 3).

Follow-up Magnetic Resonance Angiogram (MRA) (figure 4) at day 1 postprocedure demonstrated a large residual basilar aneurysm with complete occlusion. However, irregularity of the anterior circulation vessels was radiologically suggestive of arterial spasm.



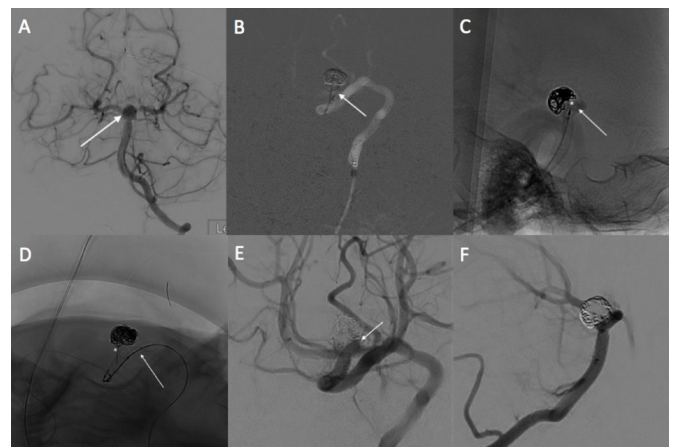**Figure 4** Three-dimensional time-of-flight angiography at day one postprocedure demonstrating large residual basilar artery aneurysm with satisfactory occlusion; however, there is narrowing of the distal internal carotids and middle cerebral arteries bilaterally (arrows) in keeping with arterial spasm.



**Figure 5** Follow-up MRA at 2 months showing significant aneurysmal recurrence.

The patient was clinically asymptomatic but was commenced on oral nimodipine (a calcium channel blocker) for this.

She was monitored in the Paediatric Intensive Care Unit (PICU) for several days postembolisation and discharged to the ward for further surveillance when clinically stable. Nimodipine was discontinued on day 23 of admission. She was felt to be back to baseline and fit for discharge from hospital on day 26 on no regular medication.



**Figure 6** (A) Initial retreatment AP Digital Subtraction Arteriogram (DSA) image performed via contrast injection from the left vertebral artery, showing basilar aneurysm neck recurrence (arrow). (B) Fluorogram image from attempted retreatment coiling showing coil prolapse from the aneurysm neck into the basilar artery (arrow). (C) Sagittal unsubtracted digital angiographic image showing a Woven Endobridge device placed within the aneurysm (\*), however, with prolapse into the basilar artery (arrow), meaning it could not be deployed safely. (D) AP fluoroscopic image showing stent deployed via the left vertebral access within the left posterior cerebral artery/basilar artery (arrow) and the headway duo microcatheter from the right vertebral artery 'jailed' within the aneurysm (\*). (E,F) AP and lateral DSA images at the end of the procedure showing stent-assisted coiling of the basilar artery aneurysm with only a small residual neck remnant on the left (arrow).

## Patient's perspective

In May of last year, we discovered our 14-month-old daughter had a brain aneurysm. Hearing that news was the worst feeling we have ever experienced. Since that day we have continued to go through a whirlwind of emotions. We have felt sadness, despair, stress and worry; we have felt petrified and numb at the possibility that we were going to lose our daughter.

On that evening, she was very lethargic and had become much worse; then as I was holding her in my arms I felt her go limp, I looked down and she was grey and lifeless.

I rang the ambulance, which arrived promptly. I knew in this moment things were not good and I felt sick to my stomach.

When we arrived at hospital, initially no one seemed to know what was causing her to be so ill. They originally tested her for meningitis, which terrified us but this came back clear. They rushed her in for a CT scan, which showed she had a bleed on her brain. Our heads were in a complete spin, there were so many doctors around our tiny daughter and she looked so small and helpless. They decided to move her up to intensive care, everything was happening so fast and there was so much information for us to take in.

Intensive care was a very daunting experience but the staff were amazing. They were very attentive and explained both good and bad news to us. They kept us informed of everything that was going on; however, it was also confusing at times as there was a lot of discussion back and forth between the doctors as they were liaising with a specialist centre to decide on the best form of treatment. It soon became apparent that the aneurysm she had was extremely rare and they had limited information as to what lay ahead for us. They had nothing to compare her situation to and everything felt very surreal. We had no reassurance as they just didn't know how things were going to go.

She needed to have surgery and her life depended on it. Again, they were unable to give us any statistics. We were frightened when we were made aware of the surgery risks as both stroke and death were mentioned, but we knew she needed the surgery, or she would die.

It is difficult to explain how we felt at this time, it was a struggle, but we needed to remain strong. We were so relieved the surgery was a success. She would need to be closely monitored and have regular MRIs. They also said that there was a chance the aneurysm could come back. However, all of this information was based on how adults recover.

She had her repeat MRI 6 weeks later; unfortunately, it showed the aneurysm had got bigger and more surgery would be required. We knew this was a possibility, but we did not expect it to happen so soon. There was a chance she would have to travel to a quaternary centre for this operation. This added to the stress as we also have an older daughter who was being affected by everything that was going on. Thankfully, the local team were happy to perform the surgery again and a surgeon travelled from another centre to assist them. This was a relief, as we had also built up a relationship with him, and we trusted him. But it was comforting to know that another specialist surgeon would be there to assist him.

Thankfully, the second operation was successful. However, she is now on long-term medication. This impacts not only us but our surrounding family who help take care of her as they must be made aware of the importance of her taking this medication at

Continued

## Patient's perspective Continued

certain times of the day. This is something else we have had to adapt to as a family.

Unfortunately, everything still remains uncertain for our daughter. She will continue to have regular MRIs and be closely monitored. What keeps us going is that she is doing really well; she is a happy little girl who is developing and reaching all her milestones just like any other child her age.

We are so grateful that the doctors saved her life and hope and pray she continues to do well. We take comfort in the fact that she is so well looked after and cared for by all the doctors, nurses and medical staff in our local hospital; we thank each and every one from the bottom of our hearts, they are our superheroes.

## OUTCOME AND FOLLOW-UP

A 2-month follow-up MR angiogram (figure 5) revealed significant recurrent filling of the body of the previously coiled basilar tip aneurysm, with the aneurysmal sac also slightly larger than before.

Five months following initial presentation, she underwent repeat endovascular repair of the aneurysm recurrence (figure 6A). This was performed with the intention of using the simplest and safest technique that would not require long-term medication.

For this reason, initial treatment with coils only was attempted; however, significant coil prolapse (figure 6B) secondary to the wide-necked morphology of the recurrence meant this was not feasible. Subsequent aneurysm occlusion with a Woven Endobridge (WEB) device was attempted; however, due to the posterior angulation of the aneurysm, satisfactory placement of the WEB device could not be achieved without some prolapse into the basilar artery (figure 6C), and so was, therefore, removed.

It was decided that the best option was, therefore, stent-assisted coiling, which while necessitating the use of long-term antiplatelet medication would allow satisfactory aneurysm occlusion.

Bilateral four-French femoral access was obtained, with bilateral four French guide catheters placed in each vertebral artery. An XT-17 catheter via the left vertebral was placed in the left posterior cerebral artery (PCA) and a headway duo via the right vertebral was placed in the aneurysm, with the first loop of coil deployed (figure 6D).

Intravenously, 75 mg of aspirin was given 10 min prior to deployment of a 2.5×25 mm Leo baby stent from the left PCA into the basilar artery, with packing of the stent applied at the aneurysm neck to provide good neck coverage. Satisfactory coil occlusion of the aneurysm was then possible via the 'jailed' headway duo microcatheter, until only a small left sided neck remnant remained (figure 6E,F).

The patient was commenced on 12-month dual antiplatelet therapy with clopidogrel and aspirin, with a plan for lifelong aspirin thereafter.

She will be followed up jointly by the neurosurgical and interventional neuroradiology teams in 3 months following interval MRI scan. At initial follow-up, the patient remains clinically well and achieving developmental milestones as normal.

## DISCUSSION

Paediatric intracranial aneurysms are rare. In recent extensive work researching atraumatic paediatric intracranial aneurysm,

## Learning points

- ▶ Paediatric intracranial aneurysms are rare—particularly, in the infant and toddler age groups; however, they can be an important differential in a child with acute impairment of consciousness.
- ▶ Subarachnoid haemorrhage is the most common mode of presentation of cerebral aneurysms in paediatric population. Surgical clipping and endovascular embolisation are treatment options.
- ▶ Adult risk factors such as smoking, hypertension and alcohol are unlikely to contribute to paediatric aneurysm formation.
- ▶ Vasospasm is a recognised poor prognostic indicator in adult patients; however, this may not be the case in paediatric cases.

infantile and toddler aneurysm diagnoses were found to be particularly rare.<sup>4</sup>

They are reported to occur twice as commonly in men as women. The age distribution within sexes differs with boys showing a gradual increase in frequency with increasing age, whereas girls predominate around the time of menarche.<sup>4</sup>

Unlike in this case, paediatric intracranial aneurysms have a tendency to be located more frequently in the anterior circulation, and most commonly in the internal carotid artery bifurcation.<sup>5</sup> Posterior circulation aneurysms are, however, around three times more commonly seen in the paediatric population compared with adults, with paediatric basilar artery aneurysms reported in approximately 11% of cases compared with 4%–8% in adults.<sup>4</sup>

Well-established adult risk factors such as alcohol, hypertension and smoking are unlikely to contribute to those in paediatric population. Underlying comorbidities are found in around 30% of children with intracranial aneurysm.<sup>6</sup> One study suggested that up to 50% of paediatric aneurysms may be attributed to previous arterial dissection.<sup>7</sup>

In this case, there were no predisposing factors for aneurysm, such as known connective tissue disease or polycystic kidney disease, and no preceding trauma.

The most common presenting complaint in the paediatric population is SAH, accounting for more than 70% of cases. Other presentations include seizures, chronic headache and as an incidental finding on cerebral scanning.<sup>4</sup>

Following the publication of the International Subarachnoid Aneurysm Trial trial, in 2003, there has been a dramatic shift in the treatment of cerebral aneurysms in the adult population from surgical clipping to endovascular embolisation.<sup>8</sup>

Evidence for the management of cerebral aneurysms in the paediatric population is based largely on experience in adult patients and reported case series.<sup>9</sup> Sanai *et al* found that children treated endovascularly were four times more often in need of further management as compared with those that were managed with open neurosurgical procedures.<sup>10</sup> A meta-analysis, however, conducted by Lanzino *et al* looking at adults found that functional outcome at 1 year was better in patients managed endovascularly despite the increased risk of recurrence or early rebleed.<sup>11</sup> They advised that endovascular embolisation should be the preferred technique of treatment in acutely ruptured aneurysms whenever technically feasible.

In cases of ruptured aneurysms, the clinical grade immediately following the SAH is a strong predictor of outcome.<sup>4</sup> Although

cerebral vasospasm is recognised as a significant risk factor for poor outcome following SAH in adult patients, this was found not to be the case in paediatrics in a review conducted by Beez *et al*.<sup>12</sup>

The long-term effect of endovascular treatment in paediatric patients is not yet well established due to the small number of patients treated, and the evolving techniques in endovascular surgery.

Long-term close neurosurveillance is required. Outcome must be considered in a holistic multi-disciplinary manner with physical, neurodevelopmental and psychological impact on the developing child.

**Twitter** Peter Mallett @SimEdRBHSC

**Acknowledgements** The team would like to acknowledge the contribution from clinicians and healthcare professions in Acute Paediatrics, Paediatric Neurosurgery and Interventional Neuroradiology in both the Royal Belfast Hospital for Sick Children and the Royal Victoria Hospital. Most importantly, we would like to thank the patient, her parents and family for their time, patience and contribution to this piece of work. This report will significantly add to the literature in this area and be of good educational value to current and future healthcare professionals.

**Contributors** PM is involved in the care of the patient in PICU and co-wrote this article with STO (an Interventional neuroradiology registrar) and myself (AJT). PM also liaised with patients' parents throughout the process and engaged their participation with patient perspective section and was responsible for planning report and first draft format. This was reviewed, edited and adjusted by AJT. STO was involved to provide more technical expertise in the neuroradiology field. MS and IR were both closely involved in this patients' management throughout their journey.

**Funding** The authors have not declared a specific grant for this research from any funding agency in the public, commercial or not-for-profit sectors.

**Competing interests** None declared.

**Patient consent for publication** Parental/guardian consent obtained.

**Provenance and peer review** Not commissioned; externally peer reviewed.

## ORCID iD

Sean Thomas O'Reilly <http://orcid.org/0000-0003-1023-5471>

## REFERENCES

- Hunt WE, Hess RM. Surgical risk as related to time of intervention in the repair of intracranial aneurysms. *J Neurosurg* 1968;28:14–20.
- Frontera JA, Claassen J, Schmidt JM, *et al*. Prediction of symptomatic vasospasm after subarachnoid hemorrhage: the modified Fisher scale. *Neurosurgery* 2006;59:21–7.
- Royal College of Paediatrics and Child Health. The management of children and young people with an acute decrease in conscious level, 2015. Available: <https://www.rcpch.ac.uk/decon2015>
- Sorteberg A, Dahlberg D. Intracranial non-traumatic aneurysms in children and adolescents. *Curr Pediatr Rev* 2013;9:343–52.
- Huang J, McGirt MJ, Gailloud P, *et al*. Intracranial aneurysms in the pediatric population: case series and literature review. *Surg Neurol* 2005;63:424–32.
- Vaid VK, Kumar R, Kalra SK, *et al*. Pediatric intracranial aneurysms: an institutional experience. *Pediatr Neurosurg* 2008;44:296–301.
- Krings T, Geibprasert S, terBrugge KG. Pathomechanisms and treatment of pediatric aneurysms. *Childs Nerv Syst* 2010;26:1309–18.
- Molyneux A, Kerr R, Stratton I, *et al*. International subarachnoid aneurysm trial (ISAT) of neurosurgical clipping versus endovascular coiling in 2143 patients with ruptured intracranial aneurysms: a randomised trial. *Lancet* 2002;360:1267–74.
- Bhogal P, Pérez MA, Wendl C, *et al*. Paediatric aneurysms - Review of endovascular treatment strategies. *J Clin Neurosci* 2017;45:54–9.
- Sanai N, Quinones-Hinojosa A, Gupta NM, *et al*. Pediatric intracranial aneurysms: durability of treatment following microsurgical and endovascular management. *J Neurosurg* 2006;104:82–9.
- Lanzino G, Murad MH, d'Urso PI, *et al*. Coil embolization versus clipping for ruptured intracranial aneurysms: a meta-analysis of prospective controlled published studies. *AJNR Am J Neuroradiol* 2013;34:1764–8.
- Beez T, Steiger H-J, Hänggi D. Evolution of management of intracranial aneurysms in children: a systematic review of the modern literature. *J Child Neurol* 2016;31:773–83.

Copyright 2020 BMJ Publishing Group. All rights reserved. For permission to reuse any of this content visit <https://www.bmj.com/company/products-services/rights-and-licensing/permissions/>  
BMJ Case Report Fellows may re-use this article for personal use and teaching without any further permission.

Become a Fellow of BMJ Case Reports today and you can:

- ▶ Submit as many cases as you like
- ▶ Enjoy fast sympathetic peer review and rapid publication of accepted articles
- ▶ Access all the published articles
- ▶ Re-use any of the published material for personal use and teaching without further permission

#### Customer Service

If you have any further queries about your subscription, please contact our customer services team on +44 (0) 207111 1105 or via email at [support@bmj.com](mailto:support@bmj.com).

Visit [casereports.bmj.com](http://casereports.bmj.com) for more articles like this and to become a Fellow