

Received: 2020.01.15

Accepted: 2020.03.08

Available online: 2020.04.02

Published: 2020.04.28

# Intracranial Gorgon: Surgical Case Report of a Large Calcified Brain Arteriovenous Malformation

Authors' Contribution:  
Study Design A  
Data Collection B  
Statistical Analysis C  
Data Interpretation D  
Manuscript Preparation E  
Literature Search F  
Funds Collection G

ABEF 1,2 **Ioan Alexandru Florian**  
BEF 3 **Laura Popovici**  
BEF 4 **Teodora Larisa Timis**  
EF 2 **Ioan Stefan Florian**  
EF 5,6,7 **Ioana Berindan-Neagoe**

1 Clinic of Neurosurgery, Cluj County Emergency Clinical Hospital, Cluj-Napoca, Romania  
2 Department of Neurosurgery, Iuliu Hatieganu University of Medicine and Pharmacy, Cluj-Napoca, Romania  
3 Department of General Medicine, Iuliu Hatieganu University of Medicine and Pharmacy, Cluj-Napoca, Romania  
4 Department of Physiology, Iuliu Hatieganu University of Medicine and Pharmacy, Cluj-Napoca, Romania  
5 MEDFUTURE Research Center for Advanced Medicine, Cluj-Napoca, Romania  
6 Research Center for Functional Genomics, Biomedicine, and Translational Medicine, Institute of Doctoral Studies, Iuliu Hatieganu University of Medicine and Pharmacy, Cluj-Napoca, Romania  
7 Department of Experimental Pathology, "Prof. Ion Chiricuta", The Oncology Institute, Cluj-Napoca, Romania

**Corresponding Author:** Ioan Alexandru Florian, e-mail: [florian.ioan.alexandru@gmail.com](mailto:florian.ioan.alexandru@gmail.com)

**Conflict of interest:** None declared

---

**Patient:** Male, 55-year-old

**Final Diagnosis:** Right frontal arteriovenous malformation, partially calcified • multiple generalised epileptic seizures • chronic headache

**Symptoms:** Epileptic seizure • headache

**Medication:** —

**Clinical Procedure:** Neurosurgical resection of the right frontal AVM

**Specialty:** Neurosurgery

**Objective:** Rare disease

**Background:** Brain arteriovenous malformations (AVMs) are benign intracranial vascular anomalies that, under certain circumstances, may become life-threatening. Diffuse calcifications found in the vessel walls, interposing tissue or adjacent cerebral parenchyma are not uncommon, however, intense calcifications of AVMs that render them into veritable "brain stones" are scarcely reported in the literature and a genuine neurosurgical nightmare.

**Case Report:** A 55 years-old male patient lacking any personal history of serious morbidities or surgical interventions was referred to our department for several epileptic seizures and severe chronic headache in the parieto-occipital region. Upon clinical examination, the patient was aware, right-handed, and had no motor or sensory deficits. Computed tomography angiography scan showed a large densely calcified frontal AVM. The patient was subjected to neurosurgical removal of the lesion and was discharged a week later with a minor motor deficit of the left arm.

**Conclusions:** Intracranial AVMs are a rare pathology, but a genuine microsurgical trial. The difficulty level soars when the malformed vessels become atherosclerotic and calcified, rendering bipolar ligation or permanent clipping unfeasible. An incomplete resection in the case of a highly calcified lesion can only result in an uncontrollable hemorrhage.

**MeSH Keywords:** Arteriovenous Malformations • Calcinosis • Neurosurgical Procedures • Seizures

**Full-text PDF:** <https://www.amjcaserep.com/abstract/index/idArt/922872>



2034



—



4



42



## Background

Brain arteriovenous malformations (AVMs) are rare benign intracranial vascular anomalies consisting of an amalgamation of convoluted vessels receiving arterial blood and shunting it directly into a venous drainage [1–3]. Despite this not being frequently mentioned, AVM calcification is present in up to 25–30% of cases and may account for the second highest number of calcified vascular lesions, behind only cavernous malformations [4,5]. Epileptic seizures are the most common form of presentation for unruptured AVMs, and the second most frequent presenting symptom overall, behind only hemorrhage [1–9]. Endovascular embolization and stereotactic radiosurgery are therapeutic alternatives, though it is thought that surgical resection of AVM yields the best and earliest results in controlling related symptoms [1–3,10,11]. Nevertheless, in the post-ARUBA era, the issue of the most appropriate form of treatment for unruptured brain AVMs remains controversial [11–13]. Given the rarity of highly calcified vascular malformations in neurosurgical practice, there is a scarcity of data regarding the natural history, outcome, and best possible form of treatment for the patients harboring them. This case report illustrates one such challenging situation that was successfully managed via microsurgical resection.

## Case Report

In 2017, a 55 years-old male patient lacking any personal history of serious morbidities or surgical interventions, was referred to our department for several epileptic seizures and severe chronic headache in the parieto-occipital region. The onset of the symptoms was 6 years prior and with an insidious progression, being resistant to conventional antiepileptic and analgesic therapy. Upon clinical examination, the patient was aware, right-handed, had no motor or sensory deficits, and complained of right parieto-occipital headache.

The non-contrast enhanced head computed tomography (CT) scan (Figure 1A, 1B) showed a highly dense nonuniform paraventricular mass within the right frontal lobe, without perilesional cerebral edema and no signs of recent hemorrhage. The subsequent CT angiography (CTA) (Figure 1C, 1D) revealed this lesion to be a tortuous mass of blood vessels that reached the right precentral gyrus cortically and the frontal horn of the right lateral ventricle. Its blood afferents were both superficial and deep, whereas the drainage was superficial, towards the superior sagittal sinus (SSS). The initial diagnosis was of a partially calcified brain arteriovenous malformation, Spetzler-Martin grade IV.

All management options, including endovascular embolization and Gamma Knife stereotactic radiosurgery, were presented to the patient and family, as well as the risks and disadvantages

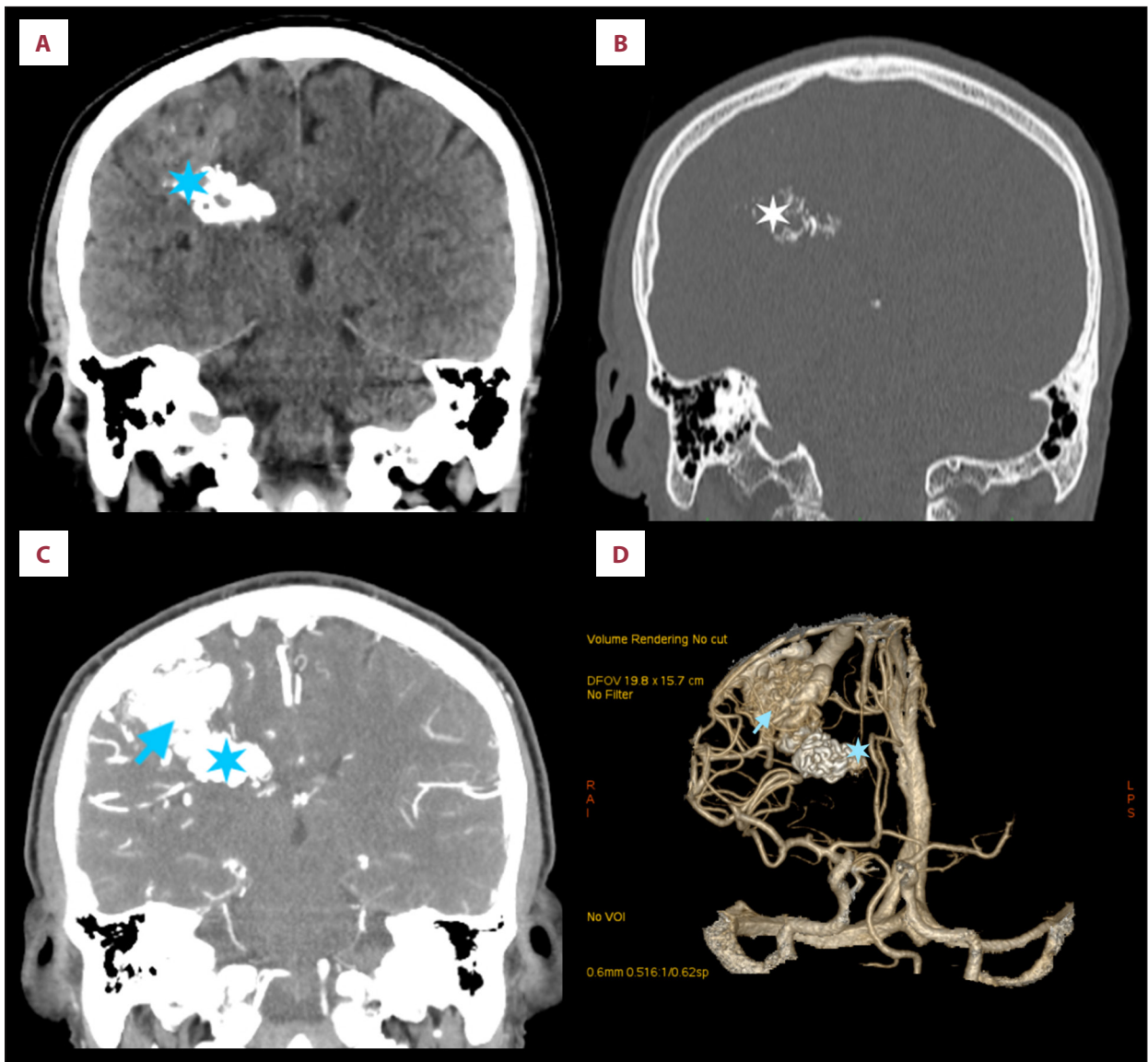
of surgery. Radiosurgery was weighed for the control of epileptic seizures and headache, however, due to the undetermined risk of rupture in the short-term period, we thought surgery to be the best choice of treatment. Considering the lack of alleviation from the symptomatic therapy, as well as the increasing severity of the symptoms and the risk of spontaneous hemorrhage, the patient, the family, and the neurosurgical team opted for microsurgical resection of the lesion. The patient himself insisted on having the lesion removed and gave his informed consent. No other form of AVM occlusion was attempted, either before or after surgery.

We performed a right temporo-parietal craniotomy and proceeded to remove the vascular malformation in its entirety. The resection became increasingly difficult the deeper we went, as the calcified vessels had the appearance and consistency of cemented material but were entirely patent. Contrary to preoperative partially embolized AVMs, in which the reduced mobility and maneuverability of the AVM is compensated by a reduced bleeding, in this particular case the coagulation via bipolar forceps yielded no results for hemostasis, as the vessels would not shrink or collapse because of their rigidity. The only viable option was to use continuous aspiration and resume dissection. Fortunately, bleeding stopped once the lesion was completely removed and the uncalcified deep feeders were coagulated.

After resection, we performed a non-contrast enhanced CT scan (Figure 2), showing the complete removal of the lesion, with minor calcium deposits in the adjacent paraventricular parenchyma and a small amount of blood in the subdural and subarachnoid spaces of the right hemisphere. Postoperatively, the patient was awake and presented a new severe motor deficit on the left arm, which under physiotherapy improved before discharge from hospital. The CT scan performed on the third day after surgery revealed a reduction of the subdural blood (Figure 3). On the seventh day after surgery, the sutures were removed, and the patient was transferred to another center in order to continue recovery.

The pathological examination disclosed a mass lesion comprised of vascular structures of variable diameter, some of which presented bright areas of intense calcification and focal thrombi, confirming that it was indeed an AVM.

The control at 3 and 6 months respectively showed a marked improvement of the motor function. The CTA scans showed no remnant or recurrence of the lesion (Figure 4). During this interval, and under continuous antiepileptic drug therapy (valproic acid, 200 mg daily), the patient did not suffer from generalized epileptic seizures. He did, however, complain of a single brief episode of tremors in his left upper limb, which could have been interpreted as a partial epileptic seizure. As this was observed only by himself and not by an expert in the



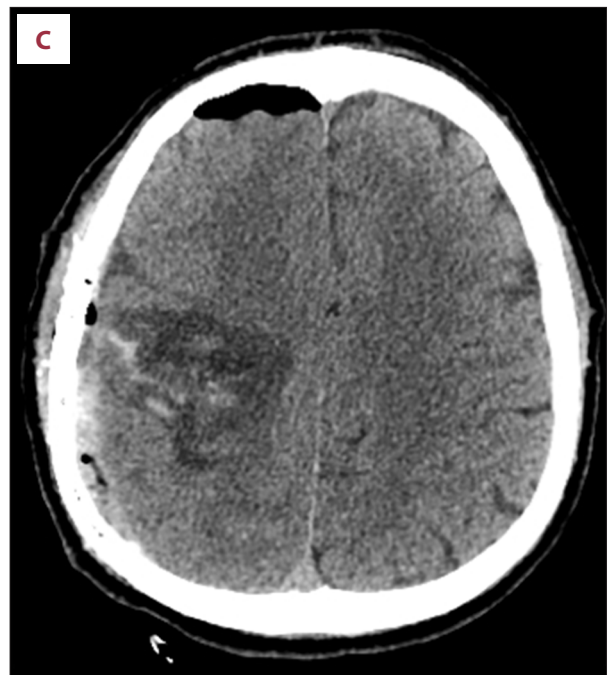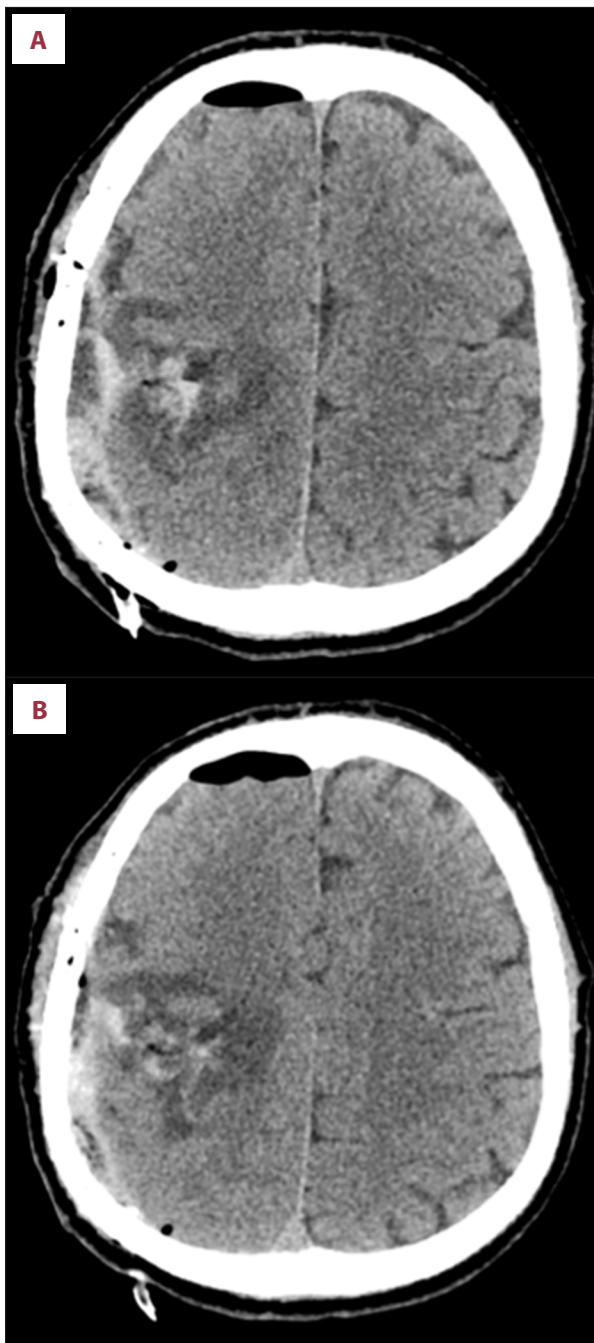
**Figure 1.** Preoperative computed tomography (CT) and CT angiography (CTA). (A) Non-contrasted CT scan showing the highly dense right paraventricular formation representing the deep calcified portion of the arteriovenous malformation (AVM) (blue star). (B) The bone window more clearly demonstrates the calcium deposits (white star). (C) CTA revealing the superficial, “soft” part of the nidus (blue arrow) as well as its relationship with the calcified region (blue star). (D) 3-dimensional reconstruction of the CTA, showing the “soft” nidus (cyan arrow), calcified portion (cyan star), feeders and draining veins.

field, the true nature of this singular episode remains elusive. At the 1-year control, the motor function of his left arm remained unchanged, and the antiepileptic therapy was successfully interrupted without subsequent seizures.

## Discussion

Despite AVMs being the second most common vascular malformation of the brain to present calcifications [5], the pathophysiological mechanisms of partial completely calcified AVMs are

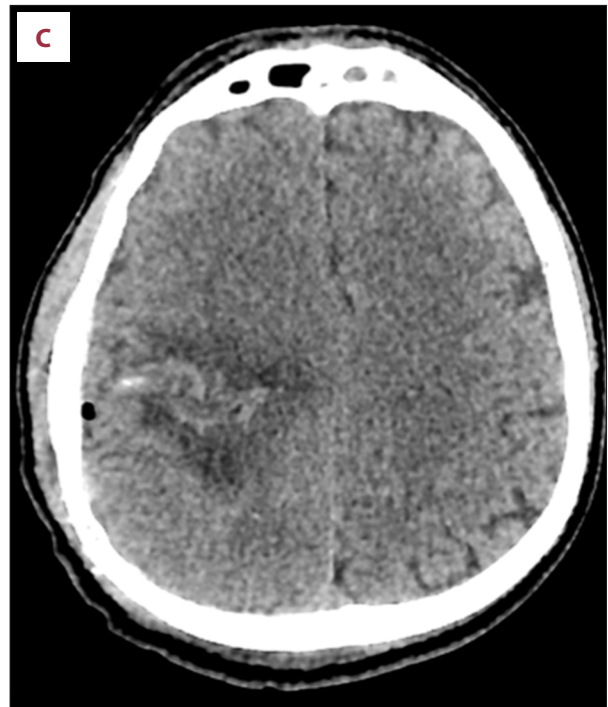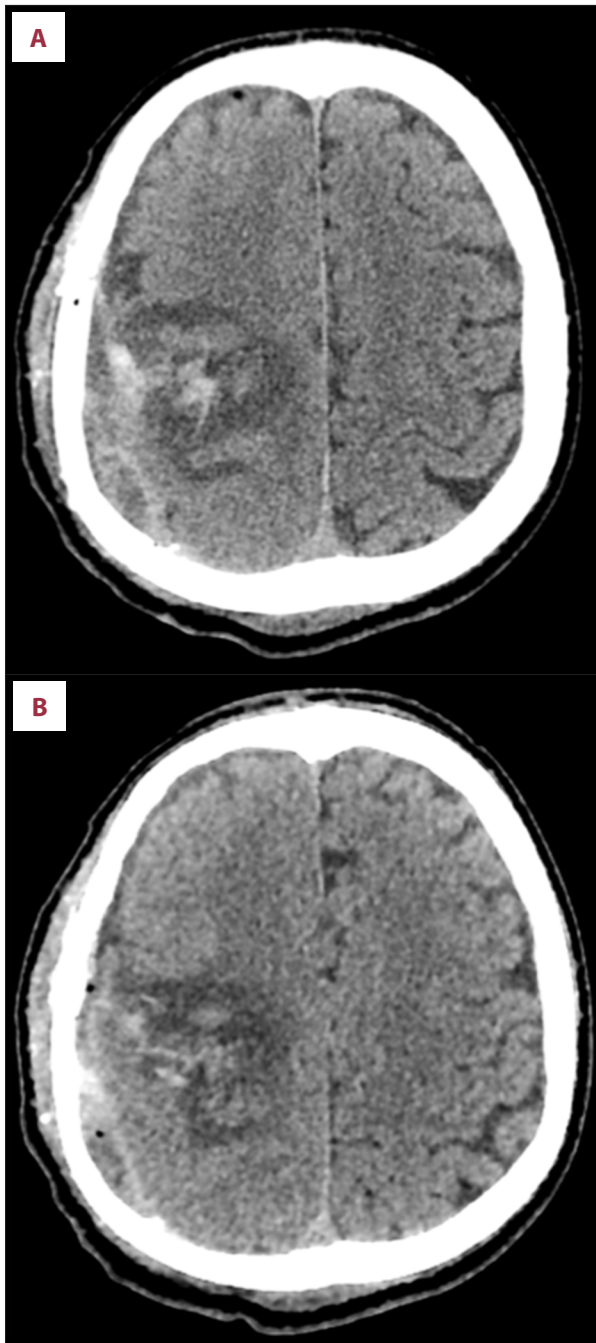
as of yet uncertain. It has been stipulated that this phenomenon is a result of chronic venous ischemia and repeated hemorrhages [4,5]. Among other suspected factors are inflammation, vasculitis, and intraluminal thrombosis, some of the lesions becoming angiographically occult [4,5,14]. Yu et al. remarked that the calcifications were restricted to the malformed vessel walls of the lesion but could extend to the neighboring gliotic cerebral tissue [15]. They also hypothesized that this phenomenon could be the result of vascular steal, as it may lead to calcium deposits on ischemic and dystrophic parenchyma. Spontaneous regression of AVMs has also been described, with



**Figure 2.** Immediate postoperative computed tomography scan. (A–C) Axial slices demonstrating the removal of the lesion, hemostatic material and a small amount of hemorrhage in place of the nidus, a hematic collection in the subarachnoid and subdural spaces, as well as a minimal pneumocephalus. The subaponeurotic drainage can be observed in the lower right.

the lesions becoming sclerotic and impregnated with calculi as a sign of involution [13,16]. It is estimated that 25–30% of AVMs present a degree of calcification, predominantly alongside serpentine vessels, in the surrounding parenchyma or inside of the nidus itself, yet these findings may be underestimated [4,17,18]. However, these calcifications are typically faint and are comprised of punctate densities dispersed either in a nodular or curvilinear fashion [19].

As early as 1924, Cushing and Bailey described a patient who underwent 2 surgeries for the removal of a calcified AVM [16]. The patient later received radiotherapy for the possibility of the AVM to be in fact a tumor. Another calcified vascular malformation was discussed by Shafey in 1966, and the histopathological examination was of a “capillary-venous hemangioma, with extensive calcification and ossification” [20]. Leblanc and Ethier noted that a significant number of patients with AVMs presenting with seizures harbored calcification within the lesion [21], and in the case report presented by Baykal et al. the calcified AVM was treated conservatively via antiepileptics [14]. Sandu and Gorgan described the total resection of a partially thrombosed and calcified parasagittal AVM, reportedly without additional neurological deficit [13], while Munakomi et al. illustrated the complete removal of a grade V right parietal AVM with speckled peripheral calcifications, the patient having no change in the severity of the left-sided hemiparesis as before surgery [22]. Other reports focused on the higher sensibility of CT scans in detecting calcifications [18,23,24], or the fact that these malformations may become thrombosed or regress and thus being angiographically occult [14,22,25–27]. However, none considered the impact these modifications may have on surgical management. Moreover, unlike the calcified,



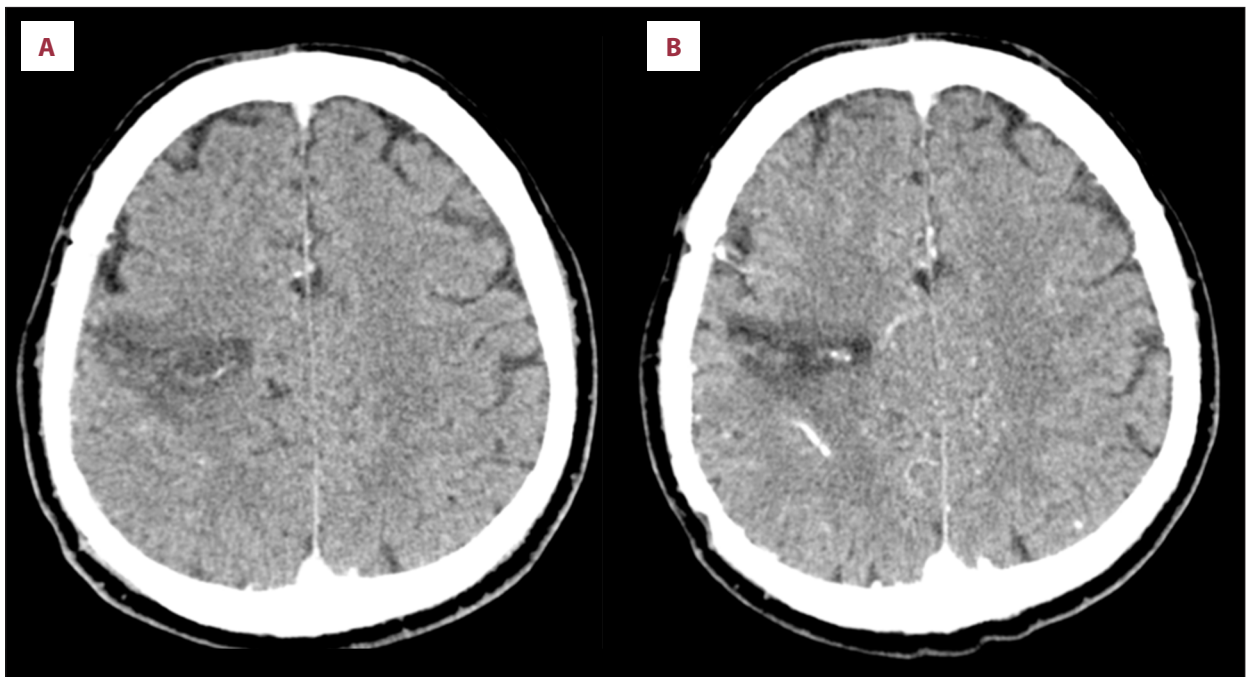
**Figure 3.** Control non-contrasted computed tomography scans. These scans were performed on the third postoperative day (A–C), showing marked reduction of the hemorrhage and perilesional edema.

thrombosed and angiographically occult AVMs, our case was visible and patent on CTA.

In the wake of the controversial ARUBA (A Randomized trial of Unruptured Brain AVMs) study, which compared interventional therapy to conservative treatment, the optimal management modality for these lesions was left in uncertainty [13,28–33]. The study was halted due to the much higher proportion of patients suffering from stroke, neurologic impairment and death in the interventional arm, despite only a small number

of patients being subjected to surgery. The possibility to generalize these findings to individual patients is therefore restricted [30]. A more definitive randomized control trial should be performed to establish whether surgical removal is superior to simple antiepileptic medication in controlling seizures caused by unruptured AVMs [31]. Even so, physicians also have to take into calculation the wishes of the informed patient, as quality of life is subjective and may be improved through any treatment method. The experience of our senior neurosurgeon in treating vascular malformations of the brain spans over 25 years, with 212 AVM surgically resected between January 2000 and December 2018, with 156 patients (81%) having a favorable outcome at discharge and an overall mortality of only 7% (13 patients). This was the only case in his repertoire that presented such extensive calcifications, deeming it one of the most challenging.

Complete microsurgical resection of AVMs presenting with seizures has been generally linked with higher seizure-free rates than embolization or radiosurgery [34–38]. Additionally, as Hyun et al. illustrated, surgery patients benefitted from the shortest median interval to achieving seizure-free status when compared to the other 2 methods [38]. Stereotactic radiosurgery is also capable of controlling or eliminating AVM-associated epilepsy in the majority of patients while causing lower rates of *de novo* seizures than surgical resection [35,39–42]. Moreover,



**Figure 4.** Control Computed tomography angiography at 3 months (A) and 6 months (B) respectively. The imaging studies reveal no sign of patent nidus or hemorrhage remaining, only a small amount of perilesional calcium deposits in the brain parenchyma.

according to the systematic review by Chen et al., seizure-free rates are significantly greater in the event of a completely occluded AVM (82% versus 41% for complete and incomplete occlusion respectively), even surpassing surgery [39]. As Ironside et al. have shown in their meta-analysis, up to two-thirds of seizure-free patients can also renounce antiepileptic drugs entirely [40]. These results might, however, not have been attainable in our case due to the patent calcified portion of the AVM. As of yet, it is uncertain whether radiosurgery alone may be able to achieve total obliteration in such heavily calcified AVMs.

Limitations of our case report include the absence of a preoperative digital subtraction angiography (DSA) to accurately establish AVM patency, as well as the lack of experience in managing AVMs with such a high degree of calcification. There is a small number of calcified AVMs in observational case series, but even fewer in surgical reports. As a result, a clear management indication or an ideal treatment method may prove elusive. It can be reasoned that a completely calcified lesion that is angiographically occult has no other definitive treatment modality than surgical resection. However, in absence of symptoms, we advise against surgical resection of such cases, as the risk of hemorrhage or growth is minimal.

Our case posed a more challenging therapeutic conundrum, as it was permeable and only the deep portion presented intense calcifications. The superficial part still had a considerable chance of growth and hemorrhage and, since it was symptomatic and in an eloquent area of the brain, it posed a threat to

the patient. Since endovascular embolization excludes AVMs from circulation but does not physically remove the lesion itself, and because the patient suffered from epileptic seizures, it was ruled out as an adequate form of treatment. And because the calcified vessels were already dystrophic, we considered radiosurgery to be ineffective in reducing their diameter. Thus, we established that the only adequate course of action was microsurgical resection, even if both the treating physicians and the patient knew of the risk of long-lasting motor or sensory deficit. Fortunately, the postoperative deficits were tolerable, and the patient managed to recover appreciably in between follow-up controls. The moral of this case report would be that symptomatic calcified AVM should be removed, especially if they are visible on angiographic studies.

## Conclusions

Intracranial AVMs are a rare pathology, but a genuine microsurgical trial. The difficulty level soars when the malformed vessels become atherosclerotic and calcified, rendering bipolar ligation or permanent clipping unfeasible. An incomplete resection can only result in an uncontrollable hemorrhage. We reported a case of an intensely calcified high-grade AVM that was completely removed and with the patient in a favorable neurological outcome.

## Conflicts of interest

None.

## References:

1. Florian IS, Perju-Dumbravă L (eds.), [Therapeutic options in hemorrhagic strokes]. Editura Medicală Universitară "Iuliu Hatieganu" Cluj-Napoca; 2007 [in Romanian]
2. Florian IS, Baritchi A, Trifoi SV: [Arteriovenous malformations]. In: Popescu I, Ciuce C (eds.), *Tratat de Chirurgie Vol VI*. 2<sup>nd</sup> edition. Editura Academiei Române, 2014; 402–10 [in Romanian]
3. Kalb S, Gross BA, Nakaji P: Vascular malformations (arteriovenous malformations and dural arteriovenous fistulas). In: Ellenbogen RG, Sekhar LN, Kitchen ND (eds.), *Principles of Neurological Surgery*. 4<sup>th</sup> edition. Elsevier, 2018; 313–24
4. Celzo FG, Venstermans C, De Belder F et al: Brain stones revisited – between a rock and a hard place. *Insights Imaging*, 2013; 4(5): 625–35
5. Gezercan Y, Acik V, Çavuş G et al: Six different extremely calcified lesions of the brain: brain stones. *Springerplus*, 2016; 5(1): 1941
6. Opinzar A, Mendez G, Abla AA: Epidemiology, genetics, pathophysiology, and prognostic classifications of cerebral arteriovenous malformations. *Handb Clin Neurol*, 2017; 143: 5–13
7. Zhao J, Wang S, Li J et al: Clinical characteristics and surgical results of patients with cerebral arteriovenous malformations. *Surg Neurol*, 2005; 63(2): 156–61; discussion 161
8. Galletti F, Costa C, Cupini LM et al: Brain arteriovenous malformations and seizures: an Italian study. *J Neurol Neurosurg Psychiatry* 2014;85: 284–88
9. Shetty R, Kato Y, Watabe T et al: Unruptured arteriovenous malformations of brain: An overview. *Rom Neurosurg*, 2010; 17(1): 34–35
10. Majewska P, Tsui A, Adamides AA: Delayed symptomatic haemorrhage from the remnants of a thalamic arteriovenous malformation after previous angiographic cure with radiotherapy. *Acta Neurochir*, 2017; 159(11): 2123–25
11. Javadpour M, Al-Mahfoudh R, Mitchell PS, Kirolos R: Outcome of microsurgical excision of unruptured brain arteriovenous malformations in ARUBA – eligible patients. *Brit J Neurosurg*, 2016; 30(6): 619–22
12. Yu JF, Nicholson AD, Nelson J et al: Predictors of intracranial hemorrhage volume and distribution in brain arteriovenous malformation. *Interv Neuroradiol*, 2018; 24(2): 183–88
13. Sandu AM, Gorgan MR: Partial thrombosed parasagittal AVM, complete resection, case report. *Rom Neurosurg*, 2015; 29(3): 255–63
14. Baykal SL, Ceylan S, Dinc H et al: Clinical and radiological evaluation of angiographically occult, calcified intracranial vascular malformation. Case report. *Neurosurg Rev*, 1996; 19(2): 119–21
15. Yu YL, Chiu EKW, Woo E et al: Dystrophic intracranial calcification: CT evidence of “cerebral steal” from arteriovenous malformation. *Neuroradiol*, 1987; 29(6): 519–22
16. Kushner J, Alexander E: Partial spontaneous regressive arteriovenous malformation. *J Neurosurg*, 2009; 32(3): 360–66
17. Kiroglu Y, Calli C, Karabulut N, Cagatay O: Intracranial calcifications on computed tomography: pictorial essay. *Diagn Interv Radiol*, 2010; 16(4): 263–69
18. Brown RD, Wiebers DO, Forbes G et al: The natural history of unruptured intracranial arteriovenous malformations. *J Neurosurg*, 1988; 68(3): 352–57
19. Wharen RE, Scheithauer BW, Laws ER: Thrombosed arteriovenous malformations of the brain. *J Neurosurg*, 2009; 57(4): 520–26
20. Shafey S, Gargano F, Mackey E: Angiomatous malformation as a cause of cerebral Calculus. *J Neurosurg*, 2009; 24(5): 898–900
21. Leblanc R, Ethier R: The computerized tomographic appearance of angiographically occult arteriovenous malformations of the brain. *Can J Neurol Sci*, 1981; 8(1): 7–13
22. Munakomi S, Bhattarai B, Cherian I: Case report: Microsurgical excision of grade 5 cerebral AVM. *F1000Res*, 2016; 4: 1197
23. Hayward RD: Intracranial arteriovenous malformations. Observations after experience with computerized tomography. *J Neurol Neurosurg Psychiatry*, 1976; 39(10): 1027–33
24. Noorbehesht B, Fabrikant JJ, Enzmann DR: Size determination of supratentorial arteriovenous malformations by MR, CT and angio. *Neuroradiol*, 1987; 29(6): 512–18
25. Lobato RD, Perez C, Rivas JJ, Cordobes F: Clinical, radiological, and pathological spectrum of angiographically occult intracranial vascular malformations. *J Neurosurg*, 1988; 68(4): 518–31
26. Kramer RA, Wing SD: Computed tomography of angiographically occult cerebral vascular malformations. *Radiology*, 1977; 123(3): 649–52
27. Pinto RS, Kricheff II, Butler AR, Murali R: Correlation of computed tomographic, angiographic, and neuropathological changes in giant cerebral aneurysms. *Radiology*, 2014; 132(1): 85–92
28. Abecassis JJ, Xu DS, Batjer HH, Bendok BR: Natural history of brain arteriovenous malformations: A systematic review. *Neurosurg Focus*, 2014; 37: 1–11
29. Goldberg J, Raabe A, Bervini D: Natural history of brain arteriovenous malformations: systematic review. *J Neurosurg Sci*, 2018; 62(4): 437–43
30. Rutledge WC, Abla AA, Nelson J et al: Treatment and outcomes of ARUBA-eligible patients with unruptured brain arteriovenous malformations at a single institution. *Neurosurg Focus*, 2014; 37(3): E8
31. Josephson CB, Sauro K, Wiebe S et al: Medical vs. invasive therapy in AVM-related epilepsy: Systematic review and meta-analysis. *Neurol*, 2016; 86(1): 64–71
32. Galletti F, Costa C, Cupini LM et al: Brain arteriovenous malformations and seizures: An Italian study. *J Neurol Neurosurg Psychiatry*, 2014; 85(3): 284–88
33. Pabaney AH, Reinard KA, Kole MK et al: Management of arteriovenous malformations in the elderly: A single-center case series and analysis of outcomes. *J Neurosurg*, 2015; 125(1): 145–51
34. von der Brölie C, Simon M, Esche J et al: Seizure outcomes in patients with surgically treated cerebral arteriovenous malformations. *Neurosurgery*, 2015; 77(5): 762–68
35. Schramm J: Seizures associated with cerebral arteriovenous malformations. Vol 143. 1<sup>st</sup> ed. Elsevier B.V., 2017; 31–40
36. Ferlisi M, Zanoni T, Moretto G, Pasqualin A: Seizures and brain arteriovenous malformation: a surgical series. *trends cerebrovasc surgery. Acta Neurochir*. 2016; (Suppl. 123): 147–51
37. Baranoski JF, Grant RA, Hirsch LJ et al: Seizure control for intracranial arteriovenous malformations is directly related to treatment modality: A meta-analysis. *J Neurointerv Surg*, 2014; 6(9): 684–90
38. Hyun SJ, Kong DS, Lee JJ et al: Cerebral arteriovenous malformations and seizures: Differential impact on the time to seizure-free state according to the treatment modalities. *Acta Neurochir (Wien)*, 2012; 154(6): 1003–10
39. Chen CJ, Chivukula S, Ding D et al: Seizure outcomes following radiosurgery for cerebral arteriovenous malformations. *Neurosurg Focus*, 2014; 37(3): 1–10
40. Ironside N, Chen CJ, Ding D et al: Seizure outcomes after radiosurgery for cerebral arteriovenous malformations: An updated systematic review and meta-analysis. *World Neurosurg*, 2018; 120: 550–62.e3
41. Przybylowski CJ, Ding D, Starke RM et al: Seizure and anticonvulsant outcomes following stereotactic radiosurgery for intracranial arteriovenous malformations. *J Neurosurg*, 2015; 122(6): 1299–305
42. Ding D, Starke RM, Sheehan JP: Radiosurgery for the management of cerebral arteriovenous malformations. Vol 143. 1<sup>st</sup> ed. Elsevier B.V., 2017; 69–83