

Left Ventricular Thrombi and Embolic Events in Takotsubo Syndrome despite Therapeutic Anticoagulation

Claudia Stöllberger^a Josef Finsterer^a Birke Schneider^b

^aKrankenanstalt Rudolfstiftung, Wien, Austria; ^bSana Kliniken Lübeck, Lübeck, Germany

Established Facts

- Left-ventricular (LV) thrombi in patients with takotsubo syndrome (TTS) differ from LV thrombi in acute myocardial infarction. In patients with a TTS-related thrombus, the rapid improvement of contractility promotes the discharge of emboli by causing detachment of the thrombus from the LV wall resulting in embolic events despite optimal anticoagulation. At present, the management of patients with TTS-related thrombi is still unclear, and further studies are urgently needed to assess the best methods for imaging and anticoagulation and to determine the role of thrombolysis and cardiac surgery.

Novel Insights

- Until these studies are available, we suggest the following approach: patients with TTS-related ventricular thrombi should be monitored by echocardiography while receiving anticoagulation. In case of highly mobile LV thrombi, cardiac surgery to prevent systemic embolism may be considered.

Keywords

Anticoagulation · Apical ballooning · Embolic stroke · Takotsubo syndrome · Thrombus

Abstract

Introduction: Takotsubo syndrome (TTS) may be complicated by left-ventricular (LV) thrombus formation in 1.3–5.3% of patients. Risk factors for thrombi comprise apical TTS, elevated levels of C-reactive protein and troponine, thrombocytosis, persisting ST segment elevation and right-ventricular involvement. Embolic risk appears high, and anticoagulation is recommended. **Case Presentation:** We present 3 females, aged 60–82 years, with TTS-associated LV thrombi and cerebral embolism despite therapeutic anticoagulation. Two patients showed apical and 1 patient midventricular ballooning. In 2 patients LV thrombi had not been present at the first echocardiographic examination. LV thrombi were multiple and highly mobile in 2 patients; 1 patient had a single immobile thrombus associated with spontaneous echocardiographic contrast (SEC). In each case, 3 of the described risk factors for LV thrombus formation were identified. The embolic stroke occurred 41–120 h after TTS symptom onset and 21–93 h after the initiation of therapeutic anticoagulation. Two patients were discharged with a neurological deficit, and 1 of them eventually died as a consequence of the stroke. LV thrombectomy to prevent embolism, which has been reported in a small number of cases, had not been considered in our patients. **Conclusion:** At present, the

ism despite therapeutic anticoagulation. Two patients showed apical and 1 patient midventricular ballooning. In 2 patients LV thrombi had not been present at the first echocardiographic examination. LV thrombi were multiple and highly mobile in 2 patients; 1 patient had a single immobile thrombus associated with spontaneous echocardiographic contrast (SEC). In each case, 3 of the described risk factors for LV thrombus formation were identified. The embolic stroke occurred 41–120 h after TTS symptom onset and 21–93 h after the initiation of therapeutic anticoagulation. Two patients were discharged with a neurological deficit, and 1 of them eventually died as a consequence of the stroke. LV thrombectomy to prevent embolism, which has been reported in a small number of cases, had not been considered in our patients. **Conclusion:** At present, the

management of patients with TTS-related thrombi is still unclear, and further studies are urgently needed to assess the best methods for imaging and anticoagulation and to determine the role of thrombolysis and cardiac surgery. Until these studies are available, we suggest the following approach: patients with a TTS-related thrombus should be monitored by echocardiography while receiving anticoagulation. In case of highly mobile LV thrombi, the heart team may consider cardiac surgery to prevent systemic embolism. The role of SEC in TTS remains to be determined.

© 2020 S. Karger AG, Basel

Introduction

Formation of a left-ventricular (LV) thrombus is an infrequent complication of takotsubo syndrome (TTS) with a prevalence ranging from 1.3 to 5.3% (Table 1) [1–8]. Several risk factors for LV thrombus formation have been described: apical TTS, significantly elevated levels of C-reactive protein and troponine, thrombocytosis, persisting ST segment elevation and right-ventricular involvement [3, 4, 7, 9]. It has been recommended to treat

Table 1. Prevalence, embolic risk and factors associated with left-ventricular thrombus formation in takotsubo syndrome (TTS)

Author, year	Patients	Setting	Prevalence of LV thrombi	Embolic events with LV thrombi	TTS type with LV thrombi	Factors associated with LV thrombi
Sharkey et al. [1], 2010	136	SC	5 (3.7%)	2/5 (40%)	–NR	NR
Kurusu et al. [2], 2011	95	SC	5 (5.3%)	1/5 (20%)	Apical <i>n</i> = 5	–NR
Schneider et al. [3], 2014	209	MC	7* (3.3%)	2/7 (29%)	Apical <i>n</i> = 6 Midventricular <i>n</i> = 1	RV involvement
El-Battrawy et al. [4], 2016	114	SC	6 (5.2%)	1/6 (17%)	Apical <i>n</i> = 3 Midventricular <i>n</i> = 3	Elevated CRP ST segment elevation RV involvement
Dias et al. [5], 2016	206	MC	6 (3%)	1/6 (17%)	NR	–NR
Ghadri et al. [6], 2016	1,750	MC	23 (1.3%)	NR	Apical <i>n</i> = 22 Midventricular <i>n</i> = 1	–NR
Santoro et al. [7], 2017	541	MC	12 (2.2%)	2/12 (17%)	Apical <i>n</i> = 12	Troponin level >20× ULN, apical ballooning ST segment elevation >48 h
Almendro-Delia et al. [8], 2018	711	MC	20 (2.9%)	–NR	NR	–NR

CRP, C-reactive protein; LV, left ventricular; MC, multicenter; NR, not reported; RV, right ventricular; SC, single-center; ULN, upper limit of normal.

Table 2. Embolic events under anticoagulation therapy in patients with takotsubo syndrome and left-ventricular thrombi

Author, year	Age/sex	TTS type	LV EF, %	Thrombus morphology	Anticoagulation	Embolic event	Interval: initiation of AC and embolic event	Outcome
Schmidt et al. [15], 2007	70/f	apical	–	P	“effective,” drug not mentioned	Transient ischemic attack	NR	Discharged
Nerella [13], et al. 2008	43/f	apical	45	F/S	Heparin, VKA	Renal embolism	3 days	Discharged
Kurusu et al. [2], 2011	82/f	apical	45	P/M	“AC,” drug not mentioned	Ischemic stroke	1 day	Discharged
Valbusa et al. [12], 2013	75/f	apical	40	F/S → P/M	Heparin, VKA	Brachial artery embolism	6 days	Discharged
Porta et al. [14], 2013	78/f	apical	35	F/S → P/M	ASA, heparin	Ischemic stroke, mesenteric artery embolism	1 and 7 days	Died

AC, Anticoagulation; ASA, acetylsalicylic acid; F, flat; LV EF, left-ventricular ejection fraction; M, mobile; NR, not reported; P, protruding; S, sessile; TTS, takotsubo syndrome; VKA, vitamin K antagonist.

patients with TTS-related LV thrombi with anticoagulation for up to 3 months until LV function has completely normalized [7, 10, 11]. However, embolic events in patients with TTS-related thrombi despite therapeutic anticoagulation have been reported in the literature (Table 2) [2, 12–15]. We present further 3 patients with TTS-associated thrombi who developed cerebral embolism under therapeutic anticoagulation and discuss the therapeutic options in this clinical scenario.

Case Report

The clinical characteristics, laboratory findings and course of the patients are listed in Table 3. Two of these 3 patients had been included in a multicenter registry [3]. All 3 patients were postmenopausal females with an age range from 60 to 82 years. Regarding laboratory findings, 1 patient had an elevated thrombocyte count, 2 patients showed elevated D-dimer levels, and all patients had elevated C-reactive protein levels. The ECG on admission showed ST segment elevation in 2 patients and widespread negative T waves with a prolonged QTc interval >500 ms in all patients. LV ejection fraction was moderately reduced (45–56%). One patient suffered from midventricular ballooning with right-ventricular involvement whereas the other 2 patients showed an apical ballooning pattern of the LV. In 2 patients, LV thrombi had not been present at the first echocardiographic examination and were detected 21–76 h after initiation of anticoagulation for stroke and paroxysmal atrial fibrillation. LV thrombi were multiple and highly mobile in 2 patients (Fig. 1), 1 patient had a single immobile thrombus and dense spontaneous echocardiographic contrast (SEC) extending from the LV apical akinesia into the LV cavity. All embolic events were ischemic strokes, occurring 41–120 h after symptom onset and 21–93 h after initiation of anticoagulation. At the time of embolism, all patients were under therapeutic levels of anticoagulant therapy, either controlled by anti-factor Xa activity or by aPTT. Two patients had additionally received acetylsalicylic acid 100 mg/day and a clopidogrel loading dose because of an initially suspected acute coronary syndrome. All patients had a combination of 3 of the previously described risk factors for LV thrombus formation. One patient developed paroxysmal atrial fibrillation after admission as an additional risk factor for cerebral embolism. Two of the 3 patients were discharged with a neurological deficit, and 1 of them eventually died as a consequence of the disabling stroke.

Discussion

This case series and the published cases listed in Table 2 demonstrate that therapeutic anticoagulation in TTS-related LV thrombi may not completely protect from embolic events in every case. It has been recommended that patients with TTS-related ventricular thrombi should be treated with anticoagulant therapy for 3 months, since usually the wall motion abnormality resolves within this period of time

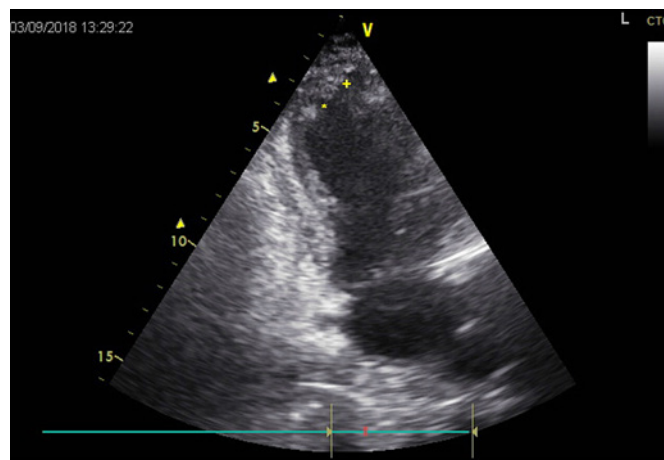


Fig. 1. Echocardiographic modified apical 4-chamber view showing ballooning of the left ventricular apex with 2 protruding thrombi measuring 10 mm (*) and 15 mm (+).

[7, 10, 11]. This recommendation derives from data on LV thrombi associated with acute myocardial infarction, most frequently anterior ST elevation myocardial infarction (STEMI) [16, 17]. There are, however, no randomized controlled trials which have assessed safety and efficacy of anticoagulation in TTS-related thrombi.

Possible mechanisms for thrombus formation in TTS are transient LV regional wall motion abnormalities resulting in the local activation of hemostasis, endocardial injury with regional exposure or release of thrombogenic substances and influence of catecholamines on nucleotide-induced platelet aggregation [10]. In the literature, most of the thrombi have been described in patients with apical TTS; however, in contrast to the assumption of Santoro et al. [7, 9], midventricular TTS may equally be associated with thrombus formation, as seen in one of our patients [4, 6, 18, 19].

Risk factors for LV thrombus formation in TTS, identified from several case series, comprise an apical type of TTS [7], significantly elevated C-reactive protein levels [4, 18], thrombocytosis [18], elevated troponin levels (>20 times the upper limit of normal) [7], ST segment elevation [4, 7], persisting for more than 48 h [9] and right-ventricular involvement [3, 4]. The predictive value of these risk factors, however, has so far not been prospectively tested. In each of our cases, a combination of 3 previously described risk factors was identified.

The prevalence of TTS-associated thrombi in large multicenter registries appears lower than in single-center

Table 3. Characteristics and course of patients with takotsubo syndrome, left-ventricular thrombi and embolic events despite anticoagulation

	Patient 1	Patient 2	Patient 3
Age, years/sex	60/f	82/f	82/f
Cardiovascular risk factors			
Hypertension	+	0	0
Diabetes	0	0	+
Hypercholesterolemia	+	0	0
Smoking	+	0	0
BMI	26	18.4	31.3
Extracardiac comorbidities	Pulmonary tuberculosis 30 years previously; ankylosing spondylitis for 15 years; cervical spinal canal stenosis, dorsal surgical decompression 3 months previously	Parkinson's disease; osteoporosis	Hypothyroidism; pneumonia
TTS			
Medication at admission	Trazodone 50 mg/day Pregabalin 150 mg/day Diltiazem 90 mg/day Pantoprazol 40 mg/day Tizanidine 4 mg/day Dexibuprofen 400 mg/day Adalimumab 40 mg every second week, last injection 6 days previously	Pramipexol 3 × 0.18 mg/day Levothyroxine 50 µg/day Alendronic acid 70 mg/week	Levothyroxine 75 µg/day
Triggering event	Conflicts within the family	Fall at home, lying on the floor for 20 h	Pneumonia
Symptoms	Epigastric pain, radiating into neck; paresthesia in fingertips and tongue	Malaise	Angina, dyspnea
ECG on admission	SR, negative T waves I, II, III, aVF; V ₂ -V ₆	SR, ST segment elevation V ₂ , negative T waves I, II, aVL, V ₂ -V ₆	SR, ST segment elevation I, aVL, V ₂ , V ₃ , negative T waves aVL, V ₂ -V ₆
Hours after OOS	16	27	21
Q wave	0	0	0
Persisting ST elevation	0	0	+
QTc (Bazett), ms	505	565	585
Laboratory findings			
Creatine kinase × ULN	1.52	12.3	3.61
Creatine kinase MB × ULN	NM	1.88	2.5
Troponine × ULN	5.6	14.7	2.7
NT-pro-BNP × ULN	5.6	-	-
D-dimer × ULN	2.0	3.1	normal
Thrombocyte count, GPT/L	527	267	236
C-reactive protein, mg/L	8.4	54	303
Echocardiography	Thickened myocardium, apical akinesia	Midventricular hypoakinesia	Apical akinesia
Hours after OOS	18	68	20
Detection of LV thrombus, hours after OOS	41	68	94
Thrombus morphology	Multiple, mobile	Multiple, mobile	Single, sessile, dense spontaneous echo contrast
LVOTO	0	0	0
LV ballooning pattern	Apical	Midventricular	Apical
LV ejection fraction, %	45	48	56
RV involvement	0	+	0
Coronary angiography			
Hours after OOS	88	89	20
Unfractionated heparin, IU	5,000	No additional heparin	No additional heparin
Coronary arteries	Nonsignificant plaque	Normal	Nonsignificant plaque
Myocardial bridging	0	LAD	0

Table 3 (continued)

	Patient 1	Patient 2	Patient 3
Pharmacotherapy			
Acetylsalicylic acid, mg	250	100	250 loading dose
Started hours after OOS	33, once	27	18, once
Clopidogrel, mg	0	300 loading dose	300 loading dose
Started hours after OOS	0	40, once	20, once
Anticoagulation	Enoxaparin 120 mg/day s.c.	Certoparin 3,000 IU, followed by unfractionated heparin i.v. in therapeutic dose according to PTT	Unfractionated heparin i.v. in therapeutic dose according to PTT
Started hours after OOS	20	27	18
Embolism			
Clinical signs	Right-sided weakness	Left-sided hemiparesis	Left-sided weakness
Assessed as	Stroke	Stroke	Stroke
Hours after OOS	41	120	92
Confirmed by	MRI, CT	CT	CT
Therapy	Enoxaparin continued	Unfractionated heparin continued	Unfractionated heparin continued
Additional adverse event	0	Sinoatrial block	Paroxysmal atrial fibrillation
Outcome			
Discharge after	26 days	27 days	11 days
Neurological deficit	0	Left-sided hemiparesis	Left-sided weakness
Ventricular function	Normal	Normal	Apical hypokinesia
Thrombus visible	0	0	Small thrombus reduced in size
Anticoagulant therapy	0	Acetylsalicylic acid 100 mg/day, certoparin 3,000 IU/day	Acetylsalicylic acid 100 mg/day, enoxaparin 100 mg/day
Follow-up	No cardiac event after 5 months	Died after 45 days from aspiration pneumonia due to the disabling stroke	Surgery for rectal carcinoma after 27 months

BMI, body mass index; CT, computed tomography; GPT, glutamic pyruvic transaminase; i.v., intravenous infusion; LAD, left anterior descending coronary artery; LV, left-ventricular; LVOTO, left ventricular outflow obstruction; MRI, magnetic resonance imaging; NM, normal muscle; NT-pro BNP, N-terminal probrain natriuretic peptide; OOS, onset of symptoms; PTT, partial thromboplastin time; RV, right-ventricular; s.c., subcutaneous injection; TTS, takotsubo syndrome; ULN, upper limit of normal.

series (Table 1). The detection rate of thrombi depends largely on the time interval between onset of TTS and the echocardiographic examination which has not been standardized in any of the registries. Furthermore, the frequency of echocardiographic examinations might be higher in single-center studies dedicated to the detection of thrombus formation than in large registries. By using cardiac magnetic resonance imaging instead of echocardiography as a diagnostic tool, the detection rate of TTS-associated thrombi is reported to be even higher [1, 3].

The clinical course of LV thrombi in TTS and STEMI in the primary percutaneous coronary intervention era seems to differ substantially. The prevalence of LV thrombi in anterior STEMI is higher than in TTS, ranging from 9.1% by echocardiography [16] to 12.2% by cardiac magnetic resonance imaging [20]. With anticoagulant therapy, LV thrombi in anterior STEMI resolve in 80–90% of

the cases within 3–6 months [17, 20]; however, new late LV thrombus formation may occur during follow-up since the wall motion abnormality usually persists [20]. The embolic complication rate in patients with anterior STEMI and LV thrombi appears to be low (1.5–6.5%) [17, 20, 21]. In contrast, in patients with TTS, the wall motion abnormalities disappear within a few days to weeks, and LV thrombi are no longer present after 2–3 months [7, 10, 18]. Embolic events, however, have been observed in 17–40% of patients with TTS-associated LV thrombi (Table 1) [1–5, 7]. Overall, in 6 large TTS registries the embolic event rate of LV thrombi was 22% (9 out of 41 patients with thrombi). It has been hypothesized that the improvement of contractility in TTS promotes the discharge of emboli by causing detachment of the thrombus from the ventricular wall, thereby transforming a mural thrombus into a protruding, floating one with embolic compli-

cations despite optimal anticoagulation therapy [2, 12, 19, 22]. This evolution makes LV thrombi in TTS extremely dangerous. The pathogenetic assumption is supported by the finding that the LV systolic function was not severely depressed, neither in our patients nor in the patients reported in the literature (Tables 2 and 3).

By transthoracic echocardiography, one of our patients showed extensive SEC in the left ventricle. SEC is related to thromboembolic events and indicates an interaction between erythrocytes and plasma proteins [23]. SEC in TTS has, to our knowledge, only been described once; however, in this case with atrial fibrillation, SEC was seen originating from the left atrium [24].

Thrombolytic therapy with urokinase has been reported to be successful and without complications in a patient with TTS-associated LV thrombus and renal infarction [25]. This therapy, however, may be associated with the risk of thrombolysis-induced fragmentation and embolization.

Cardiac surgery represents another therapeutic option for these patients. In a small number of patients aged 48–68 years, surgical thrombectomy by use of different techniques has been shown to safely remove the thrombus from the left ventricle [26–30]. Considering the high rate of embolic events in TTS-related LV thrombi and the failure of anticoagulant therapy in preventing systemic embolism in the presented 3 cases and in previous case reports, involvement of the heart team may be considered in order to discuss surgical removal of mobile TTS-related LV thrombi.

Conclusion

At present, the management of patients with TTS-related thrombi is still unclear, and further studies are urgently needed to assess the best methods for imaging and

anticoagulation and to determine the role of thrombolysis and cardiac surgery. Until these studies are available, we suggest the following approach: patients with TTS-related LV thrombi should be monitored by echocardiography every day while receiving anticoagulation. If changes in mobility and morphology of the thrombi are observed, cardiac surgery to prevent embolism may be considered by the heart team. The role of SEC as a marker for embolic events in TTS is largely unknown and should be investigated in future studies.

Statement of Ethics

The subjects have given their written informed consent to publish their case (including publication of images).

Disclosure Statement

The authors have no conflicts of interest to declare.

Sources of Funding

No grants, no funding.

Author Contribution

Claudia Stöllberger: treatment of the patients, drafting of the manuscript, literature research, corresponding author. *Josef Finsterer*: treatment of the patients, drafting of the manuscript, literature research. *Birke Schneider*: treatment of the patients, drafting of the manuscript, literature research.

References

- 1 Sharkey SW, Windenburg DC, Lesser JR, Maron MS, Hauser RG, Lesser JN, et al. Natural history and expansive clinical profile of stress (tako-tsubo) cardiomyopathy. *J Am Coll Cardiol*. 2010 Jan;55(4):333–41.
- 2 Kurisu S, Inoue I, Kawagoe T, Ishihara M, Shimatani Y, Nakama Y, et al. Incidence and treatment of left ventricular apical thrombosis in Tako-tsubo cardiomyopathy. *Int J Cardiol*. 2011 Feb;146(3):e58–60.
- 3 Schneider B, Athanasiadis A, Schwab J, Pistner W, Gottwald U, Schoeller R, et al. Complications in the clinical course of tako-tsubo cardiomyopathy. *Int J Cardiol*. 2014 Sep;176(1):199–205.
- 4 El-Battrawy I, Behnes M, Hillenbrand D, Haghi D, Hoffmann U, Papavassiliu T, et al. Prevalence, clinical characteristics, and predictors of patients with thromboembolic events in takotsubo cardiomyopathy. *Clin Med Insights Cardiol*. 2016 Jul;10:117–22.
- 5 Dias A, Franco E, Janzer S, Koshkelashvili N, Bhalla V, Rubio M, et al. Incidence and predictors of stroke during the index event in an ethnically diverse Takotsubo cardiomyopathy population. *Funct Neurol*. 2016 Jul-Sep;31(3):157–62.
- 6 Ghadri JR, Cammann VL, Napp LC, Jurisic S, Diekmann J, Bataiosu DR, et al.; International Takotsubo (InterTAK) Registry. Differences in the Clinical Profile and Outcomes of Typical and Atypical Takotsubo Syndrome: Data From the International Takotsubo Registry. *JAMA Cardiol*. 2016 Jun;1(3):335–40.
- 7 Santoro F, Stiermaier T, Tarantino N, De Gennaro L, Moeller C, Guastafierro F, et al. Left Ventricular Thrombi in Takotsubo Syndrome: Incidence, Predictors, and Management: Results From the GEIST (German Italian Stress Cardiomyopathy) Registry. *J Am Heart Assoc*. 2017 Dec;6(12):e006990.

- 8 Almendro-Delia M, Núñez-Gil IJ, Lobo M, Andrés M, Vedia O, Sionis A, et al.; RETAKO Investigators. Short- and Long-Term Prognostic Relevance of Cardiogenic Shock in Takotsubo Syndrome: Results From the RETAKO Registry. *JACC Heart Fail.* 2018 Nov; 6(11):928–36.
- 9 Santoro F, Stiermaier T, Tarantino N, Guastafierro F, Graf T, Möller C, et al. Impact of persistent ST elevation on outcome in patients with takotsubo syndrome. Results from the GERman Italian STress Cardiomyopathy (GEIST) registry. *Int J Cardiol.* 2018 Mar;255:140–4.
- 10 Herath HM, Pahalagamage SP, Lindsay LC, Vinothan S, Withanawasam S, Senarathne V, et al. Takotsubo cardiomyopathy complicated with apical thrombus formation on first day of the illness: a case report and literature review. *BMC Cardiovasc Disord.* 2017 Jul; 17(1):176.
- 11 Kurisu S, Inoue I, Kawagoe T, Ishihara M, Shimatani Y, Nishioka K, et al. Left ventricular apical thrombus formation in a patient with suspected tako-tsubo-like left ventricular dysfunction. *Circ J.* 2003 Jun;67(6):556–8.
- 12 Valbusa A, Paganini M, Secchi G, Montecucco F, Rosa GM. What happened to a thrombus during apical ballooning syndrome: a case report. *Swiss Med Wkly.* 2013 May;143:w13797.
- 13 Nerella N, Lodha A, Tiu CT, Chandra PA, Rose M. Thromboembolism in takotsubo syndrome: a case report. *Int J Cardiol.* 2008 Feb;124(2):e37–8.
- 14 Porta A, Barrabés JA, Figueras J, Millan X, Sambola A, Boyé R, et al. Transient apical ballooning complicated with left ventricular thrombus and repeated embolic events with fatal outcome despite anticoagulant therapy. *Int J Cardiol.* 2013 Apr;165(1):e11–2.
- 15 Schmidt M, Herholz C, Block M. Apical thrombus in tako-tsubo cardiomyopathy. *Heart.* 2007 Nov;93(11):1368.
- 16 Robinson AA, Jain A, Gentry M, McNamara RL. Left ventricular thrombi after STEMI in the primary PCI era: a systematic review and meta-analysis. *Int J Cardiol.* 2016 Oct;221:554–9.
- 17 Khoury S, Carmon S, Margolis G, Keren G, Shacham Y. Incidence and outcomes of early left ventricular thrombus following ST-elevation myocardial infarction treated with primary percutaneous coronary intervention. *Clin Res Cardiol.* 2017 Sep;106(9):695–701.
- 18 Haghi D, Papavassiliu T, Heggemann F, Kaden JJ, Borggrete M, Suselbeck T. Incidence and clinical significance of left ventricular thrombus in tako-tsubo cardiomyopathy assessed with echocardiography. *QJM.* 2008 May;101(5):381–6.
- 19 Y-Hassan S, Shahgaldi K. Thrombo-embolic renal infarction in a case of mid-ventricular takotsubo syndrome. *Intern Med.* 2011; 50(19):2175–8.
- 20 Bulluck H, Chan MH, Paradies V, Yellon RL, Ho HH, Chan MY, et al. Incidence and predictors of left ventricular thrombus by cardiovascular magnetic resonance in acute ST-segment elevation myocardial infarction treated by primary percutaneous coronary intervention: a meta-analysis. *J Cardiovasc Magn Reson.* 2018 Nov;20(1):72.
- 21 Pöss J, Desch S, Eitel C, de Waha S, Thiele H, Eitel I. Left Ventricular Thrombus Formation After ST-Segment-Elevation Myocardial Infarction: Insights From a Cardiac Magnetic Resonance Multicenter Study. *Circ Cardiovasc Imaging.* 2015 Oct;8(10):e003417.
- 22 Abanador-Kamper N, Kamper L, Wolfertz J, Vorpahl M, Haage P, Seyfarth M. Temporarily increased stroke rate after Takotsubo syndrome: need for an anticoagulation? *BMC Cardiovasc Disord.* 2018 Jun;18(1):117.
- 23 Kupczyńska K, Kasprzak JD, Michalski B, Lipiec P. Prognostic significance of spontaneous echocardiographic contrast detected by transthoracic and transesophageal echocardiography in the era of harmonic imaging. *Arch Med Sci.* 2013 Oct;9(5):808–14.
- 24 Brunetti ND, Ieva R, Correale M, De Gennaro L, Pellegrino PL, Dioguardi E, et al. Alternative presentation of tako-tsubo syndrome with spontaneous echo-contrast and “onion” shaped apical ballooning. *J Thromb Thrombolysis.* 2009 Aug;28(2):242–4.
- 25 Sasaki N, Kinugawa T, Yamawaki M, Furuse Y, Shimoyama M, Ogino K, et al. Transient left ventricular apical ballooning in a patient with bicuspid aortic valve created a left ventricular thrombus leading to acute renal infarction. *Circ J.* 2004 Nov;68(11):1081–3.
- 26 Niino T, Unosawa S. Surgical extirpation of apical left ventricular thrombus in takotsubo cardiomyopathy. *Case Rep Surg.* 2015;2015:387037.
- 27 Suzuki R, Kudo T, Kurazumi H, Takahashi M, Shirasawa B, Mikamo A, et al. Transapical extirpation of a left ventricular thrombus in Takotsubo cardiomyopathy. *J Cardiothorac Surg.* 2013 May;8(1):135.
- 28 Seitz MJ, McLeod MK, O’Keefe MD, Seah PW. A rare cause of Takotsubo cardiomyopathy related left ventricular apical thrombus requiring surgery. *Heart Lung Circ.* 2012 Apr; 21(4):245–6.
- 29 Zaikokuji K, Sawazaki M, Tomari S, Uemura T. Transmitral thrombectomy to treat a patient with Takotsubo cardiomyopathy. *Asian Cardiovasc Thorac Ann.* 2018 Mar;26(3):236–8.
- 30 Choi JY, Park EJ, Park SH, Kim HD, Song JY, Kim JB, et al. Surgical Removal of a Left Ventricular Thrombus Which Showed Morphologic Changes Over Time in a Patient with Stress-Induced Cardiomyopathy. *J Cardiovasc Ultrasound.* 2015 Jun;23(2):103–6.