



# Radial Artery Graft for Giant Common Carotid Artery Pseudoaneurysm After Carotid Artery Stenting

Fumihiko Matano<sup>1</sup>, Masanori Suzuki<sup>1</sup>, Takayuki Mizunari<sup>1</sup>, Toshimasa Yamada<sup>1</sup>, Yasuo Mura<sup>2</sup>, Akio Morita<sup>2</sup>

## Key words

- Carotid artery stenting
- Giant internal carotid artery aneurysm
- Radial artery graft

## Abbreviations and Acronyms

**CAS:** Carotid artery stenting  
**CCA:** Common carotid artery  
**ICA:** Internal carotid artery  
**MCA:** Middle cerebral artery  
**MRA:** Magnetic resonance angiography  
**MRSA:** Methicillin-resistant *Staphylococcus aureus*  
**RA:** Radial artery  
**STA:** Superior temporal artery

From the Departments of <sup>1</sup>Neurosurgery, Chiba Hokusoh Hospital, Chiba; and <sup>2</sup>Neurological Surgery, Nippon Medical School, Tokyo, Japan

To whom correspondence should be addressed:  
 Fumihiko Matano, M.D., Ph.D.  
 [E-mail: s00-078@nms.ac.jp]

Supplementary digital content available online.

Citation: World Neurosurg. (2020) 139:401–404.

<https://doi.org/10.1016/j.wneu.2020.04.173>

Journal homepage: [www.journals.elsevier.com/world-neurosurgery](http://www.journals.elsevier.com/world-neurosurgery)

Available online: [www.sciencedirect.com](http://www.sciencedirect.com)

1878-8750/\$ - see front matter © 2020 Elsevier Inc. All rights reserved.

## BACKGROUND AND IMPORTANCE

Carotid artery pseudoaneurysm after carotid artery stenting (CAS) is rare.<sup>1,2</sup> They are often associated with infection. Treatment of aneurysm resection and stent removal with bypass using vein grafts has been previously reported.<sup>3,4</sup> However, this is not practical for extremely large pseudoaneurysms, stents placed over a long arterial lesion, or after infection has widely spread through the neck. We present a patient who underwent left superior temporal artery (STA)–radial artery (RA)–right middle cerebral artery (MCA) bypass with resection of the right cervical internal carotid artery (ICA) pseudoaneurysm, which developed after CAS and endovascular thrombectomy for an acute cervical ICA occlusion, and discuss the treatment strategy and surgical procedure.

■ **BACKGROUND:** We present a patient who underwent left superior temporal artery (STA)–to–right middle cerebral artery (MCA) bypass using a radial artery (RA) graft with resection of a giant right cervical common carotid artery (CCA) pseudoaneurysm after carotid artery stenting (CAS) and discuss the treatment strategy and surgical procedure in detail.

■ **CASE DESCRIPTION:** An 86-year-old male presented with sudden onset of altered consciousness and complete left hemiparesis. Magnetic resonance angiography and catheter angiography of the brain revealed occlusion of the right cervical ICA. Endovascular thrombectomy and stenting of the cervical segment of the ICA were performed. Thirty-two days after CAS, the patient developed a high fever and rapid swelling of the neck. Catheter angiography showed a giant right CCA pseudoaneurysm that had a fistula just proximal to the carotid stent, and the aneurysm extended to the neck entirely. Because of the expanding neck infection, stent placement long lesion, and lack of distal collateral flow on angiography, we performed aneurysm and stent removal and left STA–to–right MCA bypass using an RA graft. The harvested RA graft was anastomosed side to end to both the M2 segment of the right MCA and the left STA. Bypass patency was confirmed before neck exposure. The pseudoaneurysm and proximal portion area of the stent were resected. The patient recovered well postoperatively, and follow-up catheter angiography showed patency of the bypass.

■ **CONCLUSIONS:** Left STA–RA–right MCA bypass with aneurysm resection is a good treatment option for giant CCA pseudoaneurysms that occur after CAS.

## CLINICAL PRESENTATION

An 86-year-old male presented with sudden onset of altered consciousness and complete left hemiparesis; his National Institutes of Health Stroke Scale score was 17. Magnetic resonance angiography and catheter angiography showed occlusion of the right cervical ICA with no distal collateral flow (Figure 1A). Diffusion-weighted magnetic resonance imaging showed a small area of slightly high signal intensity in the right corona radiata but no large acute cerebral infarction (see Figure 1B). Coincidentally, the patient undertook magnetic resonance angiography 1 month before, and asymptomatic cervical ICA stenosis was suspected but we did not choose the surgical therapy because of the high age.

Right CCA angiography revealed ICA occlusion (see Figure 1C), and we subsequently performed endovascular thrombectomy and placed a 10 mm × 31 mm stent (Carotid WALLSTENT, Boston Scientific, Marlborough, Massachusetts, USA) in the cervical ICA. After CAS, adequate arterial recanalization and TICI IIb<sup>5</sup> flow was observed (see Figure 1D). The patient's hemiparesis improved, and 18 days later, he was transferred to a rehabilitation hospital with a mild hemiparesis.

On day 32 after CAS, the patient developed a high fever and rapid swelling in the neck. Blood cultures grew methicillin-resistant *Staphylococcus aureus* (MRSA), and he progressed to septic shock. After antibiotic therapy, he recovered from septic shock but the neck swelling and fever continued. Catheter angiography showed

a giant right CCA pseudoaneurysm expanding neck entirely (**Figure 2A and B**), and there was no collateral brain blood flow the posterior circulation. We performed CCA angiography with occlusion of proximal CCA by balloon-guiding catheter confirming distal flow and aneurysm flow detail. We confirmed the fistula just proximal to the carotid stent of CCA to the aneurysm (see **Figure 2C**). We concluded that pseudoaneurysm and stent removal with vascular reconstruction was needed, which was successfully performed and is described in detail later.

After induction of general anesthesia, the patient was placed in the supine position and his head was fixed in pins and rotated 15 degrees to the left. One neurosurgeon performed the craniotomy while the other surgeons dissected and

harvested the right RA for the bypass procedure. A bicoronal skin incision was made to expose the left STA and perform a bifrontotemporal craniotomy. The right sylvian fissure was then opened to secure the M2 segment of the MCA. We coagulated and cut the falx and then passed the RA graft from the right MCA in the sylvian fissure to the left STA. First, the RA was anastomosed side to end to the right M2 using a 9–0 suture.

Next, the other end of the RA graft was anastomosed side to end to the left STA, also using a 9–0 suture. After bypass patency was confirmed, we then exposed the neck. Before the operation, we inserted a balloon catheter through the femoral artery to secure the proximal common carotid artery for temporary occlusion in case of aneurysm rupture. The hematoma was removed after balloon occlusion and

clamping of the arteries proximal and distal to the pseudoaneurysm. We then resected the aneurysm and proximal part of stent, placed permanent clips on the remaining artery stumps, and irrigated and closed the wound.

After the procedure, the patient recovered well and catheter angiography showed patency of the bypass (**Figure 3A**). Illustration and operative video showed surgical treatment (see **Figure 3B** and **Video 1**). He had a mild residual left hemiparesis and was later transferred back to the rehabilitation hospital.

## DISCUSSION

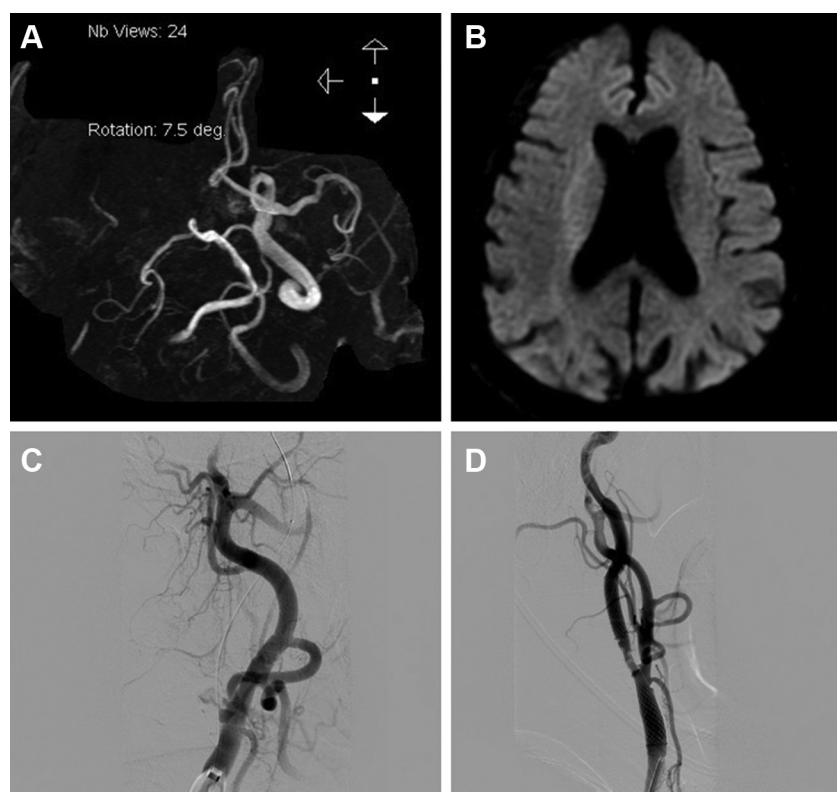
Left STA-RA-right MCA bypass with aneurysm and stent removal may be a good option as rescue therapy for infected giant right CCA pseudoaneurysms that can develop as a CAS complication.

The occurrence of pseudoaneurysms after CAS is rare.<sup>2</sup> Generally, carotid pseudoaneurysms result after weakening of the artery wall due to infection. Bacteria attach to the vasa vasorum and plaque, particularly at blood vessel bifurcations, causing local infection. Subsequently, bacteria infiltrate the vessel wall and surrounding lymph nodes, destroying the arterial wall to form a pseudoaneurysm.<sup>6,7</sup> Staphylococci, Salmonella, Klebsiella, and Escherichia coli have been reported to cause pseudoaneurysm formation in cases of septicemia, dental infection, and postoperative surgical infection.<sup>8–10</sup> Plotkin et al<sup>11</sup> reported that mycotic aortic aneurysms and aortic graft infection associated with MRSA were strongly correlated with increased mortality. Other studies have shown that nonoperative treatment of cervical mycotic aneurysms leads to death in 70%–90% of patients,<sup>8</sup> while operative treatment mortality has decreased to 10%.<sup>12</sup>

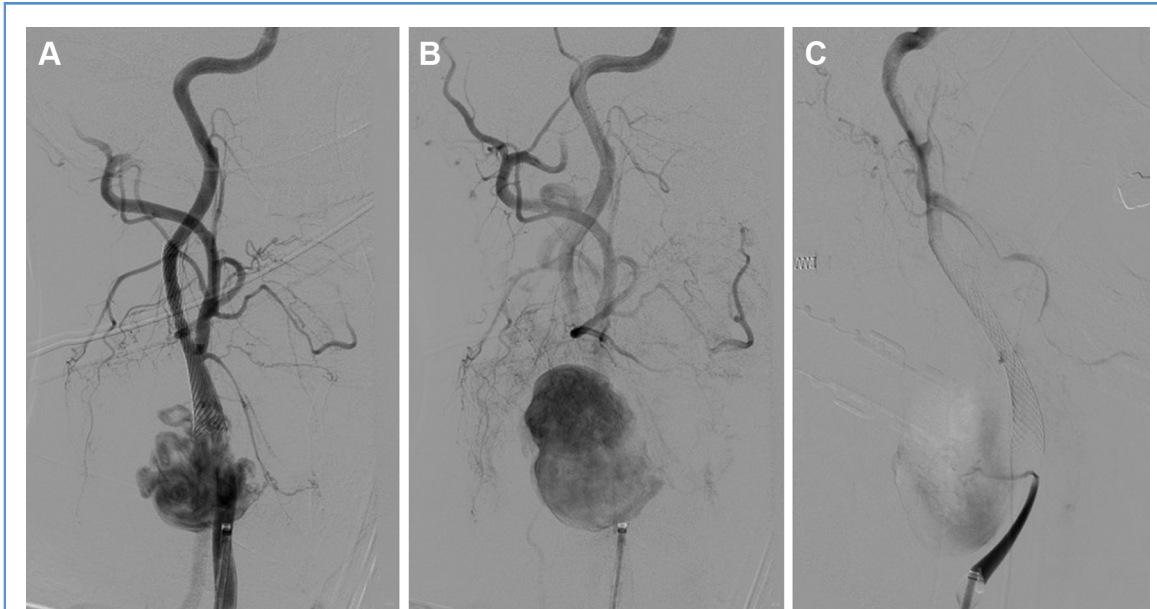In our case, iatrogenic intimal arterial wall injury may have occurred during the endovascular thrombectomy and CAS. Since MRSA was isolated from blood cultures and fever and neck swelling continued, early treatment with pseudoaneurysm and stent resection was required. Antibiotic therapy is important in the management of mycotic carotid aneurysms, especially in our patient who



Video available at  
[www.sciencedirect.com](http://www.sciencedirect.com)



**Figure 1.** (A) Magnetic resonance angiography showing right internal carotid artery occlusion. (B) Diffusion-weighted magnetic resonance imaging showing an area of slightly high intensity in the corona radiata. (C) Right common carotid artery angiography showing occlusion of the right internal carotid artery and distal and proximal balloon catheter protection for carotid artery stenting. (D) Right common carotid angiography showing recanalized internal carotid artery after stent placement.



**Figure 2.** Right common carotid artery (CCA) angiography showing a giant neck pseudoaneurysm. (A) Early arterial phase. (B) Late arterial phase. (C) Occlusion of proximal CCA by balloon

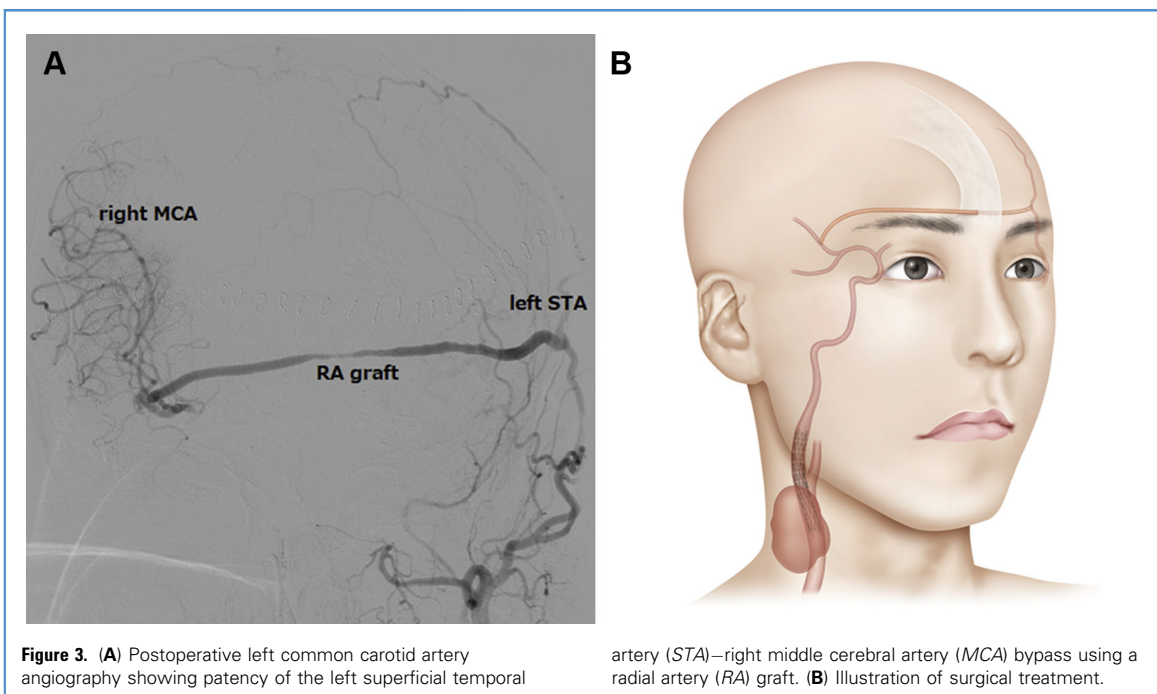
guiding catheter revealed the fistula from just proximal of the carotid stent of CCA to the aneurysm.

experienced septic shock, but it alone is inadequate.<sup>1</sup> Surgical treatment is required because of the high risk of thrombosis, embolization, and rupture; additionally, it allows direct removal of the infection

source.<sup>9,13,14</sup> Previous reports have demonstrated that trapping and pseudoaneurysm removal are effective.<sup>1,15</sup> However, in cases with absent collateral blood flow, as in our case, this is not

possible because of the risk of hemispheric ischemic complications after ligation.<sup>16</sup>

Vascular reconstruction options after aneurysm resection include direct end-to-end



**Figure 3.** (A) Postoperative left common carotid artery angiography showing patency of the left superficial temporal

artery (STA)—right middle cerebral artery (MCA) bypass using a radial artery (RA) graft. (B) Illustration of surgical treatment.

arterial anastomosis, vascular patching of the resection site, and STA or occipital artery to MCA bypass using a vein graft.<sup>16,17</sup> Because of the infected field, some reports have proposed autologous conduits such as the femoral artery, hypogastric artery, or saphenous vein. However, placement of the bypass into a site of infection has a considerable risk of bypass occlusion.<sup>18,19</sup> In addition, it is impossible to resect the distal portion of the stent because the stent is placed over a long arterial lesion. Therefore we could not choose between end-to-end anastomosed CCA and ICA.

In this case, we successfully created a left STA-right MCA bypass using an RA graft and removed the pseudoaneurysm. This treatment required a large craniotomy and radial artery sacrifice, which may not be well tolerated in elderly patients. If possible, cervical aneurysm resection and local reconstruction should be performed. When not, due to giant aneurysm, expanding infection, or the fact that the infected stent spans a long arterial segment, this approach is a viable option.

## CONCLUSION

Left STA-RA-right MCA bypass with aneurysm and stent removal is an option for treating giant right CCA pseudoaneurysms after carotid artery stenting.

## REFERENCES

- Jebara VA, Acar C, Dervanian P, et al. Mycotic aneurysms of the carotid arteries—case report and review of the literature. *J Vasc Surg.* 1991;14:215-219.
- Rabellino M, Garcia-Nielsen L, Zander T, Baldi S, Llorens R, Maynar M. Stent-assisted coil embolization of a mycotic renal artery aneurysm by use of a self-expanding neurointerventional stent. *Cardiovasc Intervent Radiol.* 2011;34(suppl 2):S109-S112.
- Monson RC 2nd, Alexander RH. Vein reconstruction of a mycotic internal carotid aneurysm. *Ann Surg.* 1980;191:47-50.
- Benedetto F, Barilla D, Pipito N, Derone G, Cutrupi A, Barilla C. Mycotic pseudoaneurysm of internal carotid artery secondary to Lemierre's syndrome, how to do it. *Ann Vasc Surg.* 2017;44:423.e413-423.e417.
- Higashida RT, Furlan AJ, Roberts H, et al. Trial design and reporting standards for intra-arterial cerebral thrombolysis for acute ischemic stroke. *Stroke.* 2003;34:e109-e137.
- Rice HE, Arbabi S, Kremer R, Needle D, Johansen K. Ruptured Salmonella mycotic aneurysm of the extracranial carotid artery. *Ann Vasc Surg.* 1997;11:416-419.
- Cornelissen BMW, Leemans EL, Slump CH, Marquering HA, Majoie C, van den Berg R. Vessel wall enhancement of intracranial aneurysms: fact or artifact? *Neurosurg Focus.* 2019;47:E18.
- Knouse MC, Madeira RG, Celani VJ. Pseudomonas aeruginosa causing a right carotid artery mycotic aneurysm after a dental extraction procedure. *Mayo Clin Proceed.* 2002;77:1125-1130.
- Liu J, Zeng Q, Huang JJ, Hu GH. Management of infected carotid artery rupture. *Eur Arch Oto-rhinolaryngol.* 2014;271:1723-1728.
- Kaczorowska M, Furmanek MI, Klimek P, Skarzynski H. [Iatrogenic internal carotid artery pseudoaneurysm as a complication of myringotomy in 6-years-old boy]. *Otolaryngol Polska.* 2012;66:368-372.
- Plotkin A, Magee GA, Elsayed RS, et al. Methicillin-resistant Staphylococcus aureus portends a poor prognosis after endovascular repair of mycotic aortic aneurysms and aortic graft infections [e-pub ahead of print]. *J Vasc Surg* <https://doi.org/10.1016/j.jvs.2019.08.274>, accessed December 13, 2019.
- Papadoulas S, Zampakis P, Liamis A, Dimopoulos PA, Tsolakis IA. Mycotic aneurysm of the internal carotid artery presenting with multiple cerebral septic emboli. *Vascular.* 2007;15:215-220.
- Busuttill RW, Davidson RK, Foley KT, Livesay JT, Barker WF. Selective management of extracranial carotid arterial aneurysms. *Am J Surg.* 1980;140:85-91.
- Shimizu T, Sakakura Y, Yamagiwa M, Hori M, Yuasa H, Murata M. Aneurysm of the extracranial carotid artery. *Arch Otolaryngol Head Neck Surg.* 1986;112:203-206.
- Petar P, Slobodan T, Srdjan B, Dragoslav N, Djordje R. Extracranial internal carotid artery pseudoaneurysms after kinking reconstruction. *Vascular.* 2010;18:356-362.
- Pirvu A, Bouchet C, Garibotti FM, Haupert S, Sessa C. Mycotic aneurysm of the internal carotid artery. *Ann Vasc Surg.* 2013;27:826-830.
- Baranoski JF, Wanebo JE, Heiland KE, Zabramski JM. Superficial femoral artery interposition graft for repair of a ruptured mycotic common carotid artery pseudoaneurysm: case report and review of the literature. *World Neurosurg.* 2019;129:130-132.
- Zardi EM, Montelione N, Vigliotti RC, et al. Surgical wound dehiscence complicated by methicillin-resistant Staphylococcus aureus infection in a diabetic patient with femorotibial vascular bypass occlusion. *Clin Med.* 2020;20:98-100.
- Matano F, Murai Y, Tateyama K, et al. Long-term patency of superficial temporal artery to middle cerebral artery bypass for cerebral atherosclerotic disease: factors determining the bypass patent. *Neurosurg Rev.* 2016;39:655-661.

**Conflict of interest statement:** The authors declare that the article content was composed in the absence of any commercial or financial relationships that could be construed as a potential conflict of interest.

Received 1 April 2020; accepted 22 April 2020

Citation: *World Neurosurg.* (2020) 139:401-404. <https://doi.org/10.1016/j.wneu.2020.04.173>

Journal homepage: [www.journals.elsevier.com/world-neurosurgery](http://www.journals.elsevier.com/world-neurosurgery)

Available online: [www.sciencedirect.com](http://www.sciencedirect.com)

1878-8750/\$ - see front matter © 2020 Elsevier Inc. All rights reserved.