

## Mesial Frontal Lobe Infarction Presenting as Pisa Syndrome

Kazuyuki Noda, MD, PhD,\* Maya Ando, MD, PhD,\* Takayuki Jo, MD, PhD,\*  
Anri Hattori, MD,\*† Kotaro Ogaki, MD, PhD,† Mizuho Sugiyama, MD,\*†  
Nobutaka Hattori, MD, PhD,† and Yasuyuki Okuma, MD, PhD\*

Pisa syndrome is usually seen in patients with Alzheimer's disease treated with a cholinesterase inhibitor, dementia with Lewy bodies, Parkinson's disease, or atypical parkinsonism including multiple system atrophy. An 86-year-old woman presented with an acute onset of lateral flexion of her trunk to the left side, i.e., Pisa syndrome. She also showed left hemiparesis predominantly in her lower extremity. Her diffusion-weighted magnetic resonance images showed acute infarction in the right premotor area and supplementary motor area. Clopidogrel (75 mg daily) was prescribed. After two weeks from the onset of symptoms, her Pisa syndrome improved.

The pathophysiology of Pisa syndrome has not yet been fully understood, but different mechanisms have been assumed. In this patient, it is possible that the infarction in her unilateral frontal lobe impaired the information processing from the temporoparietal cortex to the frontal lobe, including the premotor area and supplementary motor area for anticipatory postural control.

**Key words:** Pisa syndrome—Anterior cerebral artery infarction—Body schema—Frontal lobe

© 2020 Elsevier Inc. All rights reserved.

### Case Report

An 86-year-old woman developed acute onset of lateral flexion of her trunk to the left side. On examination, she showed weakness of her left upper extremity [Medical Research Council (MRC) grade, 3/5] and left lower extremity (MRC grade, 2/5). She showed a sustained tonic 17-degree lateral flexion of her trunk to the left side, when sitting on a wheelchair (Fig. 1A; Video 1, segment 1). This posture was alleviated in the supine position. Her Pisa angle was assessed using NeuroPostureApp© (<http://www.neuroimaging.uni-kiel.de/NeuroPostureApp>).<sup>1</sup> Her

Pisa syndrome (PS) was assessed while she was sitting, because she was unable to stand by herself because of the lesion. Her other neurological examination findings were normal. Brain magnetic resonance imaging (MRI) showed acute cerebral infarction in the right premotor area (PM) and supplementary motor area (SMA) (Fig. 1B-C). Cardiac workups showed unremarkable findings. Clopidogrel (75 mg daily) was prescribed. After two weeks from the onset of symptoms, her PS disappeared (Fig. 1D; Video 1, segment 2). She was transferred to a rehabilitation hospital.

### Discussion

PS is characterized by a marked lateral trunk deviation, which resolves or substantially improves in the supine position. PS is usually seen in patients with Alzheimer's disease treated with a cholinesterase inhibitor, dementia with Lewy bodies, Parkinson's disease, or atypical parkinsonism including multiple system atrophy (MSA). PS is relatively common in MSA and is now considered one of the "red flags" indicating a diagnosis of MSA.<sup>2</sup>

From the \*Department of Neurology, Juntendo University Shizuoka Hospital, 1129 Nagaoka, Izunokuni, Shizuoka 410-2295, Japan; and †Department of Neurology, Juntendo University School of Medicine, Bunkyo, Tokyo, Japan.

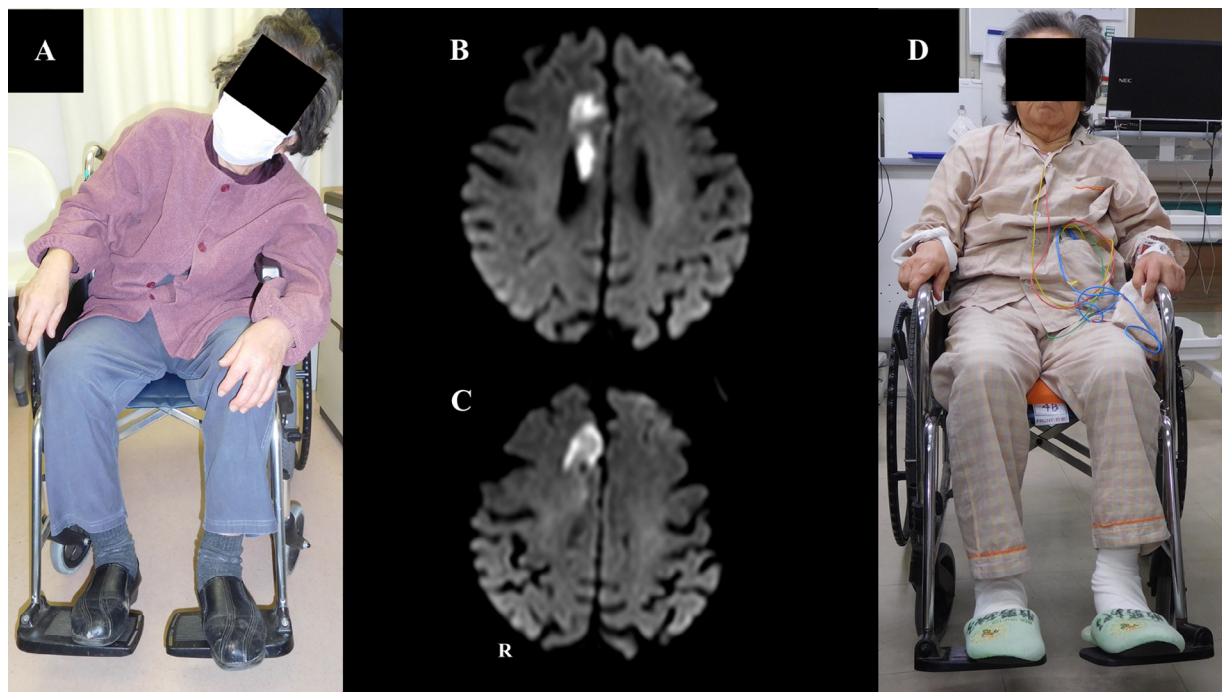
Received January 9, 2020; revision received April 7, 2020; accepted April 9, 2020.

Corresponding author. E-mail: [k-noda@juntendo.ac.jp](mailto:k-noda@juntendo.ac.jp).

1052-3057/\$ - see front matter

© 2020 Elsevier Inc. All rights reserved.

<https://doi.org/10.1016/j.jstrokecerebrovasdis.2020.104882>



**Fig. 1.** Tonic flexion of the trunk to the left was present in the sitting position (A). Brain imaging results. Diffusion-weighted magnetic resonance images with axial sections showing areas with restricted diffusion, consistent with acute infarction in the right medial frontal cortices (B-C). After two weeks from the onset, the left flexion of the trunk was alleviated (D).

Kang and Kim reported clinical and radiological features of 100 consecutive patients with anterior cerebral artery (ACA) territory infarction.<sup>3</sup> The corpus callosum/cingulate gyrus was involved in 68 patients. The SMA/paracentral lobule was involved in 55 patients, the superior frontal gyrus in 41, the frontal pole/gyrus rectus in 16, and the subcortical area in 6. Motor dysfunction was the most common symptom: hemiparesis in 70 patients, leg monoparesis in 18, and paraparesis in 3. To the best of our knowledge, patients with PS caused by ACA territory infarction have not yet been reported. The pathophysiology of PS has not yet been fully understood, and different mechanisms have been assumed, such as basal ganglial dysfunction, abnormal sensory information, hyperactivity of paraspinal muscles, and even myopathy.<sup>4</sup> Concerning postural deformities caused by cortical lesions, Oh et al. have recently described a patient with acute onset campocormia associated with a transient ischemic attack.<sup>5</sup> In addition, Marchione et al. reported the case of a patient with the onset of PS associated with a voluminous unilateral frontal, temporal, and parietal subdural hematoma, which was reversed by evacuation intervention.<sup>6</sup>

We hypothesize that the mechanism underlying PS in our patient is as follows. Somatosensory, vestibular, and visual sensations are integrated at the temporoparietal and posterior parietal cortices.<sup>7</sup> The posterior parietal cortex and its connection to the frontal lobe play an essential role in maintaining the body schema.<sup>7</sup> It is possible that the cerebral infarction in the unilateral frontal lobe impaired the information processing from the

temporoparietal cortex to the frontal lobe, including the PM and SMA for anticipatory postural control. Finally, we hypothesize that the pathophysiology of PS involves asymmetrical alteration in the cortico-striato-pallido-thalamo-cortical circuits<sup>8</sup> caused by a unilateral frontal lobe lesion.

### Declaration of Competing Interest

The authors declare no financial or other conflicts of interest.

### Supplementary materials

Supplementary material associated with this article can be found in the online version at doi:[10.1016/j.jstrokecerebrovasdis.2020.104882](https://doi.org/10.1016/j.jstrokecerebrovasdis.2020.104882).

### References

1. Schlenstedt C, Boße K, Gavriliuc O, et al. Quantitative assessment of posture in healthy controls and patients with Parkinson's disease. *Parkinsonism Relat Disord* 2020. [Epub ahead of print].
2. Marsili L, Bologna M, Kojovic M, et al. Dystonia in atypical parkinsonian disorders. *Parkinsonism Relat Disord* 2019;66:25-33.
3. Kang SY, Kim JS. Anterior cerebral artery infarction: stroke mechanism and clinical-imaging study in 100 patients. *Neurology* 2008;70:2386-2393.
4. Castrioto A, Piscicelli C, Pérennou D, et al. The pathogenesis of Pisa syndrome in Parkinson's disease. *Mov Disord* 2014;29:1100-1107.

5. Oh JH, Ryu DW, Lee SH, et al. Camptocormia with transient ischemic attack. *J Mov Disord* 2017;10:62-63.
6. Marchione P, Spallone A, Valente M, et al. Reversible Pisa syndrome associated to subdural haematoma: case-report. *BMC Neurol* 2014;14:149. <https://doi.org/10.1186/1471-2377-14-149>.
7. Takakusaki K. Neurophysiology of gait: from the spinal cord to the frontal lobe. *Mov Disord* 2013;28:1483-1491.
8. Leisman G, Braun-Benjamin O, Melillo R. Cognitive-motor interactions of the basal ganglia in development. *Front Syst Neurosci* 2014;8:1-18.